

# Hip Anatomy and Ultrasound Scanning Technique

Jon A. Jacobson, MD FACR

Professor of Radiology  
Section Chief, Musculoskeletal Imaging



1

## Disclosures

- Consultant: Bioclinica
- Book Royalties: Elsevier
- Contractor: POCUS PRO
- Advisory Board: Philips
- Not relevant to this talk

Syllabus and other educational material can be found at [www.jacobsonmskus.com](http://www.jacobsonmskus.com)

Note: all images from the textbook *Fundamentals of Musculoskeletal Ultrasound* are copyrighted by Elsevier Inc.

2

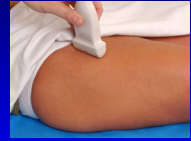## Sonographic Technique: *hip and thigh*

- Hip:
  - Anterior: hip joint, musculature, iliopsoas bursa
  - Lateral: gluteal tendons, bursae
  - Posterior: external rotators
  - Other: symphysis pubis, inguinal hernia
- Thigh:
  - Anterior: quadriceps femoris
  - Medial: abductors
  - Posterior: hamstring

3

## Sonographic Technique: Hip

- Anterior
  - Hip joint
  - Anterior musculature
  - Snapping iliopsoas
  - Iliopsoas bursa
  - Lateral femoral cutaneous nerve
- Transducers:
  - 10 – 12 MHz linear
  - <10 MHz curvilinear if needed

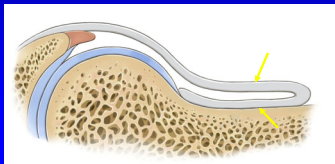


4

## Hip: anterior recess

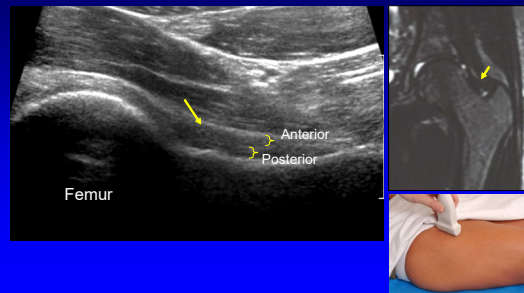
- Anterior and posterior layers
  - Fibrous tissue + minute layer of synovium
  - Hyperechoic
  - Each 2 - 4 mm thick

Radiology  
1999; 210:499

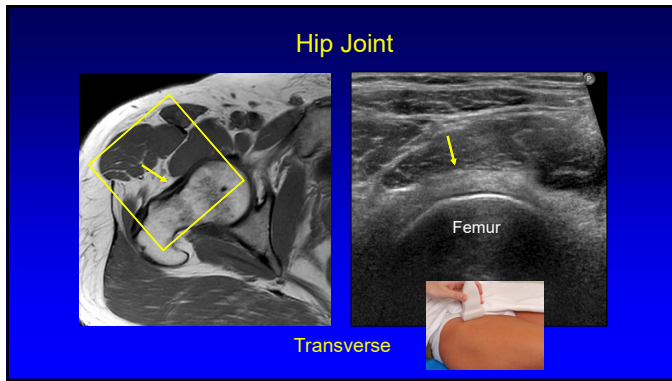


5

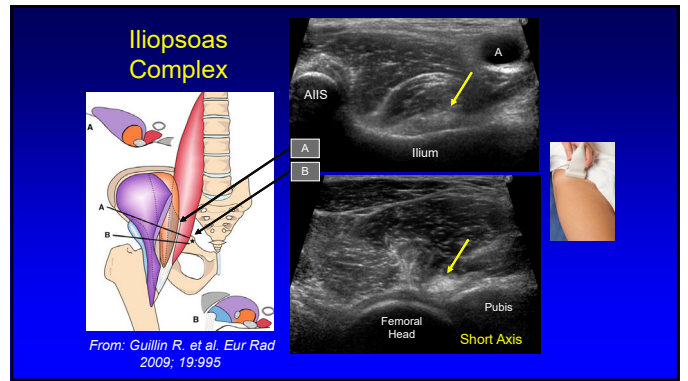
## Hip: anterior recess



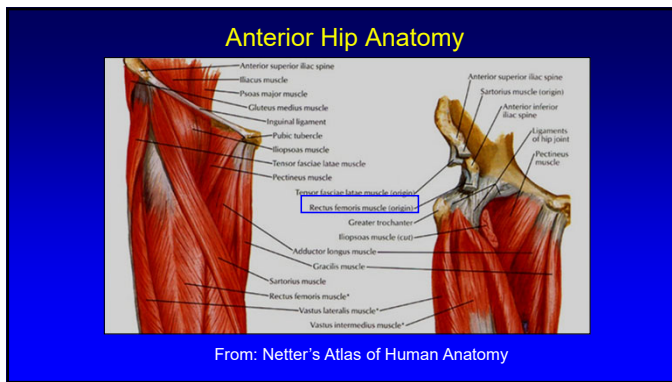
6



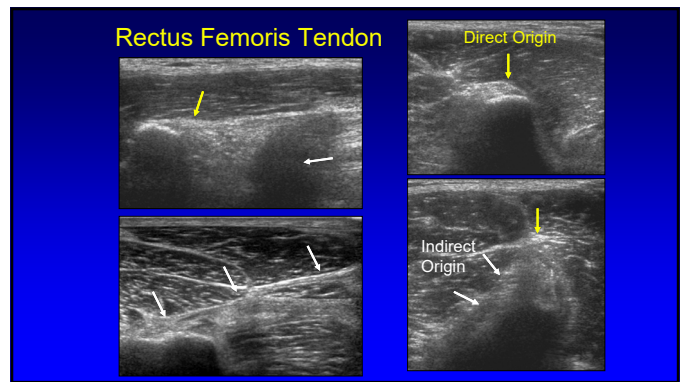
7



8



9



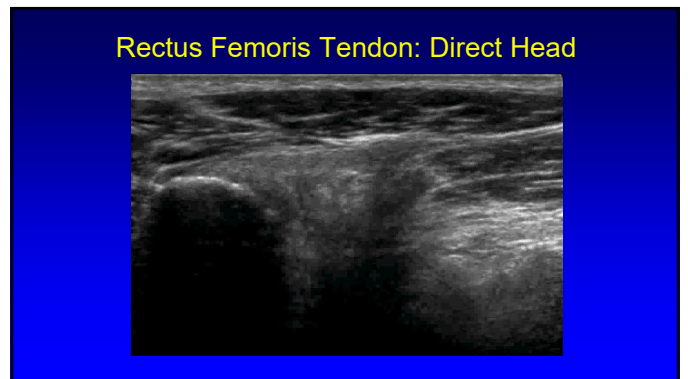
10

### Rectus Femoris Origin: Indirect Head

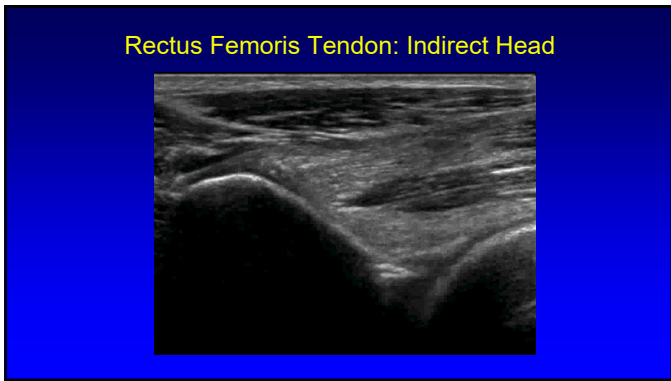
- Indirect or reflected head
- Anterolateral hip:
  - Superior acetabular ridge
  - Hip joint capsule
  - Forms central aponeurosis
- Oblique axial plane: 30°
  - 34 (l) x 10 (w) x 4 (thick) mm
- Injury more common than direct head

From: Moraux A et al. 2015 Eur Radiol 25:3614

11



12



13

### Lateral Femoral Cutaneous Nerve

- Sensory: anterolateral thigh
- Variable course:
  - 62% medial, 27% superficial, 11% lateral to ASIS
- Variable branching
- Superficial to sartorius
  - Lateral fat triangle

Rudin D et al. JBJS 2016; 98:561

14

### Lateral Femoral Cutaneous Nerve

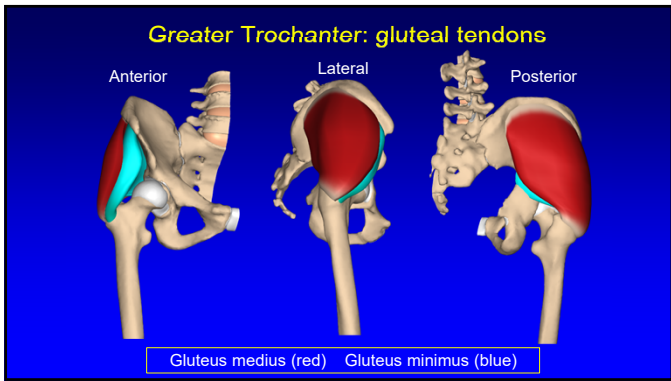
Short Axis Long Axis

15

### Sonographic Technique: Hip

- Lateral
  - Greater trochanter
  - Gluteal tendons
  - Bursae
  - Snapping hip
- Transducers:
  - 10 – 12 MHz linear
  - <10 MHz curvilinear if needed

16



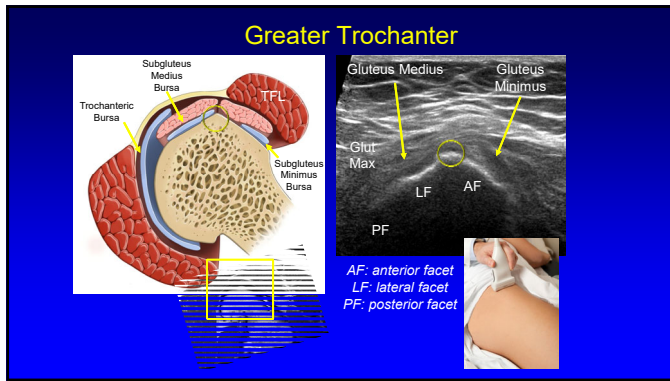
17

### Greater Trochanter

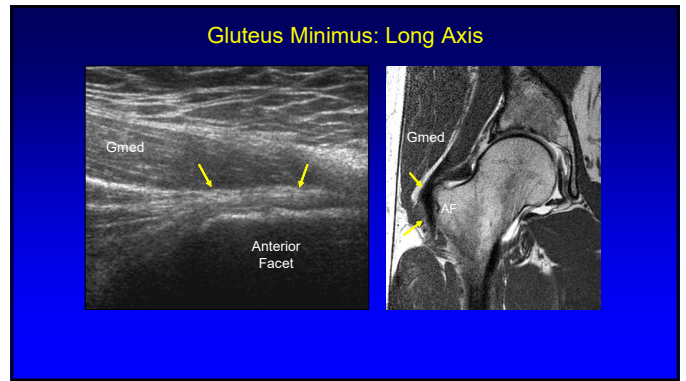
AF LF SPF PF SGMIB TrB SGMIB TrB Gluteus Medius Gluteus Minimus

FACETS: AF = anterior; LF = lateral; SPF = superoposterior; PF = posterior  
Pflrmmann et al. Radiology 2001; 221:469

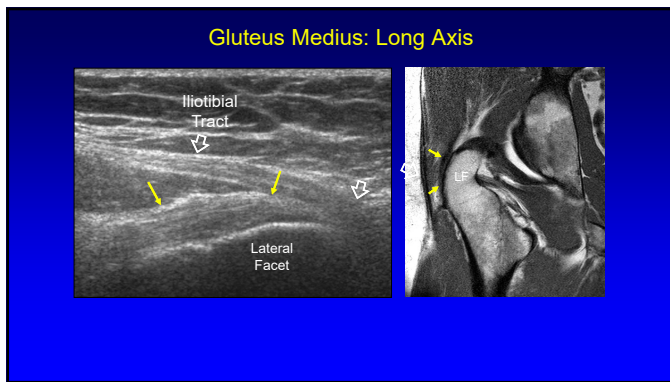
18



19



20



21

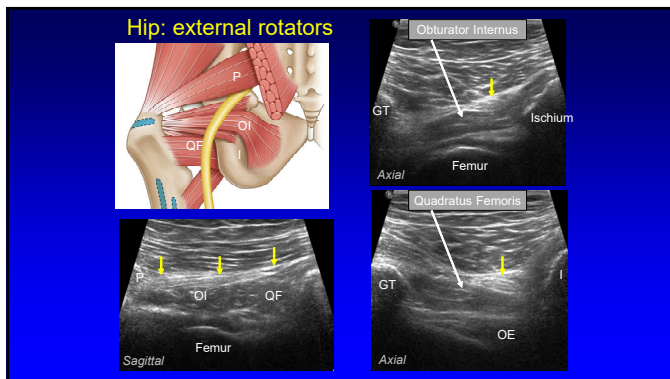
### Sonographic Technique: Hip

- **Posterior**
  - Piriformis
  - Superior gemellus
  - Obturator internus
  - Inferior gemellus
  - Obturator externus
  - Quadratus femoris
  - Sciatic nerve

Gluteus maximus (cut)  
Gluteus medius (cut, gluteal)  
Gluteus minimus  
Gluteus medius (insertional footprint)  
Vastus Tubercle  
Gluteus maximus (cut)  
Adductor brevis (insertional footprint)  
Pectineus  
Biceps  
Obturator externus  
Obturator internus  
Piriformis  
Quadratus femoris (gluteus to ischio- and iliopectineus)

From: Philippon et al. Orth J Sports Med 2014

22



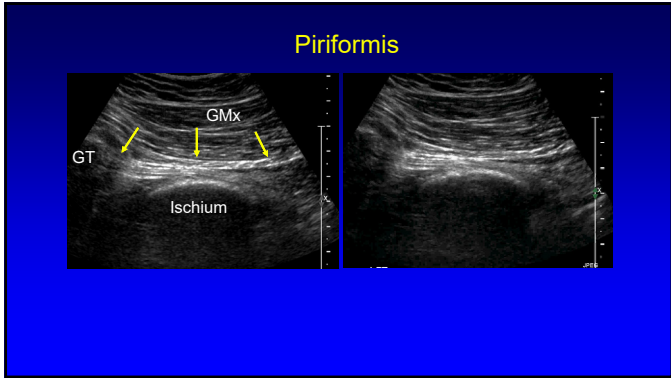
23

### Piriformis

- **Technique:**
  - Low frequency **curvilinear** transducer
  - Axial plane
  - Move transducer inferior to SI joint
  - Angle transducer: inferior and lateral
  - Rotate hip internally: movement of tendon

Finoff JT et al. J Ultrasound Med 2008; 27:1157

24



25

### Sonographic Technique: thigh

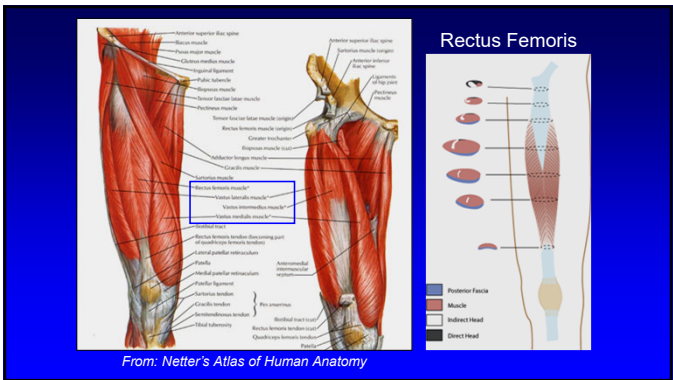
- Standardized sequence
  - Anterior: quadriceps femoris
  - Medial: adductors
  - Posterior: hamstrings
- Focused examination
- Transducers:
  - 5 MHz curvilinear (*ensure global evaluation!*)
  - 10 MHz linear

26

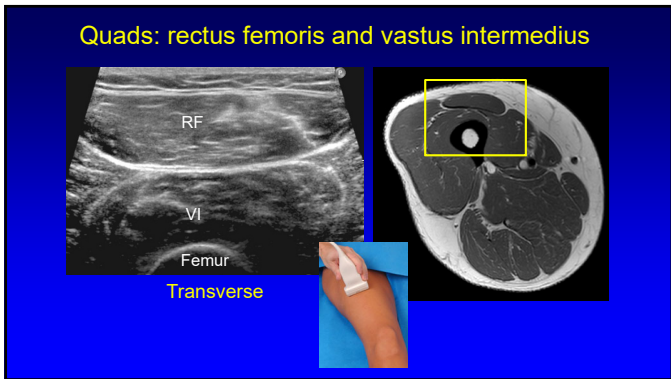
### Sonographic technique: thigh

- **Anterior**
  - Rectus femoris
  - Vastus intermedius
  - Vastus lateralis
  - Vastus medialis
- Transducers:
  - 10 – 12 MHz linear
  - <10 MHz curvilinear if needed

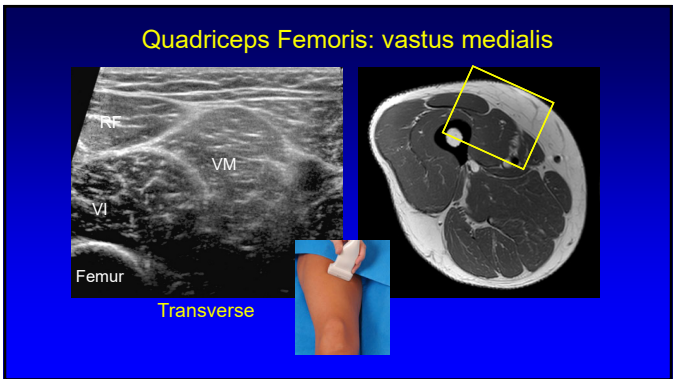
27



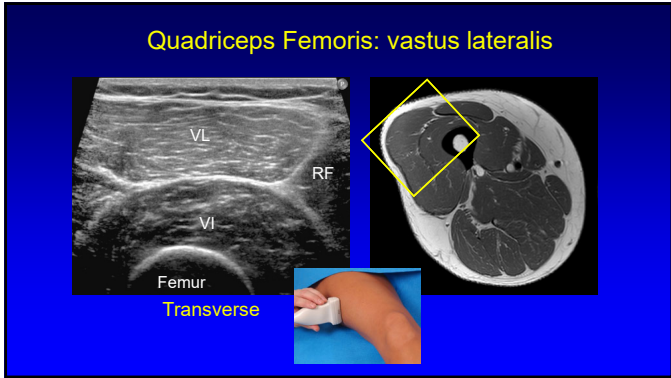
28



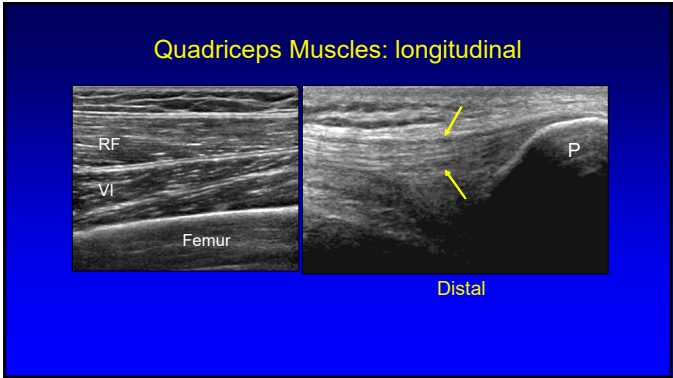
29



30



31

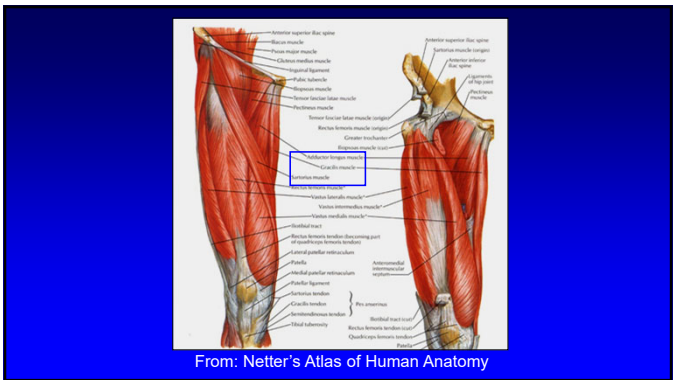


32

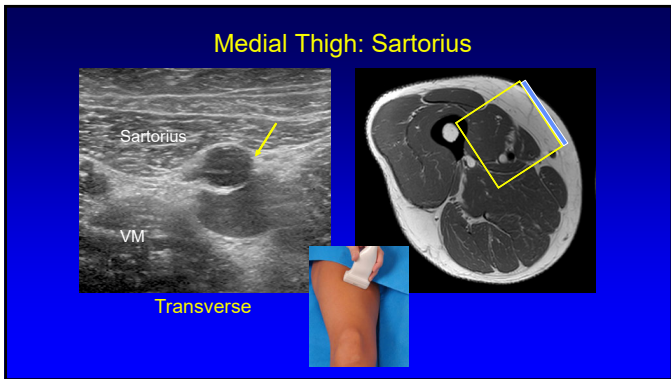
### Sonographic technique: thigh

- **Medial**
  - Adductors
  - Sartorius
  - Gracilis
- **Transducers:**
  - 10 – 12 MHz linear
  - <10 MHz curvilinear if needed

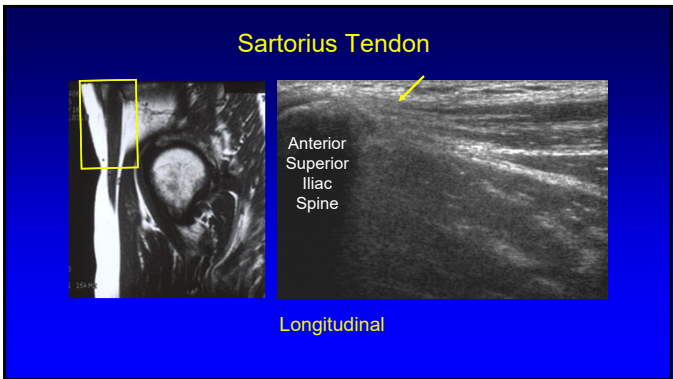
33



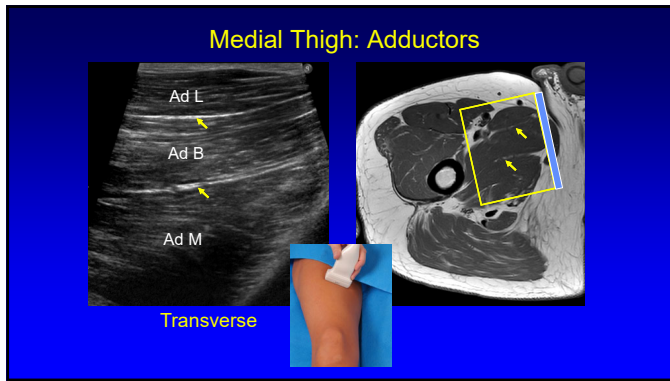
34



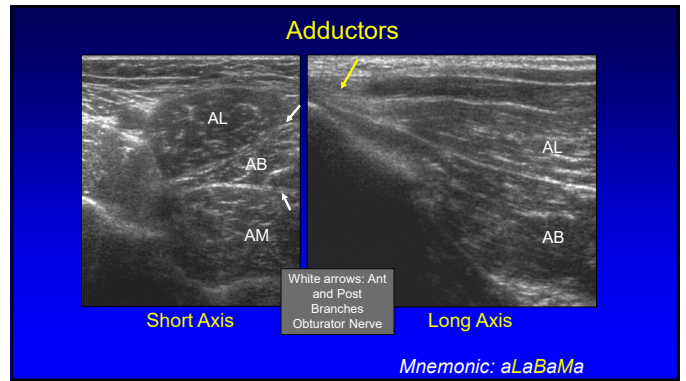
35



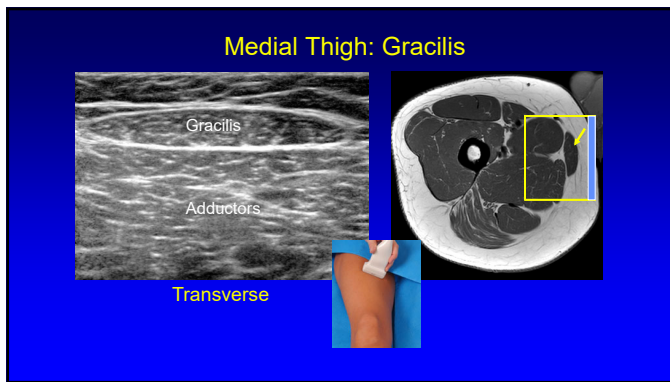
36



37



38



39

### Saphenous Nerve

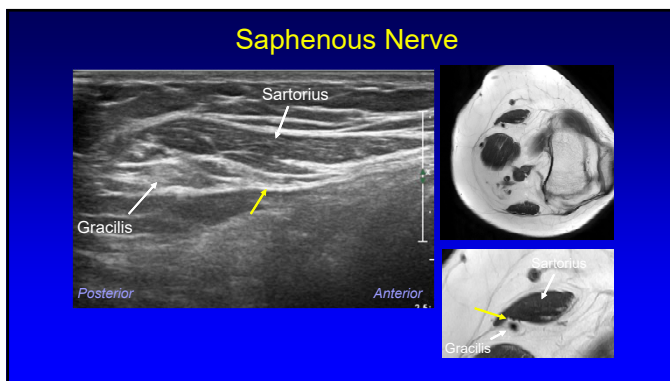
- Largest cutaneous branch of the femoral nerve
- Travels beneath sartorius:
  - Moves anterior to posterior
  - Over gracilis tendon
- Infrapatellar branch: thru sartorius
- Subcutaneous: great saphenous vein

Gracilis Sartorius  
Adductor Magnus Vastus Medialis

Posterior Anterior

Gr. Saphenous Vein

40

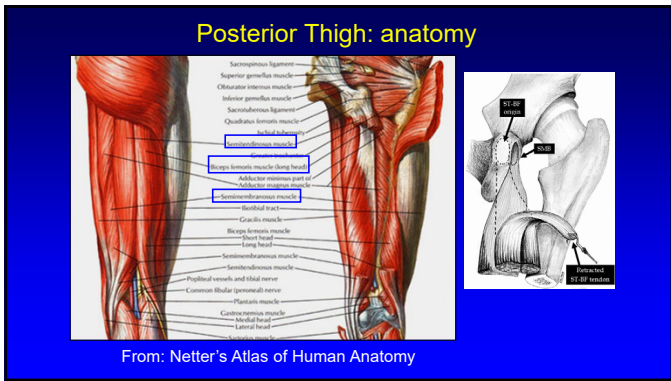


41

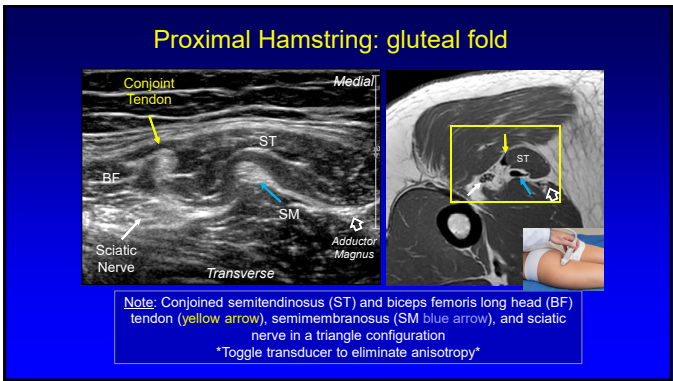
### Sonographic Technique: Thigh

- Posterior:
  - Semimembranosus
  - Semitendinosus
  - Biceps femoris
    - Long and short heads
  - Sciatic nerve
- Transducers:
  - 10 – 12 MHz linear
  - <10 MHz curvilinear if needed

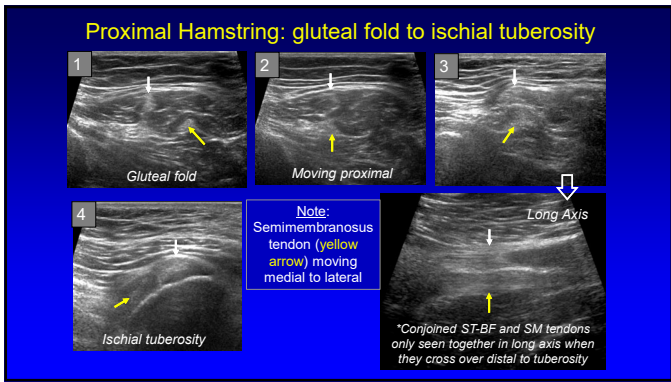
42



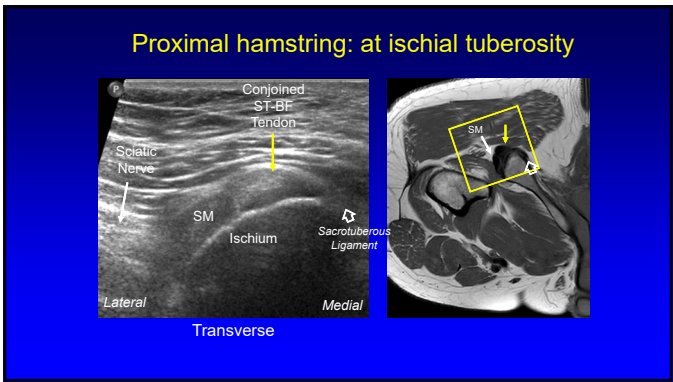
43



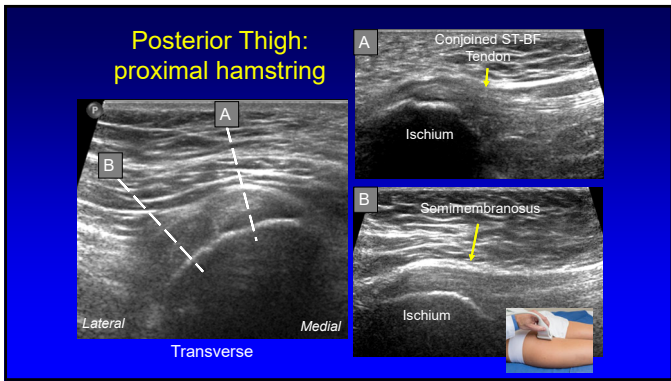
44



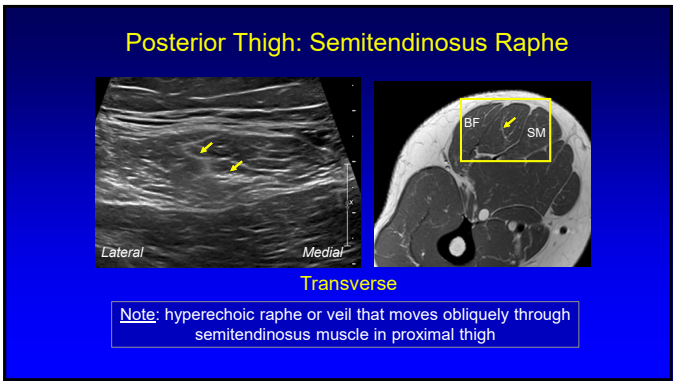
45



46

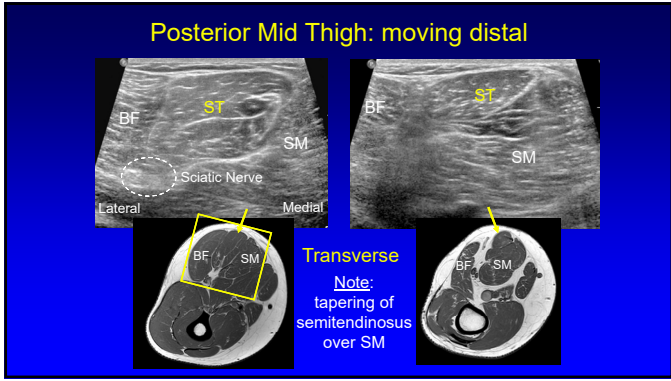


47

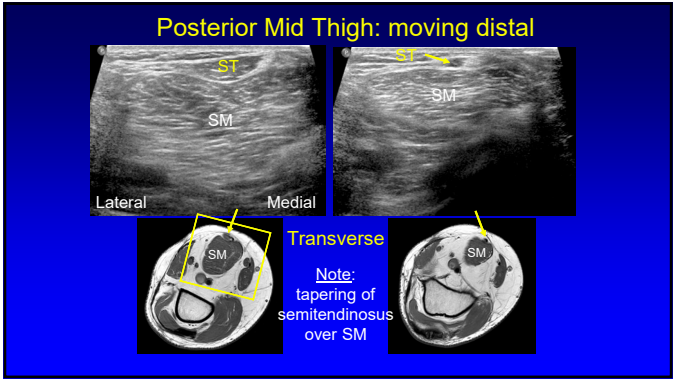


48

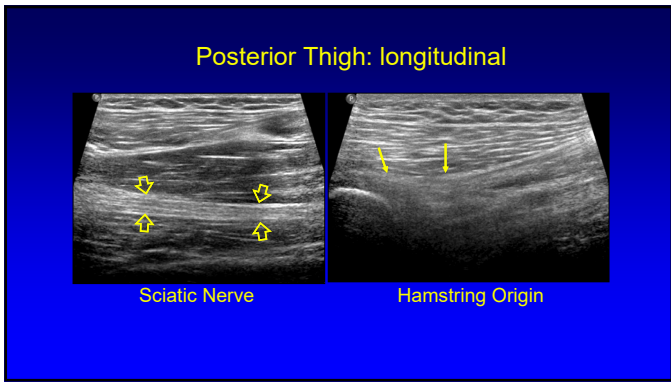




49



50



51

Take-home points:

- Know bone landmarks
- Hip evaluation:
  - Anterior: hip joint
  - Lateral: greater trochanter
- Thigh: focused examination

52

Syllabus on line and additional educational material:  
[www.jacobsonmskus.com](http://www.jacobsonmskus.com)

Twitter handle: @jjacobsn

53