

Elbow Ultrasound: Anatomy and Scanning Techniques

Jon A. Jacobson, MD FACR

Professor of Radiology
Section Chief, Musculoskeletal Imaging



1

Disclosures

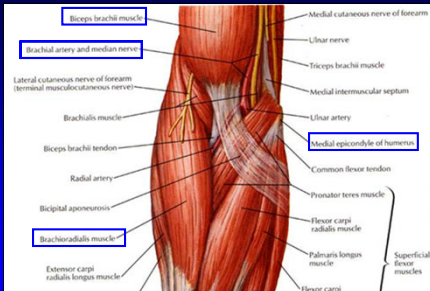
- Consultant: Bioclinica
- Book Royalties: Elsevier
- Contractor: POCUS PRO
- Advisory Board: Philips
- Not relevant to this talk

Syllabus and other educational material can be found at www.jacobsonmskus.com

Note: all images from the textbook *Fundamentals of Musculoskeletal Ultrasound* are copyrighted by Elsevier Inc.

2

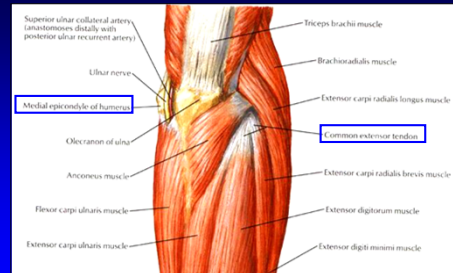
Anatomy: anterior



From: Netter's Atlas of Human Anatomy

3

Anatomy: posterior



From: Netter's Atlas of Human Anatomy

4

Sonographic Technique:

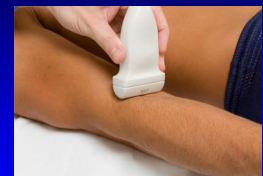- Standardized sequence
 - Anterior
 - Medial
 - Lateral
 - Posterior
- Focused examination
- Transducers: 10 - 17 MHz linear

5

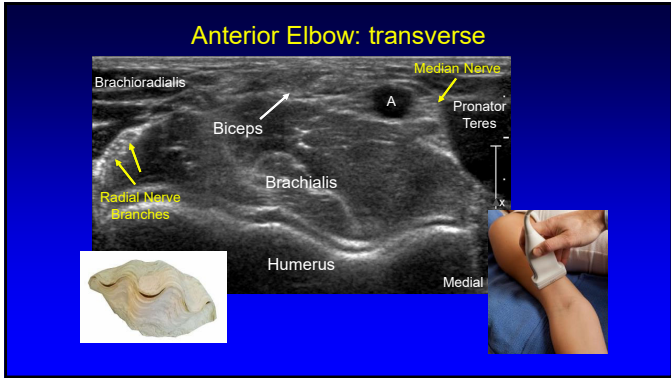
Technique: anterior

elbow extended

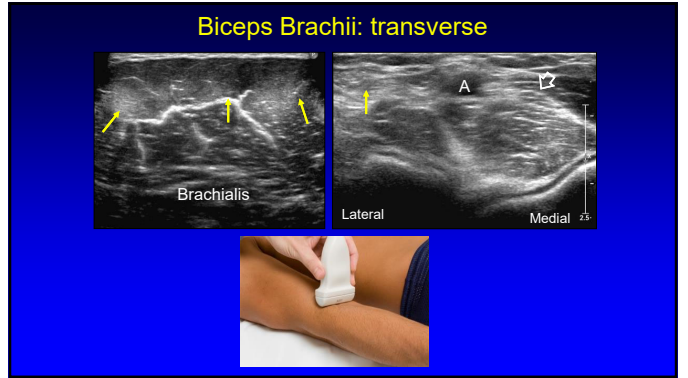
- Biceps brachii
- Brachialis
- Coronoid and radial recesses



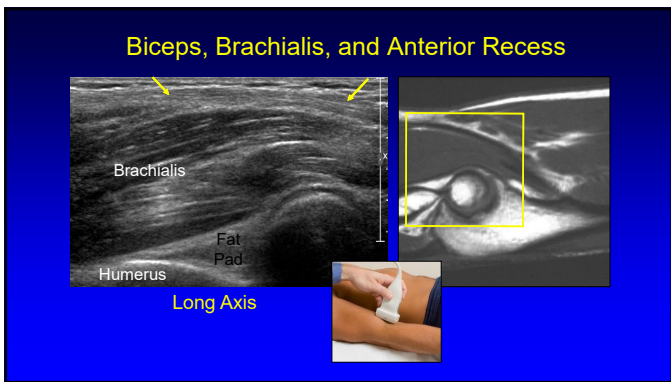
6



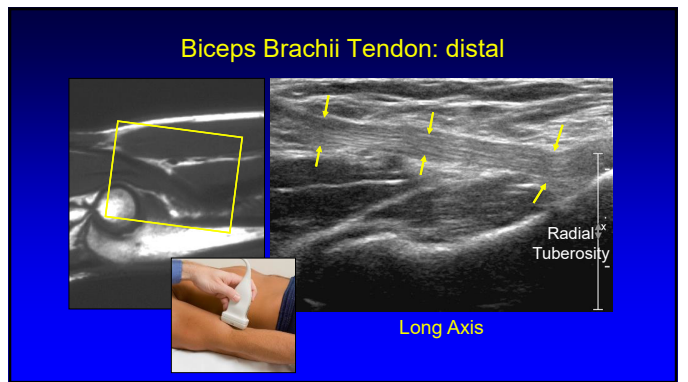
7



8



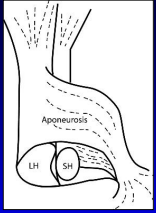
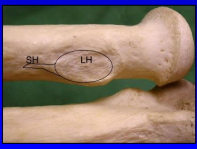
9



10

Biceps Brachii:

- Insertion: radial tuberosity
 - Short head: superficial, distal
 - Long head; deep, proximal
- No synovial sheath
- Bicipitoradial bursa

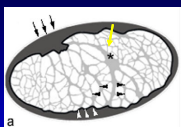
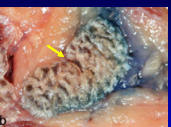



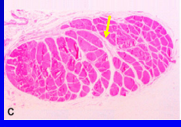
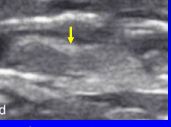
From: Eames M., et al. J Bone Joint Surg 2007;89:1044

J B J S

11

Biceps Brachii: Terminal Bifurcation

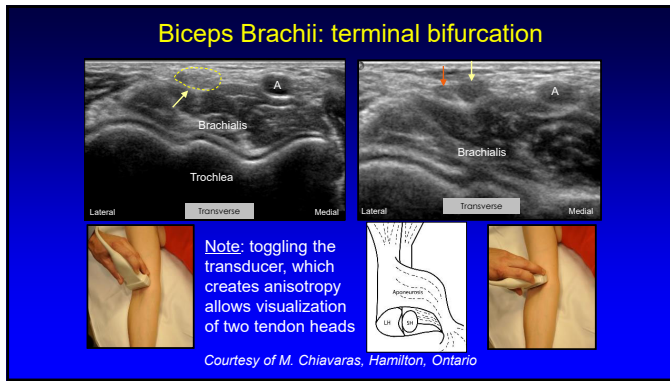



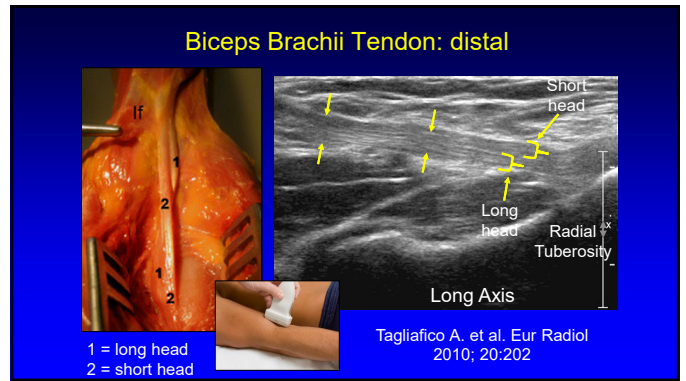
Note: endotenon septum (asterisk and arrows)

From: Blasi M., et al. Surg Radiol Anat 2014; 36:17

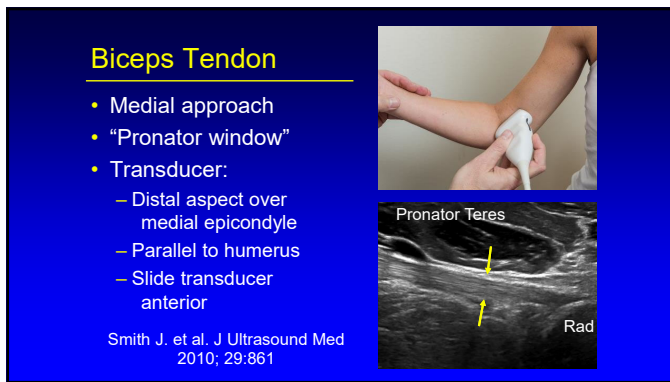
12



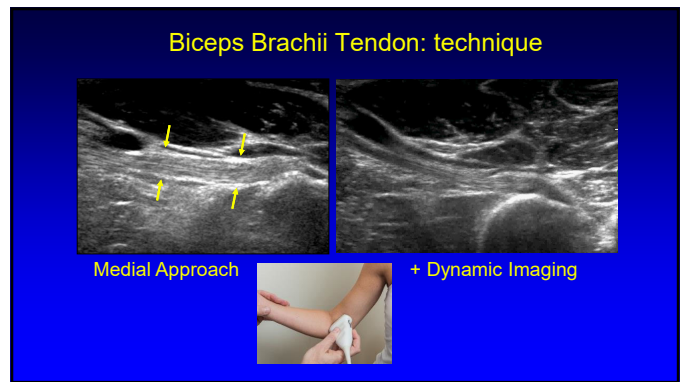
13



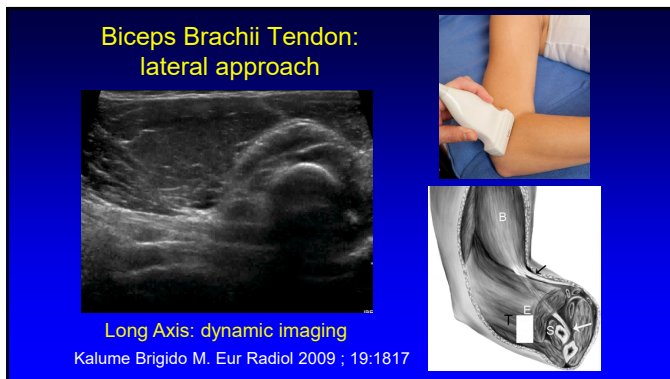14



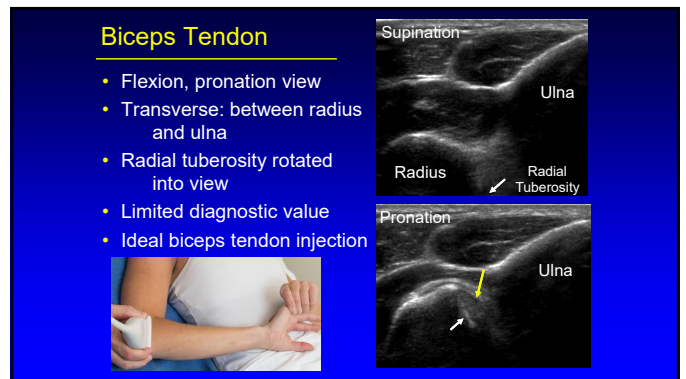
15



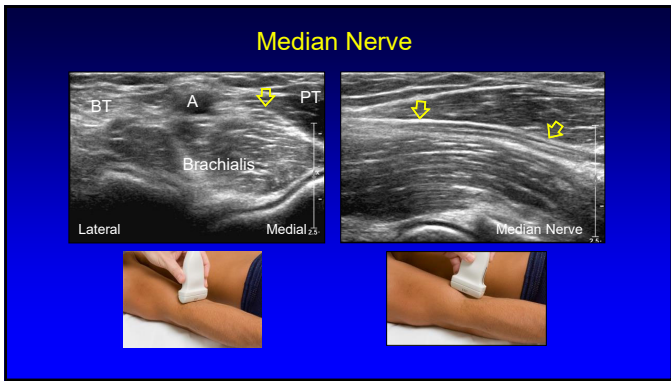
16



17



18



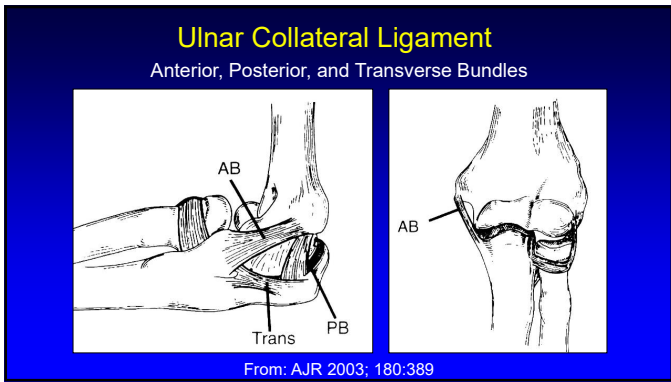
19

Technique: medial

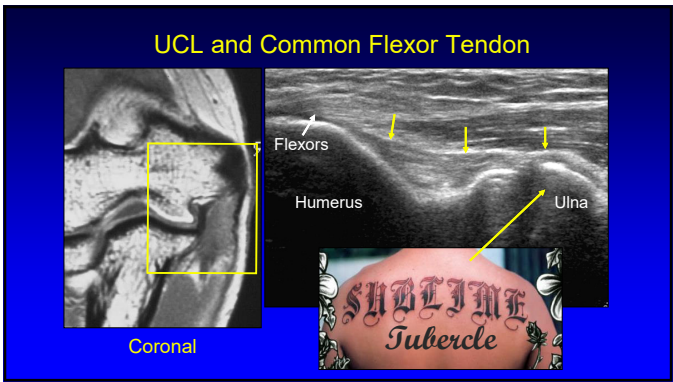
elbow partially flexed

- Ulnar collateral ligament
 - Anterior bundle
- Common flexor tendon
- Cubital tunnel
 - Ulnar nerve

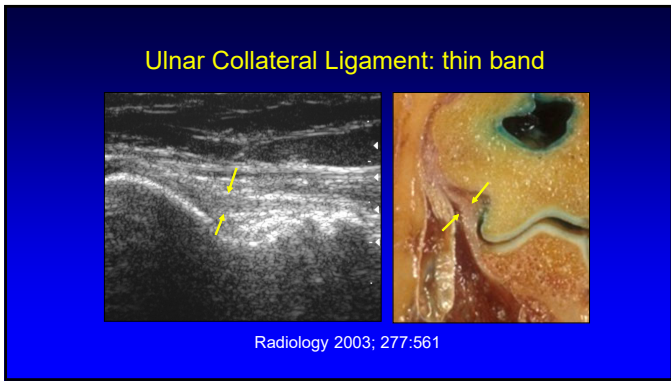
20



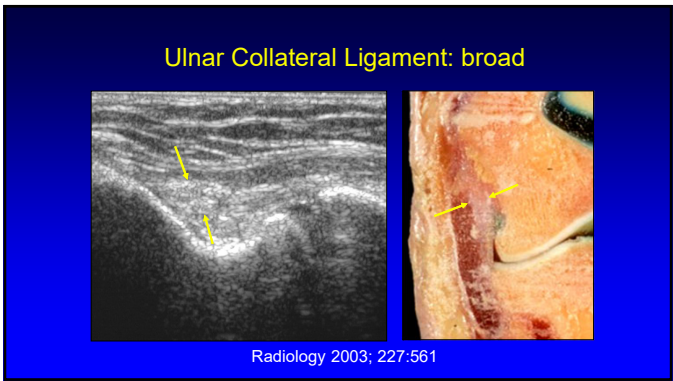
21



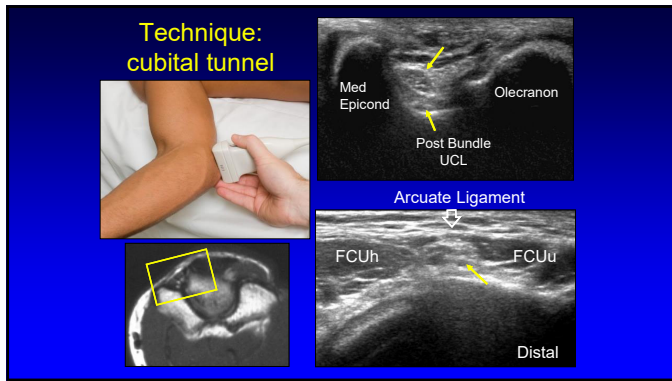
22



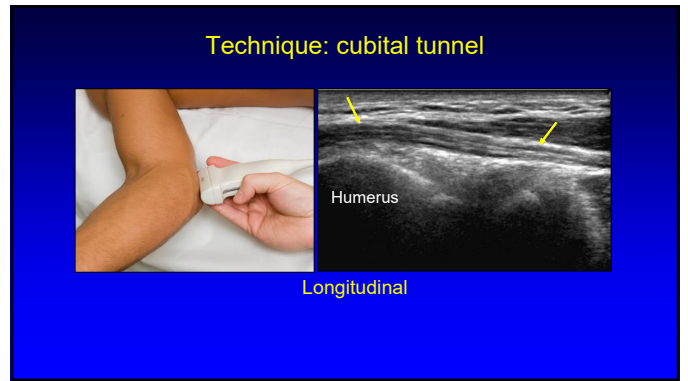
23



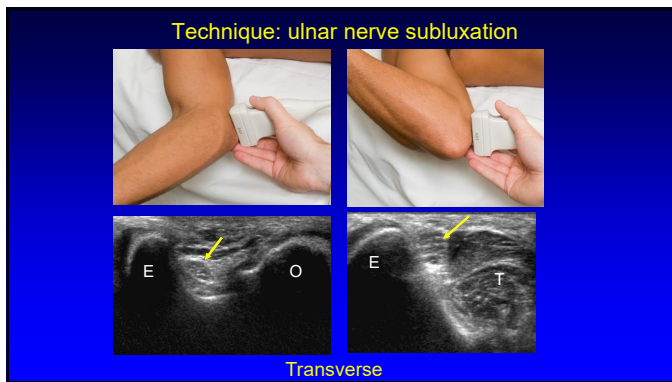
24



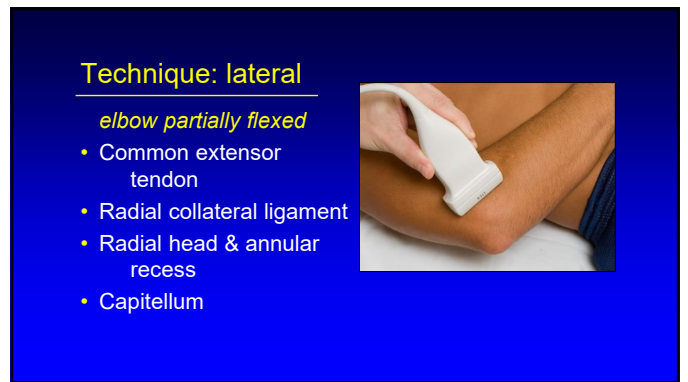25



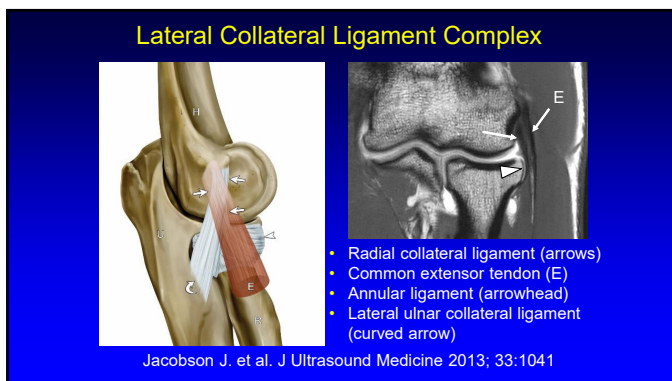
26



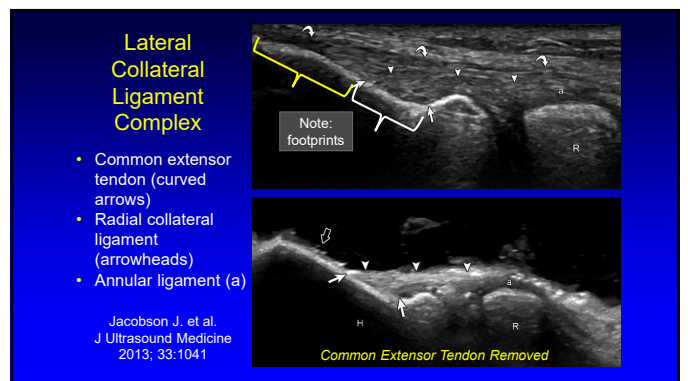
27



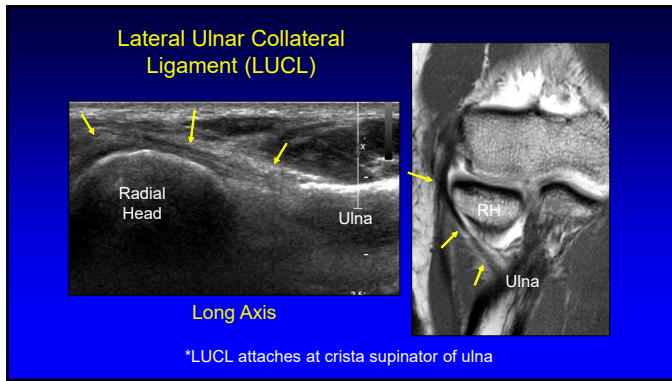
28



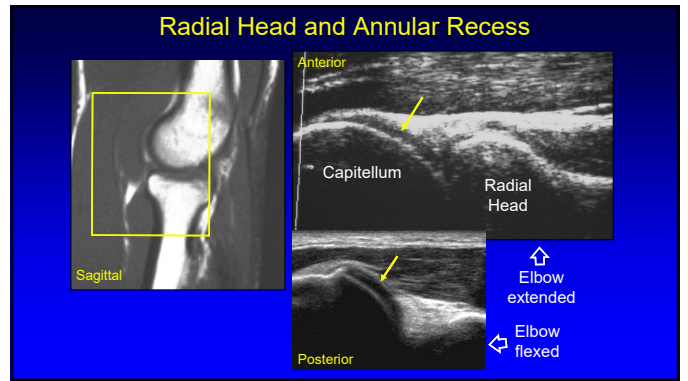
29



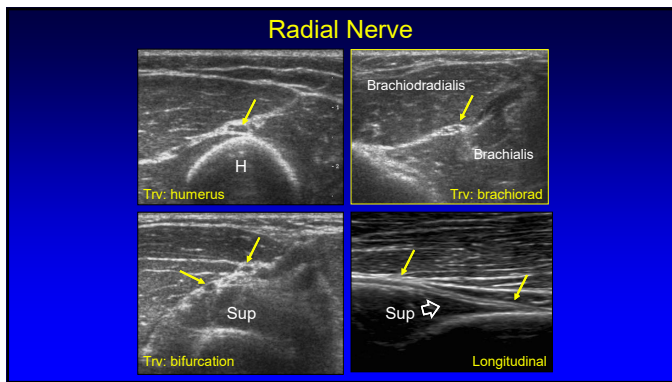
30



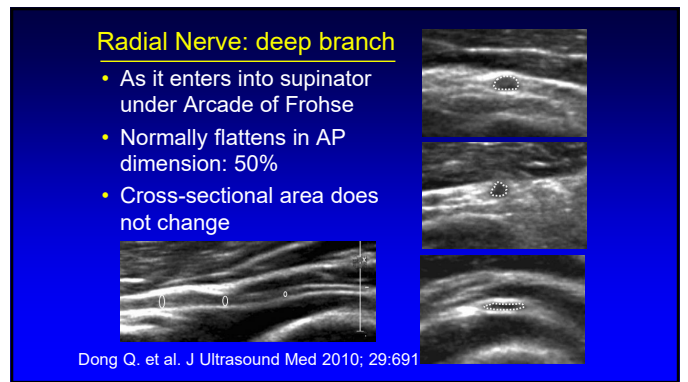
31



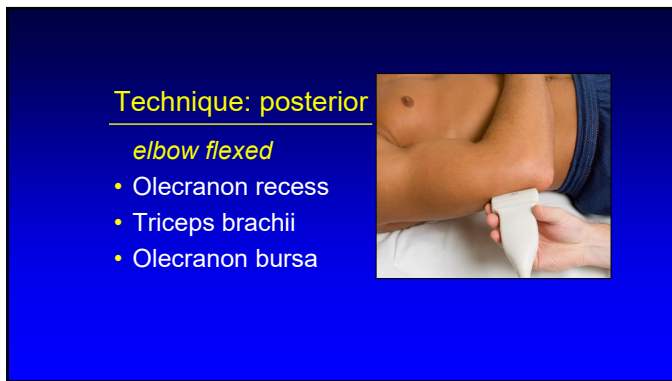
32



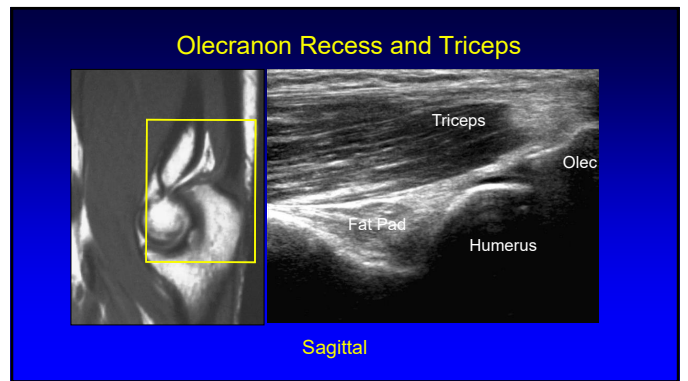
33



34

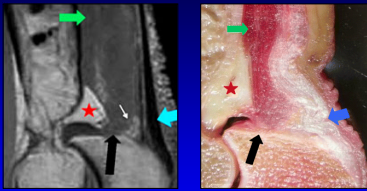


35



36

Anatomy of the Distal Triceps Brachii

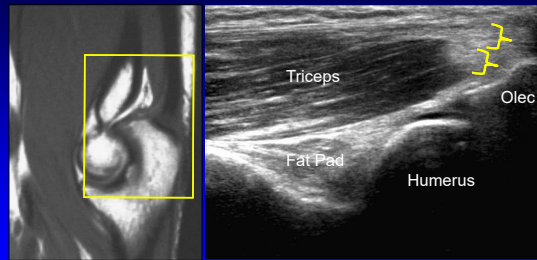


- Superficial (blue arrow): long + lateral heads
- Deep (black arrow): medial head
 - Primarily muscular insertion

*From Resnick, Skeletal Radiol 2009; 38:171

37

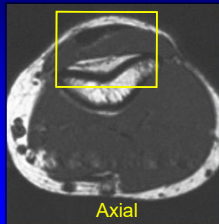
Olecranon Recess and Triceps



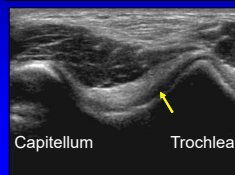
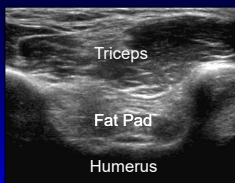
Sagittal

38

Olecranon Recess and Triceps



Axial



Capitellum

Trochlea

39

Take-home Points:

- Follow a scanning protocol
- Do not focus exam too much
- Use bone landmarks:
 - Orientation
 - Where tendon abnormalities occur
- Biceps scanning technique

40



Syllabus on line and additional educational material:
www.jacobsonmankus.com

Twitter handle: @jjacobsn

41