

# Foot and Ankle Ultrasound: Anatomy and Scanning Technique

Jon A. Jacobson, MD FACR

Professor of Radiology  
Section Chief, Musculoskeletal Imaging



1

## Disclosures

- Consultant: Bioclinica
- Book Royalties: Elsevier
- Contractor: POCUS PRO
- Advisory Board: Philips
- Not relevant to this talk

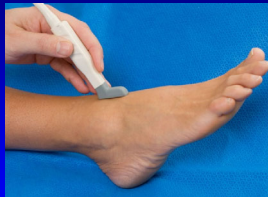Syllabus and other educational material can be found at [www.jacobsonmskus.com](http://www.jacobsonmskus.com)

Note: all images from the textbook *Fundamentals of Musculoskeletal Ultrasound* are copyrighted by Elsevier Inc.

2

## Technique: anterior

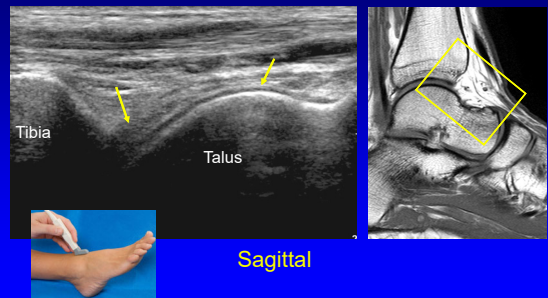
- Anterior joint recess
  - Plantar flexion
  - Hyperechoic extracapsular fat pad
  - Hypoechoic hyaline cartilage



AJR 1998; 170:1231

3

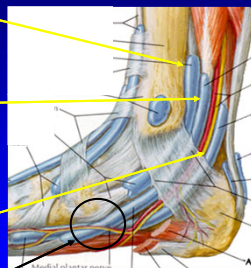
## Tibiotalar Joint



4

## Medial Tendons

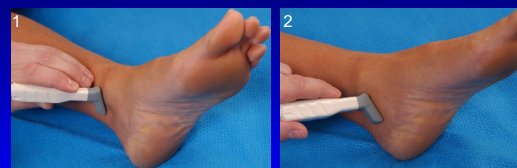
- Tibialis posterior
  - Navicular > cuneiforms
  - Metatarsals 2 – 4
- Flexor digitorum longus
  - Distal phalanges #2 – 5
- Tibial nerve, artery, veins
- Flexor hallucis longus
  - Base of distal 1<sup>st</sup> phalanx
  - \*Knot of Henry: FHL & FDL



From: Netter's Atlas of Human Anatomy

5

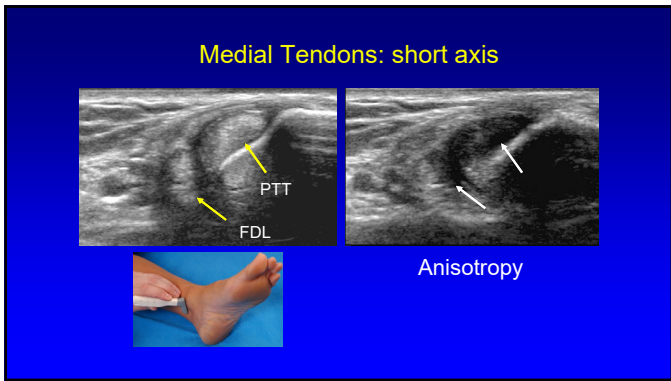
## Medial Tendons: short axis



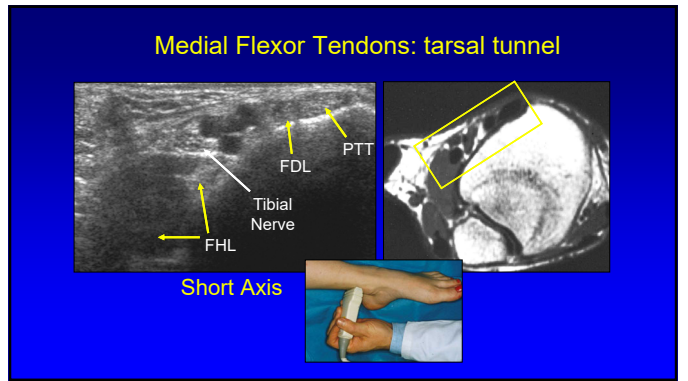
Transverse

Coronal

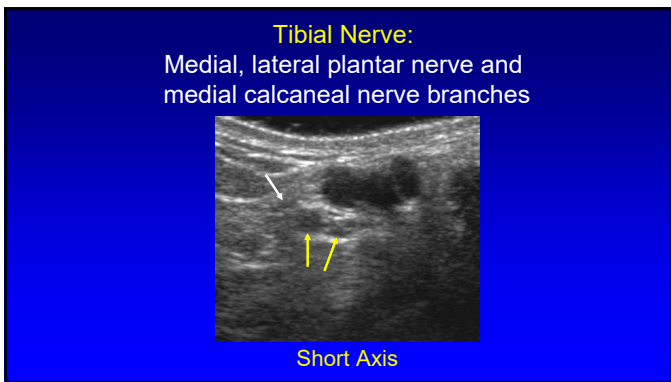
6



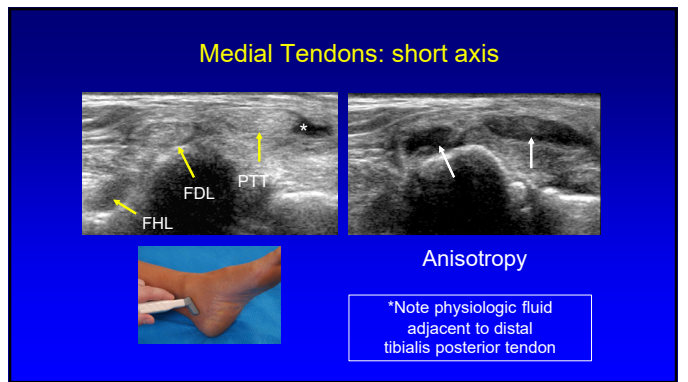
7



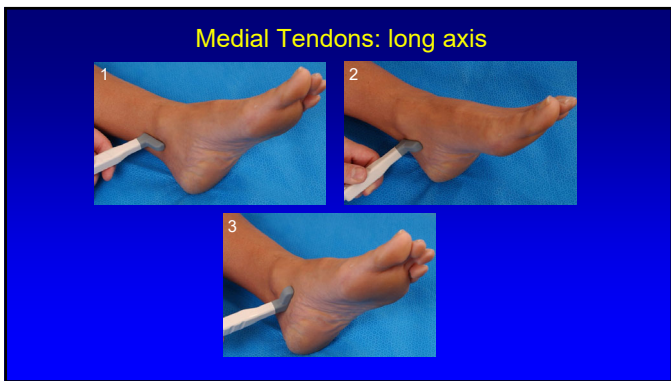
8



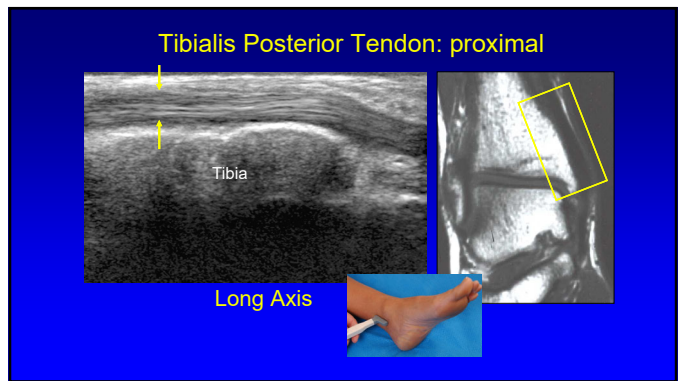
9



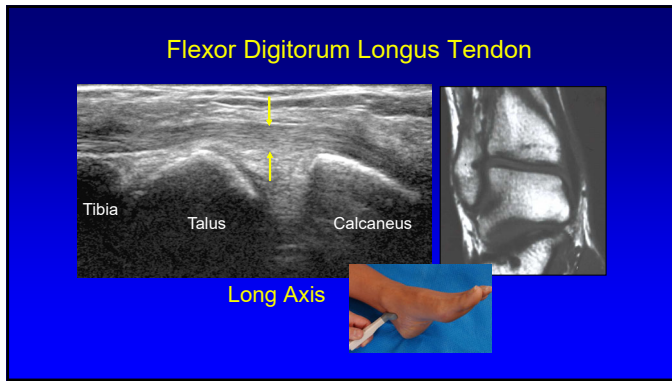
10



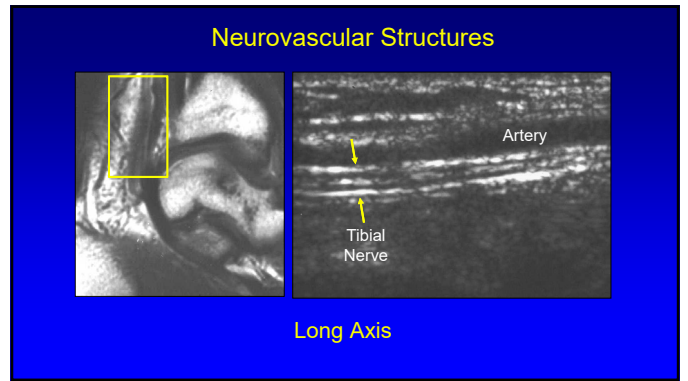
11



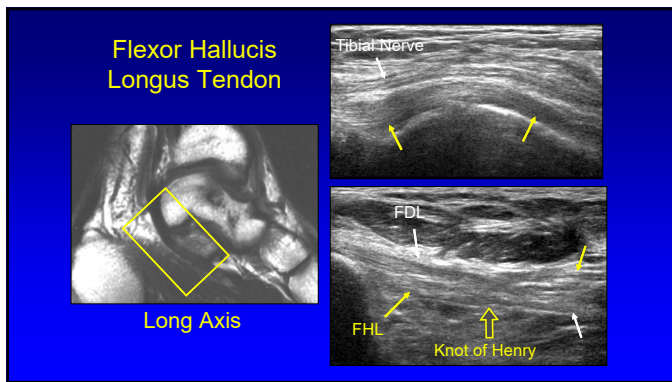
12



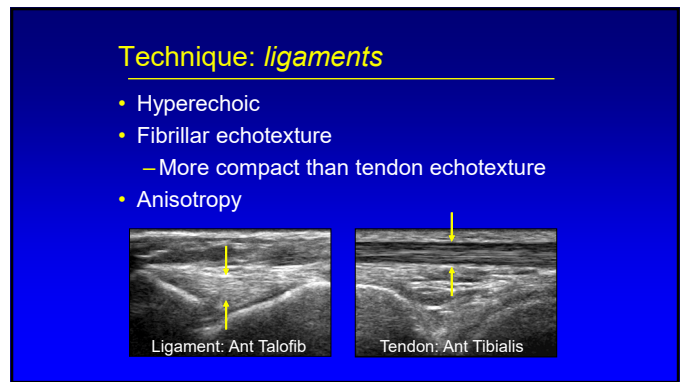
13



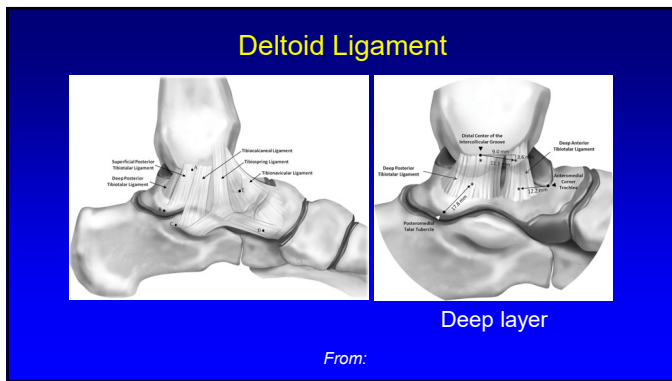
14



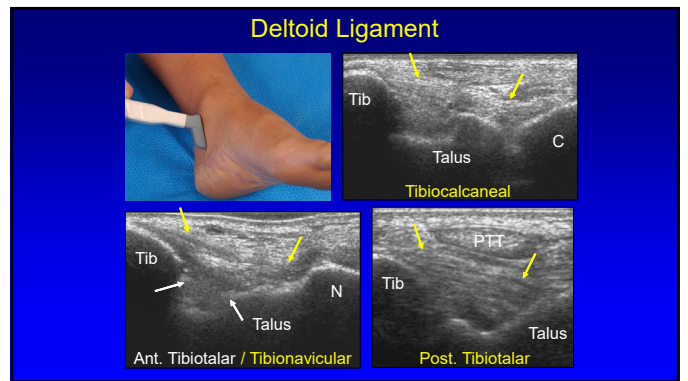
15



16



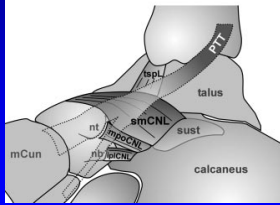
17



18

## Spring Ligament Complex

- Calcaneonavicular ligament
  - Superomedial
    - Perpendicular to distal PTT
  - Mediolateral oblique
  - Inferoplantar longitudinal

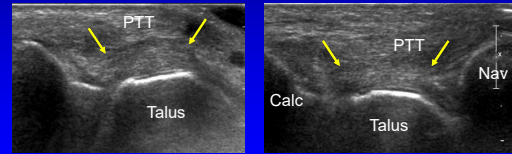


From: Radiology 2005; 237:242

19

## Spring Ligament Complex:

- Superomedial component
- Normal: hyperechoic, 2.8 – 3.4 mm thick



Harish, Skeletal Radiol 2007; 36:221

20

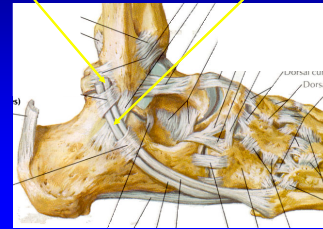
## Technique: lateral

- Tendons:
  - Peroneus longus
  - Peroneus brevis:
    - May be oval or crescent shaped, against bone
  - Dynamic evaluation: tendon subluxation
    - Dorsiflexion and eversion

21

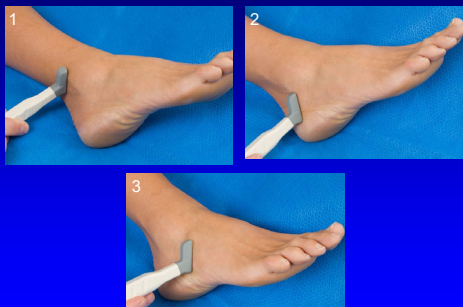
## Lateral Tendons

- Peroneus brevis:
  - Oval or crescent shaped
  - Inserts of 5<sup>th</sup> metatarsal
- Peroneus longus
  - Plantar 1<sup>st</sup> MT base
  - Medial cuneiform



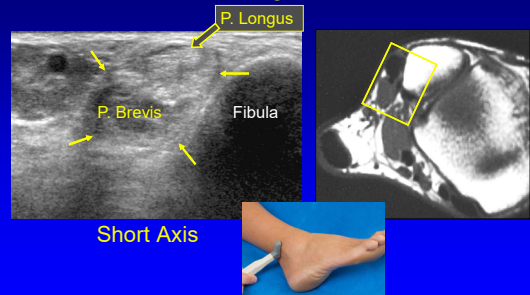
22

## Peroneal Tendons: short axis

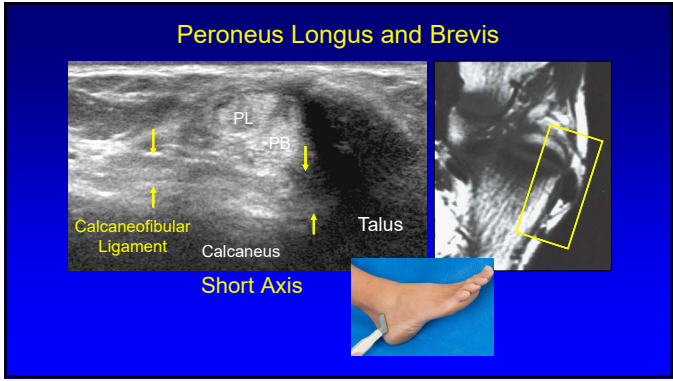


23

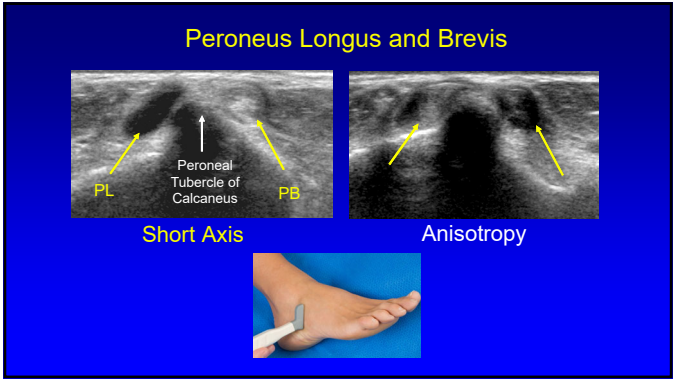
## Peroneus Longus and Brevis



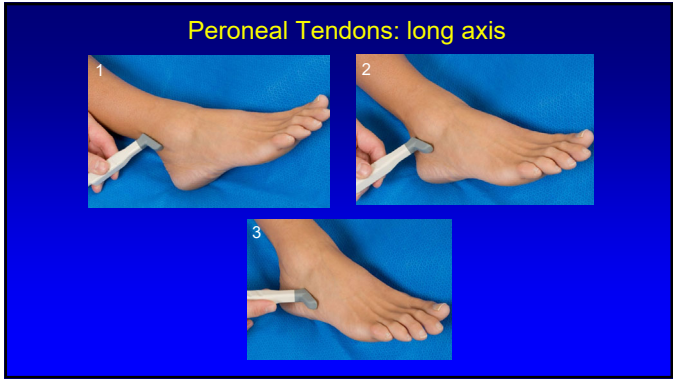
24



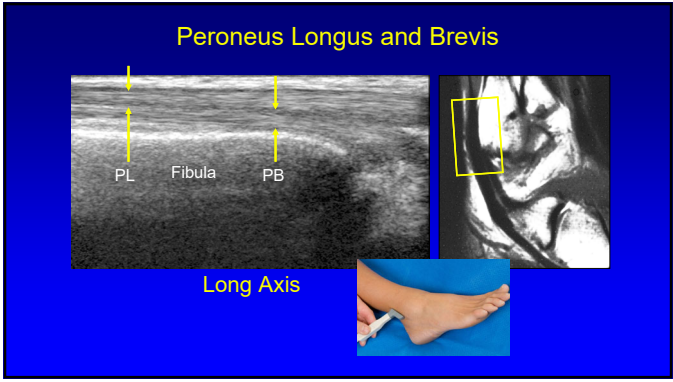
25



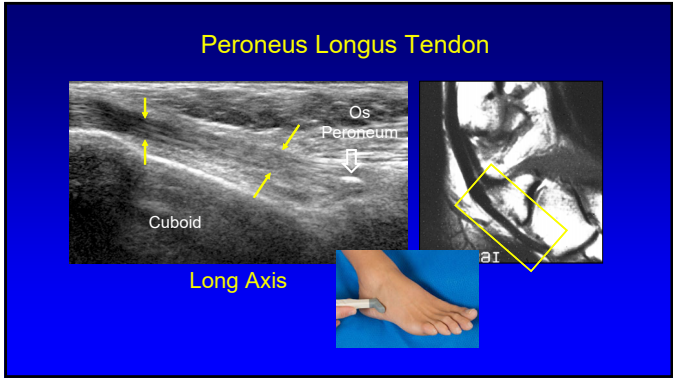
26



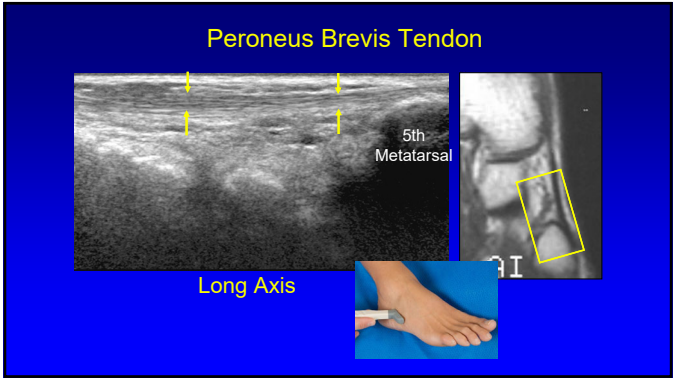
27



28



29



30

**Technique: lateral**

- Anterior talofibular
- Calcaneofibular
- Posterior talofibular
- Anterior tibiofibular
- Posterior tibiofibular

From: Netter's Atlas of Human Anatomy

31

**Anterior Talofibular Ligament**

Fibula  
Talus  
Long Axis

32

**Anterior Talofibular Ligament**

Anisotropy  
Long Axis

33

**Calcaneofibular Ligament**

Fibula  
Talus  
Calcaneus  
PB  
PL  
Long Axis

34

**Anterior Inferior Tibiofibular Ligament**

Fib  
Tib  
Long Axis

35

**Inferior Tibiofibular Ligament**

- Several bands
- Accessory inferior band (Bassett ligament)
  - Seen in 80 – 90%: more horizontal
  - Potential site of impingement

Fib  
Tib

Radiology 2010; 254:827

36

**Technique: posterior**

- Tendons / Muscles:
  - Achilles
  - Flexor hallucis longus

37

**Achilles Tendon: proximal**

Flexor Hallucis Longus  
Tibia  
Tibia  
Talus

**Long Axis**

38

**Achilles Tendon: distal**

Calcaneus  
Talus  
Calcaneus  
Talus

**Long Axis**

39

**Achilles Tendon**

Plantaris  
Tibia  
Talus

**Short Axis**

40

**Plantar Fascia or Aponeurosis:**

- 3 components:
  - Medial cord
  - Lateral cord
  - Central cord
    - Most important
    - Fibers envelop flexor digitorum brevis

DB  
PAM  
PAC  
PAL  
C

RadioGraphics 2000; 20:181

41

**Plantar Fascia**


Calcaneus  
Calcaneus

**Long Axis**

42

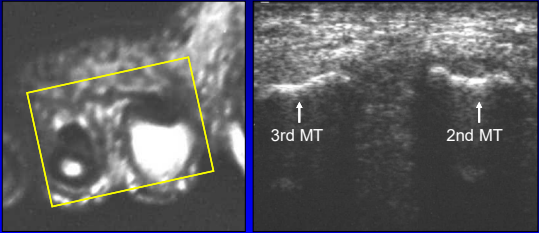
**Technique: *other***

- Interdigital space
  - Normal digital nerve difficult to visualize
  - Morton's neuroma



43

**Interdigital Space**



3rd MT      2nd MT

**Short Axis to Metatarsals**

44



Syllabus on line and additional educational material:  
[www.jacobsonmskus.com](http://www.jacobsonmskus.com)

Twitter handle: @jacobsn

45