

Ultrasound Evaluation of Wrist and Hand Pathology

Jon A. Jacobson, MD FACR

Professor of Radiology
Section Chief, Musculoskeletal Imaging



1

Disclosures

- Consultant: Bioclinica
- Book Royalties: Elsevier
- Contractor: POCUS PRO
- Advisory Board: Philips
- Not relevant to this talk

Syllabus and other educational material can be found at www.jacobsonmskus.com

Note: all images from the textbook Fundamentals of Musculoskeletal Ultrasound are copyrighted by Elsevier Inc.

2

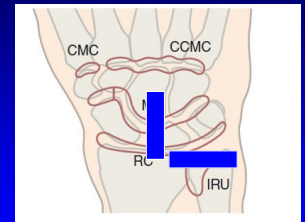
Pathology:

- Joint effusion and synovitis
- Tendon abnormalities
- Nerve entrapment
- Ligament, cartilage, and osseous injury
- Cysts and masses

3

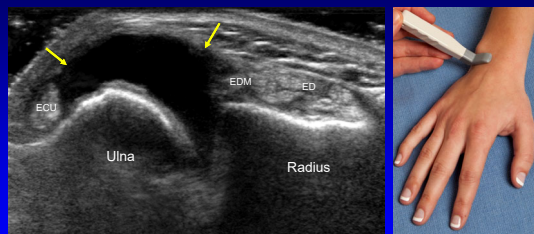
Joint Assessment: dorsal

- Wrist:
 - Radiocarpal joint (RC)
 - Midcarpal joint (MC)
 - Distal or inferior radioulnar joint (IRU)
- Hand:
 - MCP and PIP joints
 - 1st CMC (if symptomatic)



4

Joint Effusion: distal radioulnar joint



Transverse

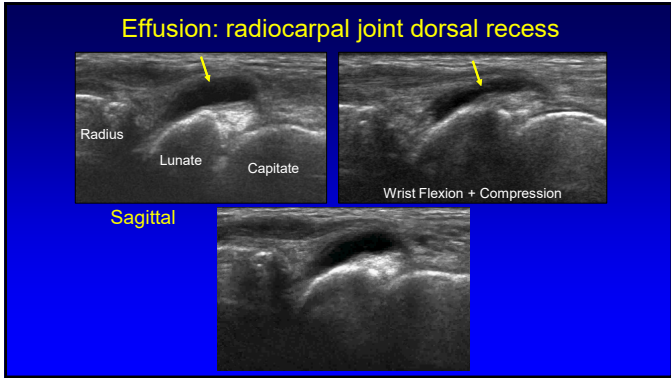
5

Joint Effusion versus Synovitis

- Anechoic and compressible = simple fluid
- If not anechoic:
 - Compressible, no hyperemia = complex fluid
 - Non-compressible, hyperemia = synovitis
- Sonography cannot differentiate sterile from septic joint fluid

AJR 2000; 174: 1353

6



7

Inflammatory Arthritis: role

- Identify synovitis and erosions
 - Prior to initiating treatment
- Determine activity: hyperemia
- Aspirate or inject
- Follow-up after therapy
 - Decreased hyperemia
 - Decreased synovial thickness

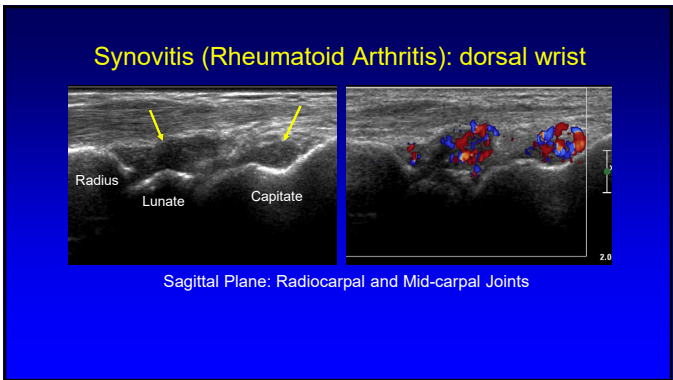
8

Arthritis: synovitis

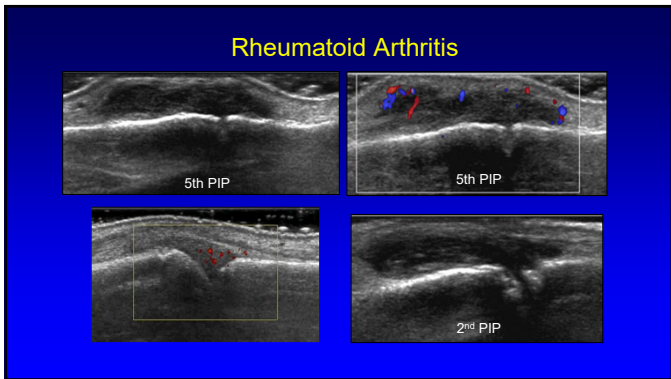
- Synovial locations:
 - Joint recess, bursa, tendon sheath
- Hypoechoic compared to adjacent subcutaneous fat
 - May be isoechoic or hyperechoic
- Hyperemia: variable
 - Represents activity of inflammation
 - Decreased: treatment (even NSAIDS)

Backhaus M, Arthritis and Rheum 1999; 42:1232

9



10



11

Pitfall Alert! Normal Joint Capsule Appearance

- Dorsal capsule thickness:
 - MCP 1: 6 mm
 - MCP 2: 4 mm
 - MCP 3-5: 3 mm
 - RC joint: 4 mm
 - MC joint: 3 mm
- Do not interpret as abnormal synovial hypertrophy

*Falkowski A et al. Eur J Radiology 2020; 124

MCP2
PP

Radius
Lunate
Capitate

*Note normal echogenic triangular fibrocartilage (white arrow)

12

Erosions

- US criteria:
 - Disrupted cortex, two planes
 - Adjacent synovitis increases specificity
- US better than radiographs¹
- 29% false-positive rate compared to CT²
- 40% sensitivity³

¹Lopez-Ben, et al. Skeletal Radiol 2004; 33: 80
²Finzel S, et al. Arth Rheumatism 2011; 63:1231
³Dohn UF M, Arthritis Res Ther 2006; 8:1

13

Rheumatoid Arthritis

The image shows two views of the 2nd MCP joint. On the left, an ultrasound image shows a cortical disruption (erosion) indicated by a yellow arrow. On the right, a radiograph shows a similar erosion at the 2nd MCP, also indicated by a yellow arrow.

14

Rheumatoid Arthritis

The image shows two views of the wrist. On the left, an ultrasound image shows erosions at the ECU, Ulna, and Triquetrum, indicated by yellow arrows. On the right, a radiograph shows a yellow box highlighting the same areas.

15

Pitfall Alert!

Pseudoerosion

- Metacarpal head: dorsal
- Up to 37% of metacarpal heads: 2nd most common
- Bare area: no hyaline cartilage
- Unlike erosion:
 - Smooth
 - Maximum depth: 2 mm
 - No adjacent synovitis

Boutry N. et al. Radiology 2004; 232:716

16

Pseudoerosion: dorsal metacarpal head

The image shows two views of the dorsal metacarpal head. On the left, an ultrasound image shows a pseudoerosion (indicated by a yellow arrow) with labels ET, P, M, and a diagram below showing the anatomy. On the right, a radiograph shows a pseudoerosion (indicated by a yellow arrow) with labels ET, P, M, and a diagram below showing the anatomy.

Radiology 2004; 232:716

17

Pitfall Alert! Pseudoerosions Are Everywhere!

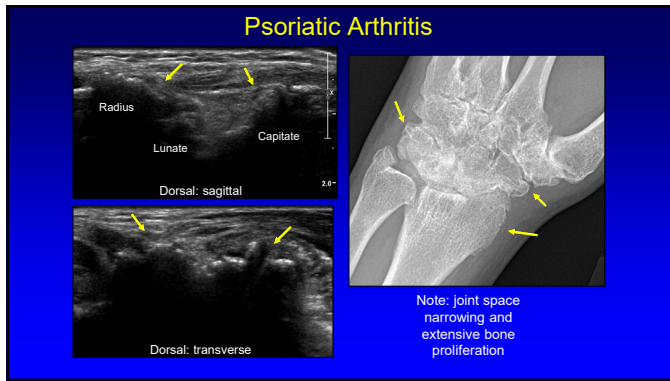
- Pseudoerosions: 100%
- Metacarpal heads: all
 - 2nd: 92%
 - 3rd: 86%
- Carpal bones:
 - Lunate: 82%
 - Triquetrum: 84%
 - Distal ulna: 22%

*Falkowski A et al. Eur J Radiology 2020; 124

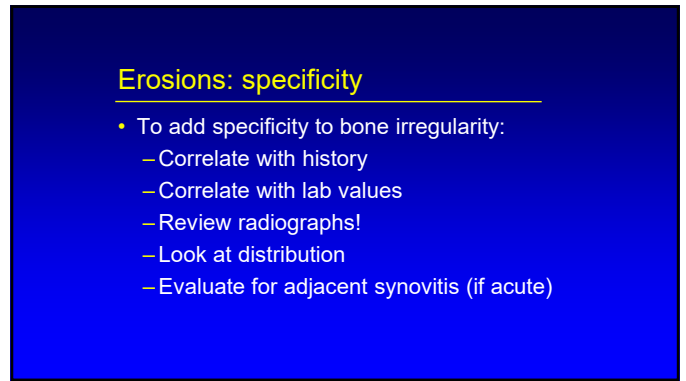
The image shows four ultrasound images. Top left: 3rd MCP: sagittal view showing a pseudoerosion (yellow arrow). Top right: Lunate view showing a pseudoerosion (yellow arrow). Bottom left: 3rd MCP: transverse view showing a pseudoerosion (yellow arrow). Bottom right: Ulna view showing a pseudoerosion (yellow arrow).

*Note lack of adjacent synovitis

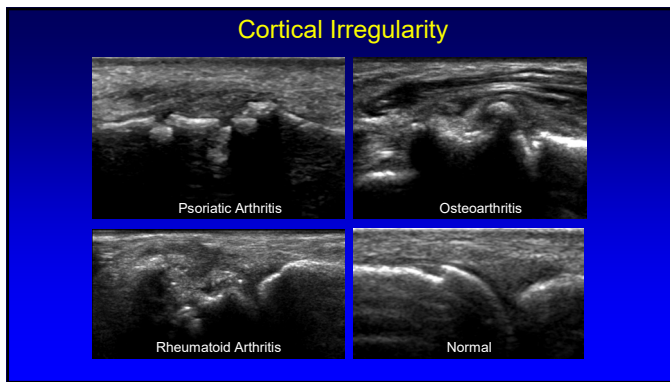
18



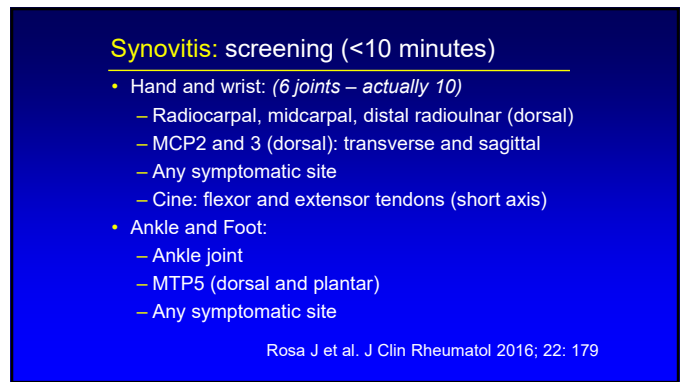
19



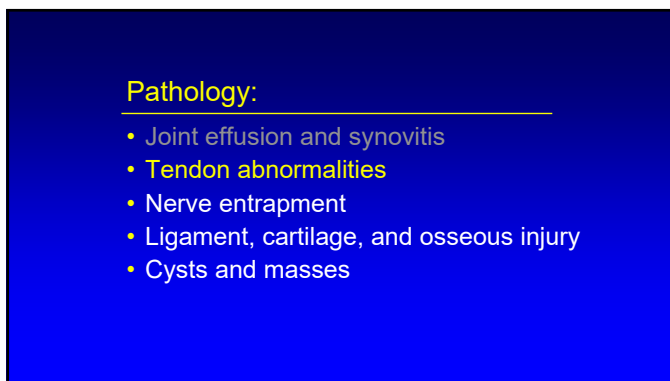
20



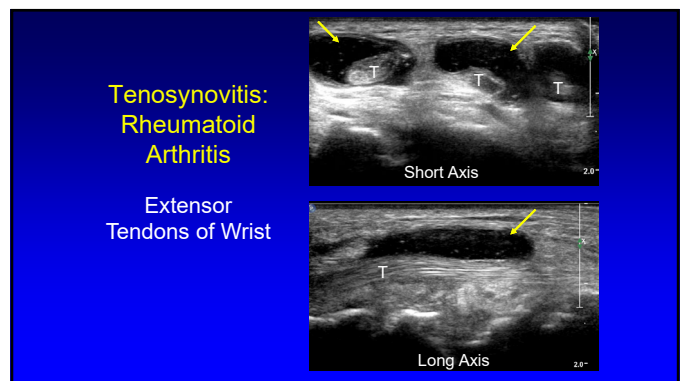
21



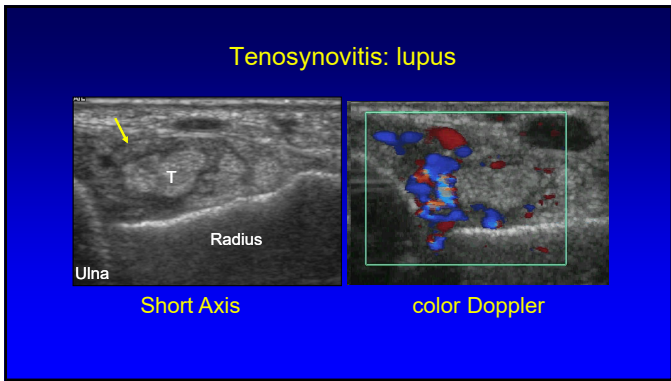
22



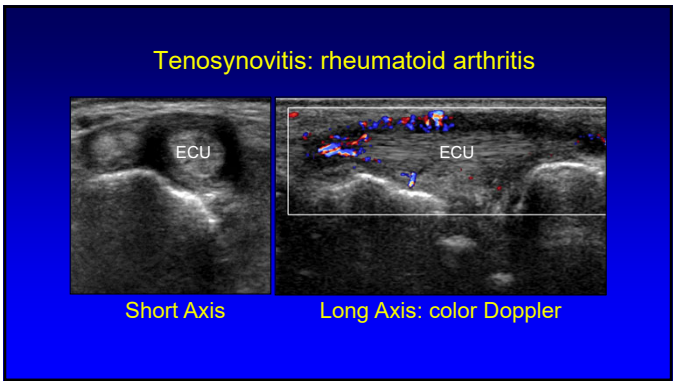
23



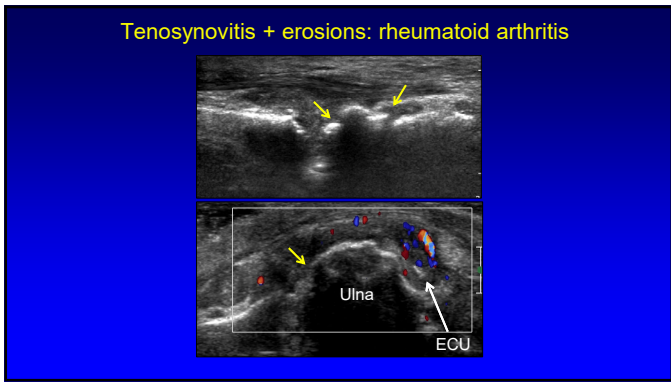
24



25



26



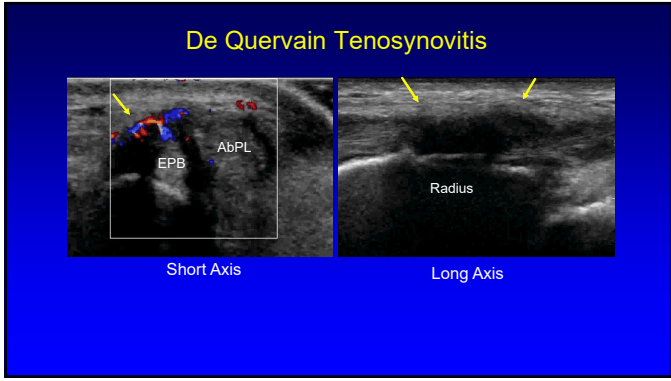
27

de Quervain Tenosynovitis:

- Stenosing tenosynovitis
 - Overuse, primary care givers
- 1st dorsal wrist compartment:
 - Extensor pollicis brevis + abductor pollicis longus
- Ultrasound findings:
 - Thick synovial sheath
 - Tendinosis
 - Cortical irregularity, hyperemia

J Ultrasound Med 1997; 16:685

28



29

Pitfall Alert! Pseudo-tenosynovitis

- Extensor retinaculum
- Hypochoic due to anisotropy
- Characteristic location
- Up to 1.7 mm thick and 23 mm in width

Anisotropy

30

Pitfall Alert!
Pseudo-tenosynovitis

- Hypoechoic muscle
- Musculotendinous junction
- Confirmed in long axis
- Normal tapering of muscle

31

Tendon Tear

- Hypoechoic or anechoic
- Disruption of tendon fibers
- Retraction: full-thickness
 - Dynamic imaging

32

Flexor Carpi Radialis

- Courses volar to triscaphe joint (scapho-trapezium-trapezoid compartment)
- FCR tendinosis and tear
- Associated triscaphe osteoarthritis

Parellada et al. Skeletal Radiol 2006; 35:572

33

Extensor Pollicis Longus: tear

Long Axis Short Axis

34

Pitfall Alert!
Pseudo-tendon Tear

- Multiple tendon fascicles
- Abductor pollicis longus
 - Incidence: 80%
 - Up to 4 fascicles
- Extensor pollicis brevis
 - Incidence: 7%
 - Up to 2 fascicles
 - May be absent
- “Lotus Root Sign”
 - Seen best distal to radius

Rousset et al. Radiology 2010; 257:427
Choi et al. Radiology 2011; 260:480

35

Pitfall Alert!
Pseud-tendon tear

- Extensor carpi ulnaris
- 6th extensor compartment
- Short axis: hypoechoic cleft
- Due to ground substance in between two heads of extensor carpi ulnaris

Ali S et al. Skelet Radiol 2015; 44:1735
Chiavaras MM et al. AJR 2014; 203:531

36

Pulley Tear

- A2 and A4 pulleys: most important
- Sagittal image
 - Bowstringing
 - Hypoechoic edema / hemorrhage
- Dynamic evaluation*

*Radiology 2002; 222:755 Radiology 1998; 206:339

37

A2 – 4 Pulley Injury

38

A4 Pulley Injury: bowstringing

From: Klauser A et al. Radiology 2002;222:755-761

Normal: < 1 mm; incomplete rupture: 1 – 3 mm; complete: 3 mm

39

Trigger Finger:

- Stenosing tenosynovitis: A1 pulley
- Thick and hypoechoic pulley
- Hyperemia: 91%
- Tendinosis: 48%
- Tenosynovitis: 55%

Guerini et al. J Ultrasound Med 2008; 27:1407

40

Trigger Finger: A1 pulley

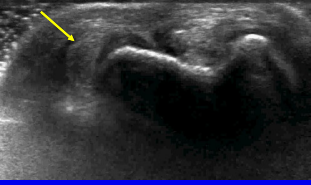
41

Trigger Finger: thumb

42

Extensor Carpi Ulnaris

- 6th extensor wrist compartment
- Dislocation:
 - Dynamic
 - Supination/pronation
 - Subsheat tear or dysfunction
- Predisposes to tendon tear and tenosynovitis

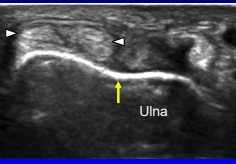


Campbell D et al. Br J Sports Med 2013; 47:1105

43

Pitfall Alert! Pseudo-subluxation

- Extensor carpi ulnaris
- 6th extensor wrist compartment
- Asymptomatic subluxation
 - Supination
 - Up to 50% out of groove
 - No tear or tenosynovitis



Lee KS et al. AJR 2009; 193:651

44


Pathology:

- Joint effusion and synovitis
- Tendon abnormalities
- **Nerve entrapment**
- Ligament, cartilage, and osseous injury
- Cysts and masses

45

Carpal Tunnel Syndrome:

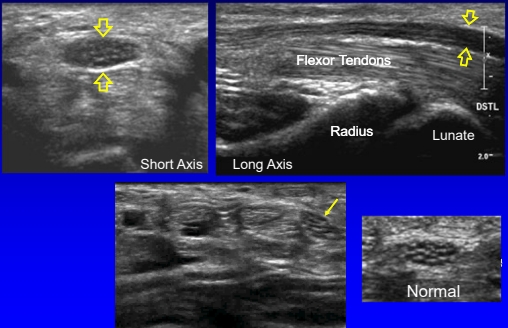
- Proximal median nerve swelling
 - Area: circumferential trace
 - Normal: <9 mm²
 - Borderline: 9 – 12 mm²
 - Abnormal: > 12 mm²
 - 12.8 mm² = moderate (83% sens, 95% spec)
 - 14.0 mm² = severe (77% sens, 100% spec)



Klauser AS et al. Sem Musculoskel Rad 2010; 14:487
Ooi et al. Skeletal Radiol 2014; 43:1387

46

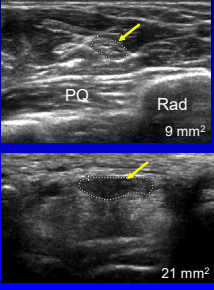
Carpal Tunnel Syndrome



47

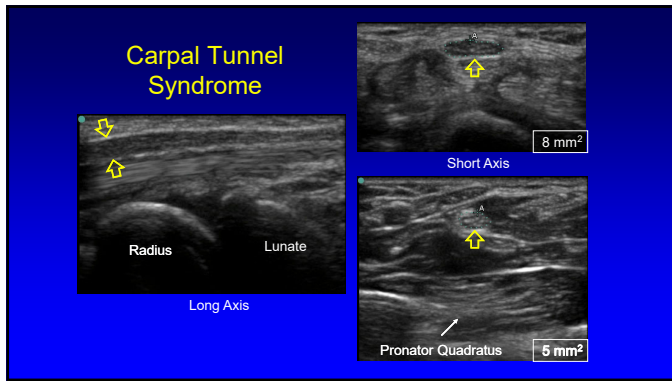
Carpal Tunnel Syndrome

- Compare areas:
 - Proximal: pronator quadratus
 - Distal: carpal tunnel
- = or >2 mm² = carpal tunnel syndrome
- 99% sensitivity
- 100% specificity

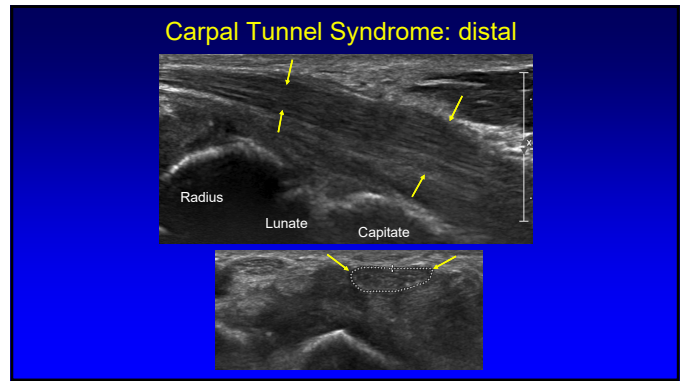


Klauser AS. Radiology 2009; 250:171

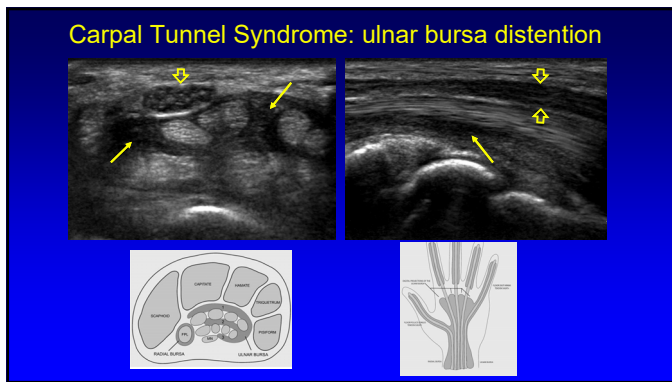
48



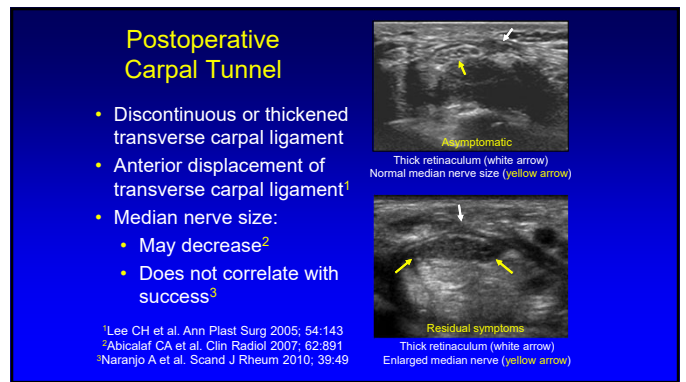
49



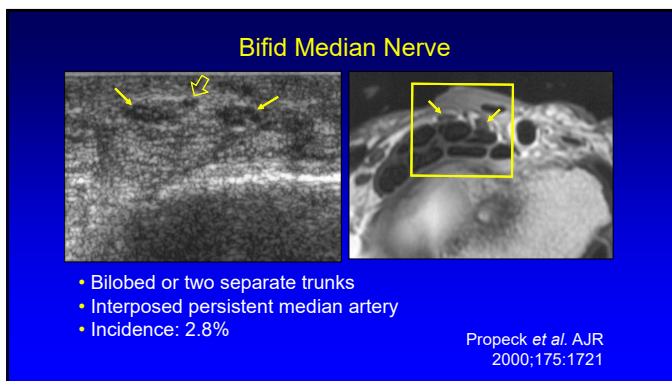
50



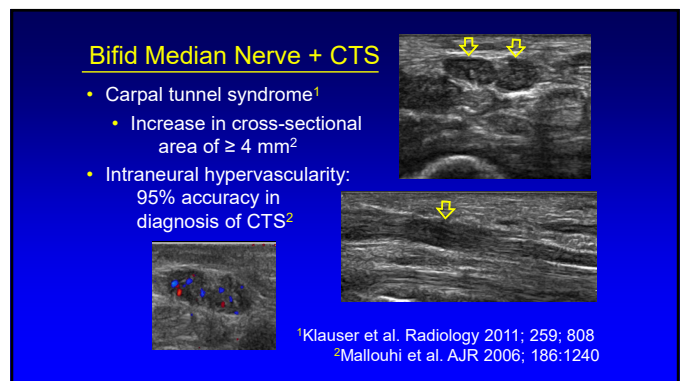
51



52



53



54

Pathology:

- Joint effusion and synovitis
- Tendon abnormalities
- Nerve entrapment
- **Ligament, cartilage, and osseous injury**
- Cysts and masses

55

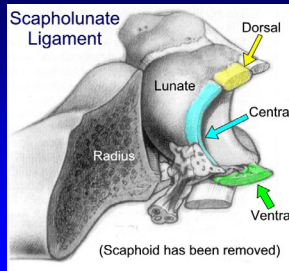
Scapholunate Ligament Tear

- Normal hyperechoic ligament not seen
- Abnormal hypoechogenicity
- Wide scapholunate space
- Dynamic imaging: fist clench

AJR 2002; 179:523

56

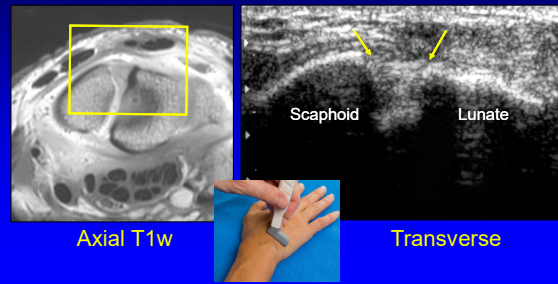
Scapholunate Ligament



From: Linkous MD, et al. Radiology 2000; 216:846

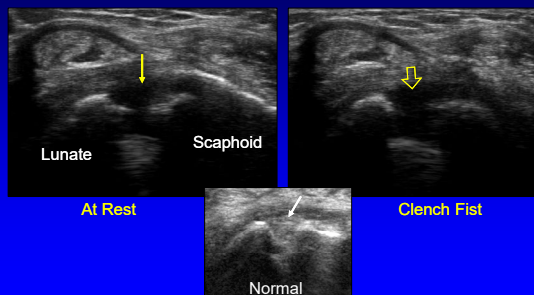
57

Dorsal Wrist: scapholunate ligament



58


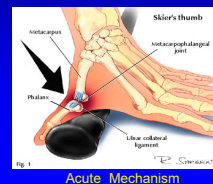
Scapholunate Ligament Tear



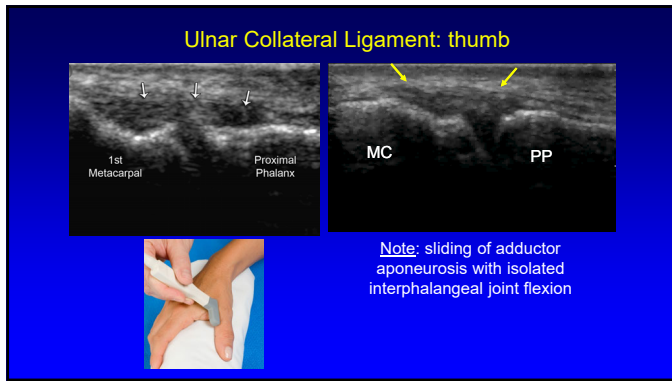
59

Gamekeeper's Thumb

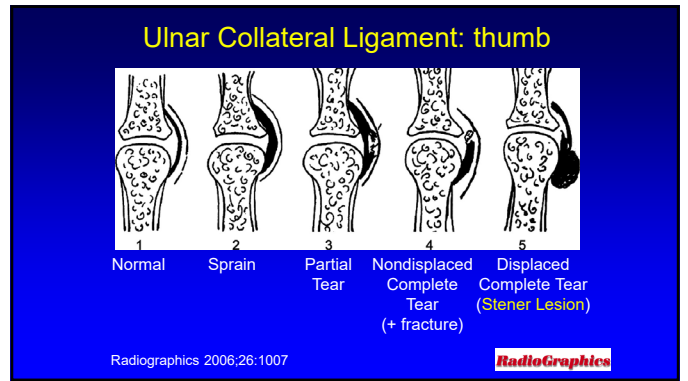
- Injury of the ulnar collateral ligament (UCL) of the thumb
 - Historically, chronic injury in Scottish gamekeepers
 - Frequently, due to acute MCP joint hyperabduction
 - **Skier's thumb**: up to 86% of thumb base injuries



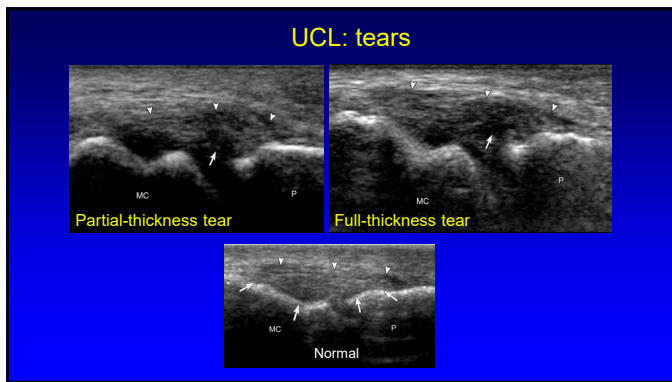
60



61



62



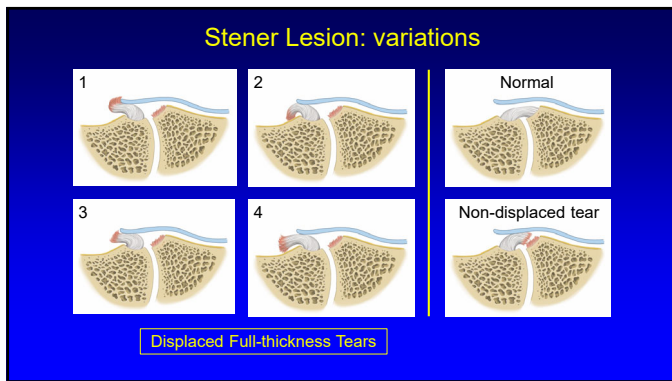
63

Stener Lesion:

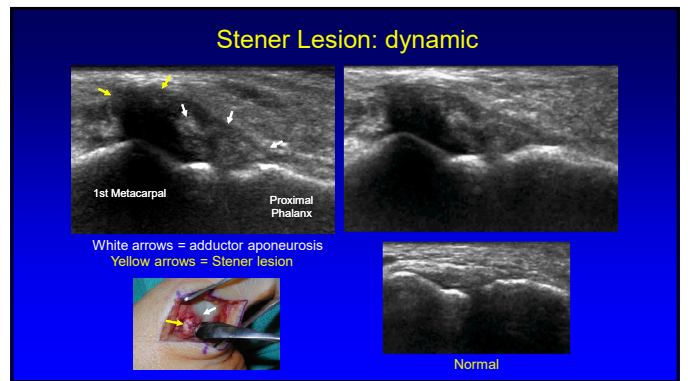
- Displaced proximal stump of torn UCL
 - Hypoechoic & round
 - Proximal to MCP joint
 - At proximal edge of adductor aponeurosis
- No tissue spanning MCP joint
- “Yo-yo on a string” sign

*Radiology 1995; 194:65

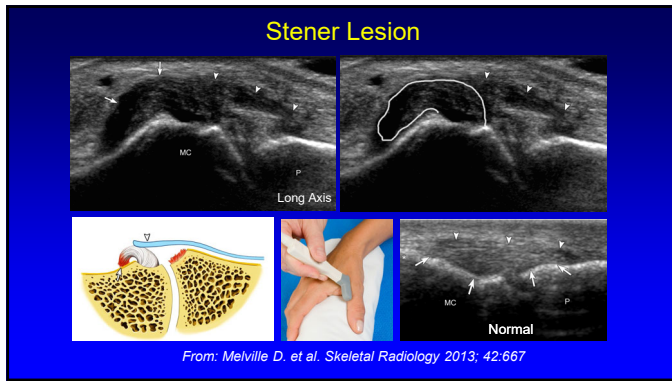
64



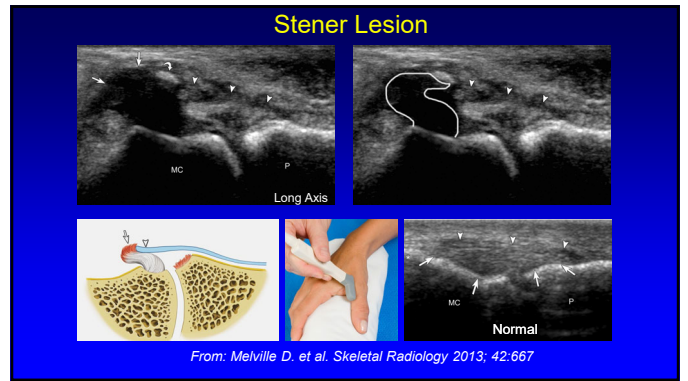65



66



67



68

- ### Pathology:
- Joint effusion and synovitis
 - Tendon abnormalities
 - Nerve entrapment
 - Ligament, cartilage, and osseous injury
 - **Cysts and masses**

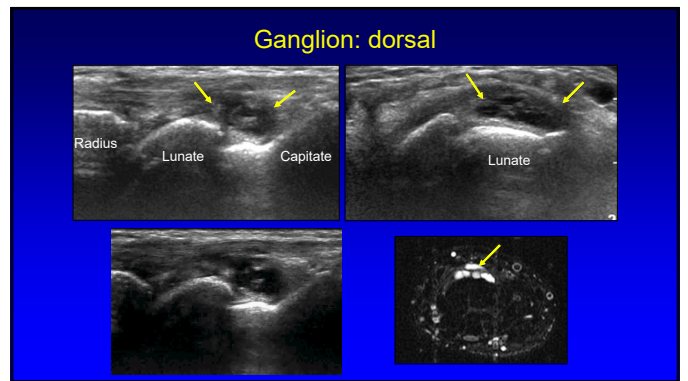
69

- ### Soft Tissue Mass: wrist ganglia
- Most wrist masses are ganglia
 - Volar (69%):
 - Radial artery & flexor carpi radialis
 - Proximal from radioscaphoid joint capsule
 - Dorsal: scapholunate ligament
 - Not compressible (unlike joint recess)

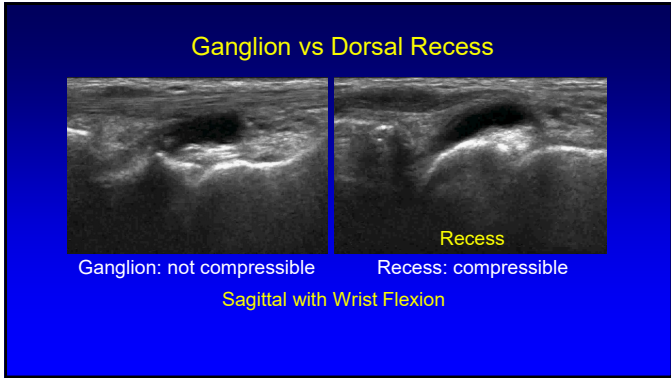
70

- ### Soft Tissue Mass: wrist ganglia
- Anechoic or hypoechoic
 - Well-defined, lobular
 - Joint or tendon sheath communication
 - <10 mm: hypoechoic without posterior acoustic enhancement
- *Wang et al. J Ultrasound Med 2007; 26:1323

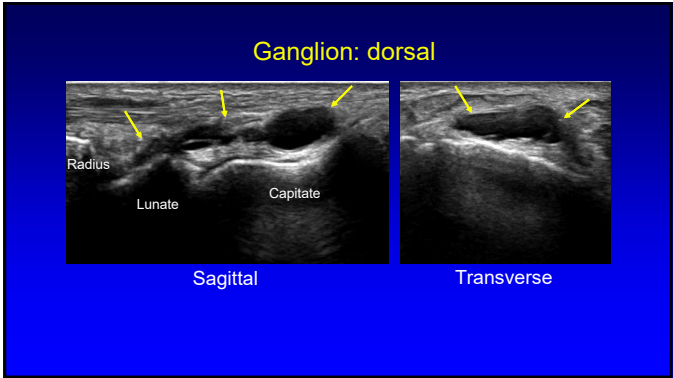
71



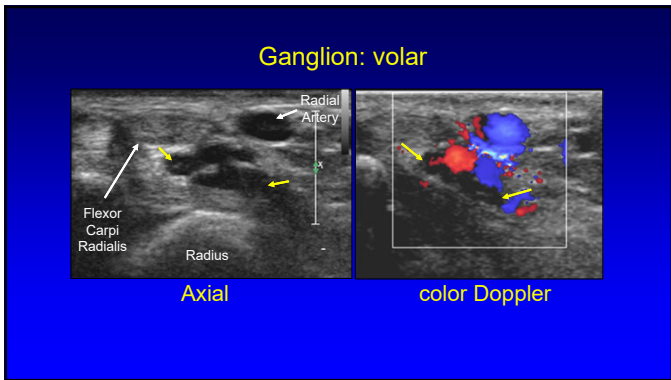
72



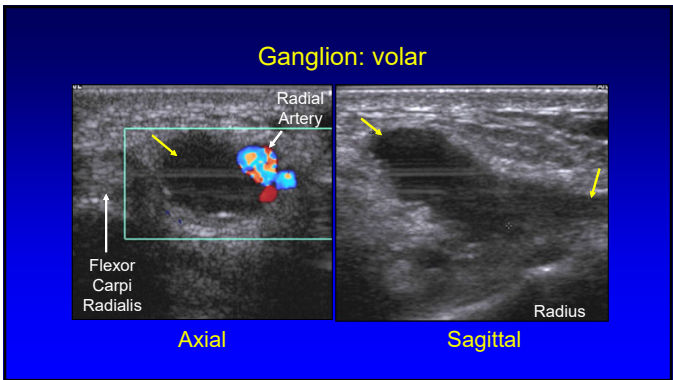
73



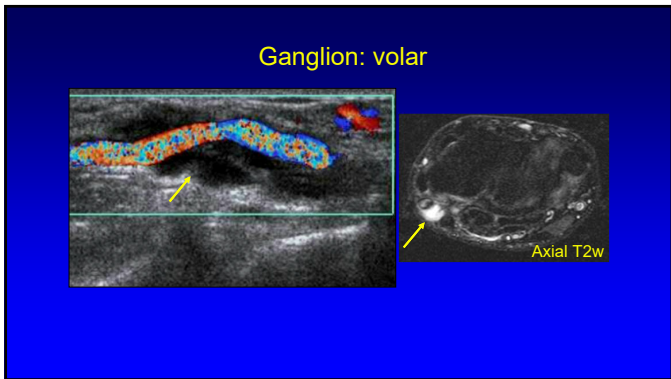
74



75



76



77

Mucous Cyst

- Arises from DIP joint
 - Osteoarthritis
 - Pedicle
- Often extends to nail bed
- Subungual mass
- Middle-age or older women
- Recur

Baek HJ et al. Radiographics 2010; 30:1621

78

Soft Tissue Foreign Bodies

- Wood and plastic: not radiopaque on radiographs
- All soft tissue foreign bodies are initially **hyperechoic**

Radiology 1998; 206:45

79

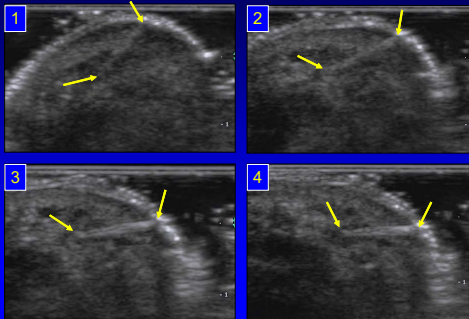
Sonography:

- All foreign bodies: initially hyperechoic
 - Organic matter: less echogenic over time
- Most echogenic if ultrasound beam perpendicular to surface of foreign body

Radiology 1998; 206:45

80

US: foreign body echogenicity



81

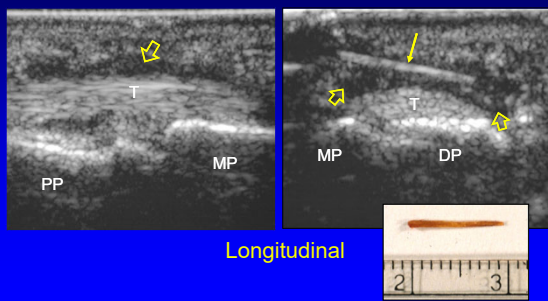
Soft Tissue Foreign Bodies

- Hypoechoic halo: foreign body response
- Smooth and flat: **reverberation**
- Irregular and small radius of curvature: **shadowing**

Radiology 1991; 181:231

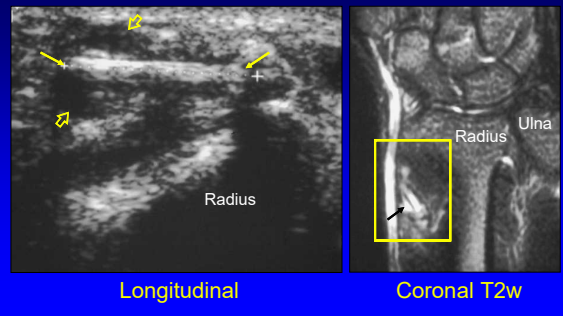
82

Wooden Foreign Body: finger

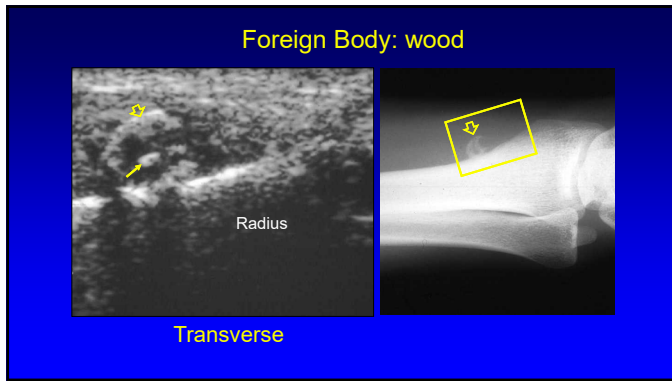


83

Foreign Body: wood



84



85

Tenosynovial Giant Cell Tumor

- Localized:
 - Giant cell tumor (GCT) tendon sheath
 - Hand, volar digits #1 - 3
 - Localized pigmented villonodular synovitis (PVNS)
- Diffuse:
 - Conventional PVNS
 - Diffuse-type GCT

Jelinek. AJR 1994; 162:919

86

Glomus Tumor

- Hamartoma:
 - Neuromyoarterial glomus body
- 75% in hand: subungual
- Pain, tenderness, temperature sensitivity
- US:
 - Hypoechoic to isoechoic mass
 - Increased flow

Drape. Radiology 1995;195:507

87

Take Home Points

- Arthritis: emphasize synovitis
- Nerve: swelling at entrapment site
- Stener:
 - Proximal to MCP joint and aponeurosis
 - Dynamic imaging
- Ganglion: multilocular
 - Volar at FCR and radial artery
 - Dorsal over SL ligament

88

Syllabus on line and other educational material:
www.jacobsonmskus.com

Twitter handle: @jjacobsn

89