

Ankle and Foot Ultrasound: Anatomy and Scanning Technique

Jon A. Jacobson, MD
FACR, FSRU, FAIM, RMSK

Musculoskeletal Radiologist
Lenox Hill Radiology, NYC

1

Disclosures

- Consultant: Bioclinica
- Contractor: POCUS PRO
- Advisory Board: Philips
- Book Royalties: Elsevier
- Not relevant to this lecture

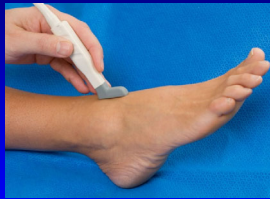*Note: all images from the textbook
Fundamentals of Musculoskeletal Ultrasound
are copyrighted by Elsevier Inc.*

See www.jacobsonmuskus.com for syllabus other educational material

2

Technique: *anterior*

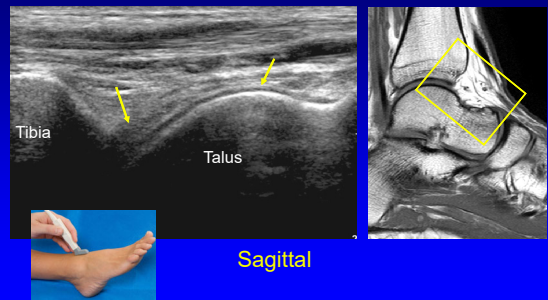
- Anterior joint recess
 - Plantar flexion
 - Hyperechoic extracapsular fat pad
 - Hypoechoic hyaline cartilage



AJR 1998; 170:1231

3

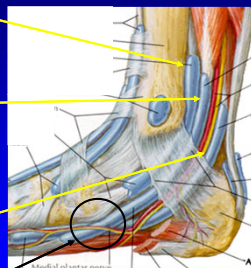
Tibiotalar Joint



4

Medial Tendons

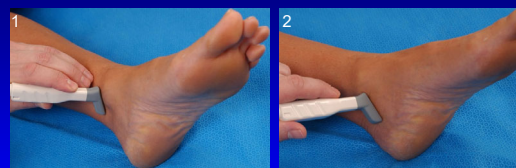
- Tibialis posterior
 - Navicular > cuneiforms
 - Metatarsals 2 – 4
- Flexor digitorum longus
 - Distal phalanges #2 – 5
- Tibial nerve, artery, veins
- Flexor hallucis longus
 - Base of distal 1st phalanx
 - *Knot of Henry: FHL & FDL



From: Netter's Atlas of Human Anatomy

5

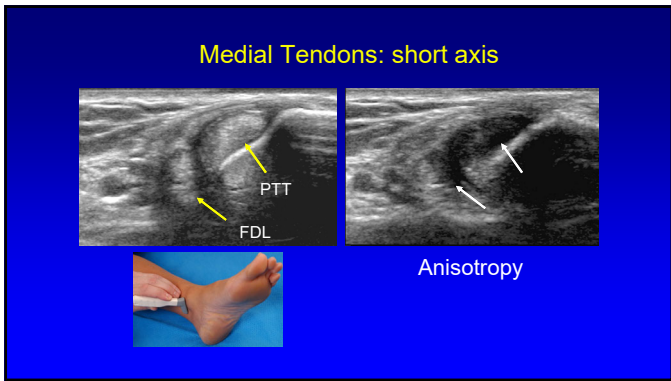
Medial Tendons: short axis



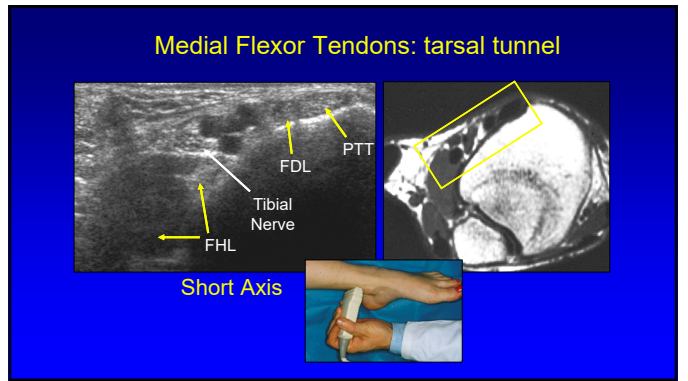
Transverse

Coronal

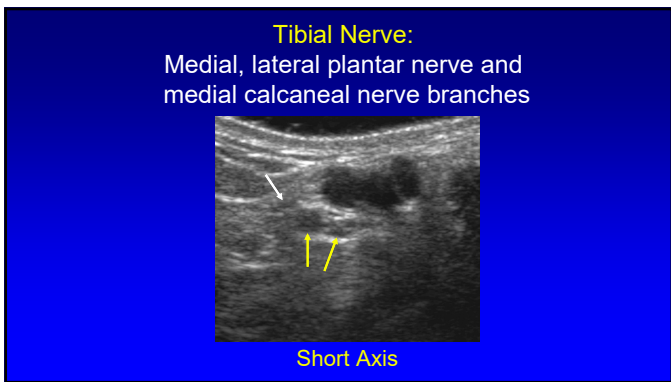
6



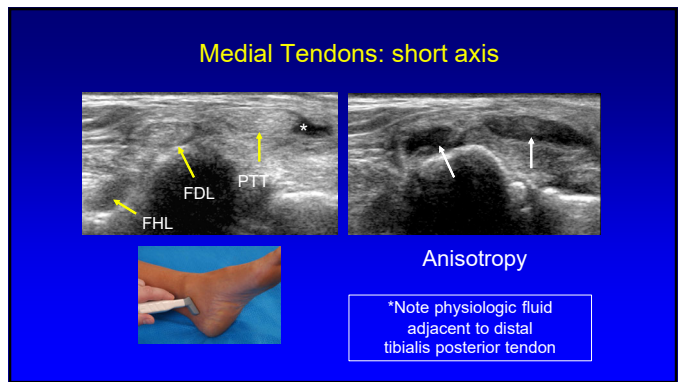
7



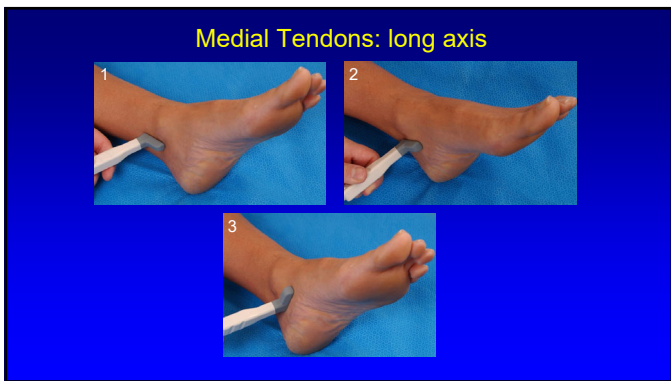
8



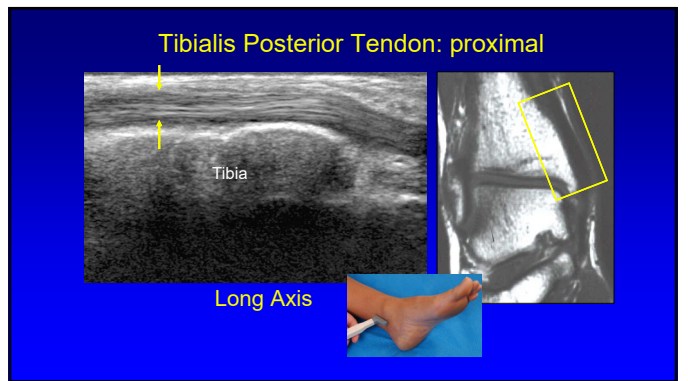
9



10



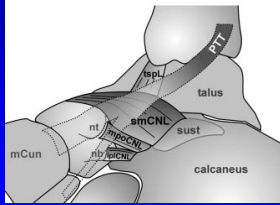
11



12

Spring Ligament Complex

- Calcaneonavicular ligament
 - Superomedial
 - Perpendicular to distal PTT
 - Mediolateral oblique
 - Inferoplantar longitudinal

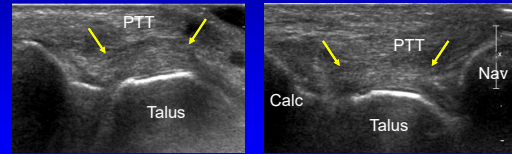


From: Radiology 2005; 237:242

19

Spring Ligament Complex:

- Superomedial component
- Normal: hyperechoic, 2.8 – 3.4 mm thick



Harish, Skeletal Radiol 2007; 36:221

20

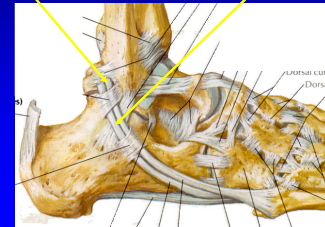
Technique: *lateral*

- Tendons:
 - Peroneus longus
 - Peroneus brevis:
 - May be oval or crescent shaped, against bone
 - Dynamic evaluation: tendon subluxation
 - Dorsiflexion and eversion

21

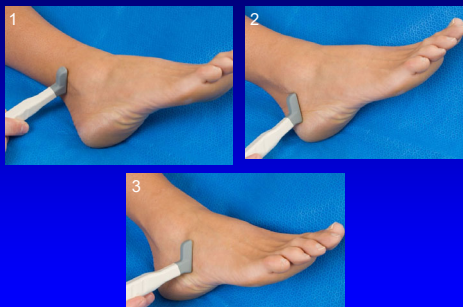
Lateral Tendons

- Peroneus brevis:
 - Oval or crescent shaped
 - Inserts of 5th metatarsal
- Peroneus longus
 - Plantar 1st MT base
 - Medial cuneiform



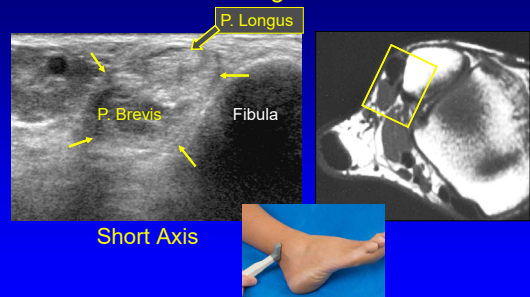
22

Peroneal Tendons: short axis

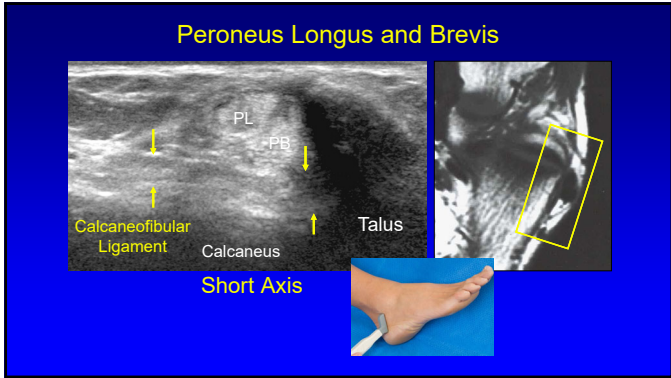


23

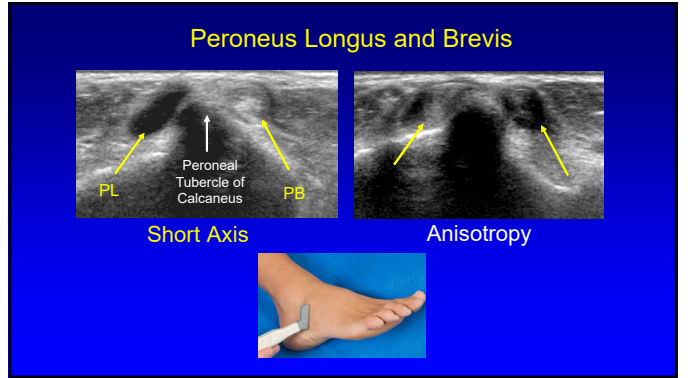
Peroneus Longus and Brevis



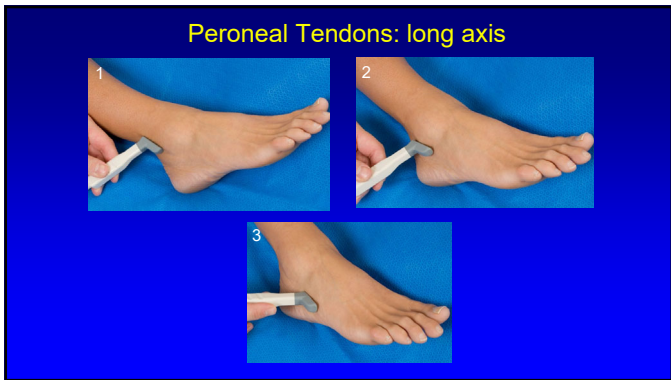
24



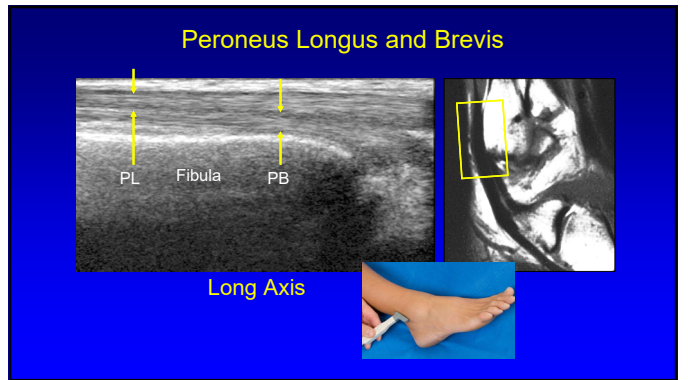
25



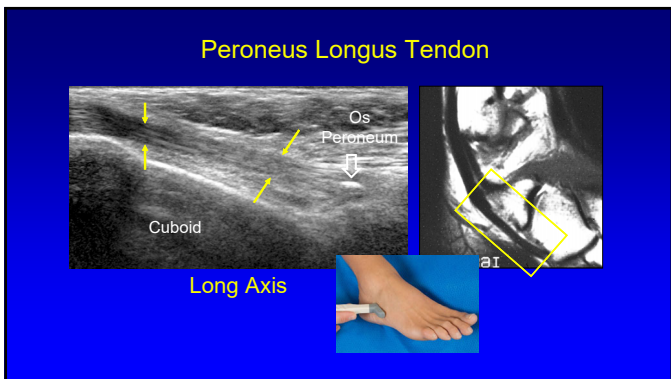
26



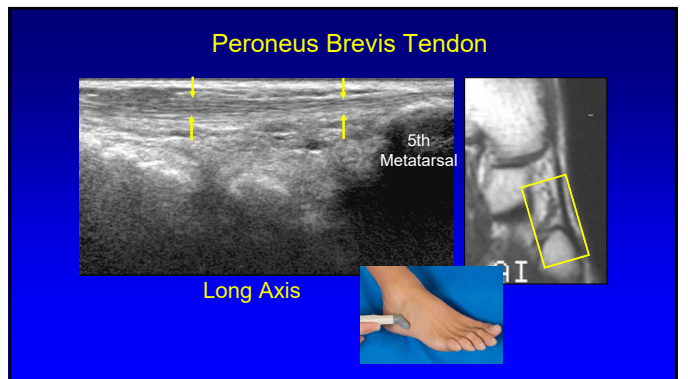
27



28



29



30

Technique: lateral

- Anterior talofibular
- Calcaneofibular
- Posterior talofibular
- Anterior tibiofibular
- Posterior tibiofibular

From: Netter's Atlas of Human Anatomy

31

Anterior Talofibular Ligament

Fibula
Talus
Long Axis

32

Anterior Talofibular Ligament

Anisotropy
Long Axis

33

Calcaneofibular Ligament

Fibula
Talus
Calcaneus
PB
PL
Long Axis

34

Anterior Inferior Tibiofibular Ligament

Fib
Tib
Long Axis

35

Inferior Tibiofibular Ligament

- Several bands
- Accessory inferior band (Bassett ligament)
 - Seen in 80 – 90%: more horizontal
 - Potential site of impingement

Fib
Tib

Radiology 2010; 254:827

36

Technique: posterior

- Tendons / Muscles:
 - Achilles
 - Flexor hallucis longus

37

Achilles Tendon: proximal

Flexor Hallucis Longus
Tibia
Tibia Talus

Long Axis

38

Achilles Tendon: distal

Calcaneus
Talus
Calcaneus

Long Axis

39

Achilles Tendon

Plantaris
Talus
Calcaneus

Short Axis

40

Plantar Fascia or Aponeurosis:

- 3 components:
 - Medial cord
 - Lateral cord
 - Central cord
 - Most important
 - Fibers envelop flexor digitorum brevis

DB
PAM
PAC
PAL
C

RadioGraphics 2000; 20:181

41

Plantar Fascia

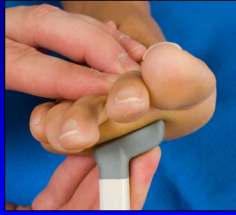Calcaneus
Calcaneus

Long Axis

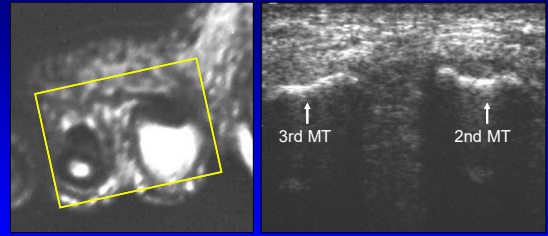
42

Technique: *other*

- Interdigital space
 - Normal digital nerve difficult to visualize
 - Morton's neuroma



Interdigital Space



Short Axis to Metatarsals

43

44

Thank you!

Syllabus on line and other educational material:
www.jacobsonmskus.com

Twitter handle: @jjacobsn

45