

# Elbow Ultrasound Anatomy and Scanning Protocol

Jon A. Jacobson, MD FACR  
FSRU, FAIUM, RMSK

Professor of Radiology  
Lenox Hill Radiology, NYC  
University of California, San Diego

1

## Disclosures

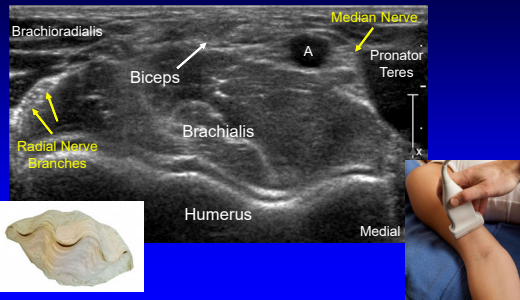
- Consultant: Bioclinica
- Advisor: Philips
- Book Royalties: Elsevier
- Not relevant to this lecture

*Note: all images from the textbook  
Fundamentals of Musculoskeletal Ultrasound are  
copyrighted by Elsevier Inc.*

See [www.jacobsonmskus.com](http://www.jacobsonmskus.com) for syllabus other educational material

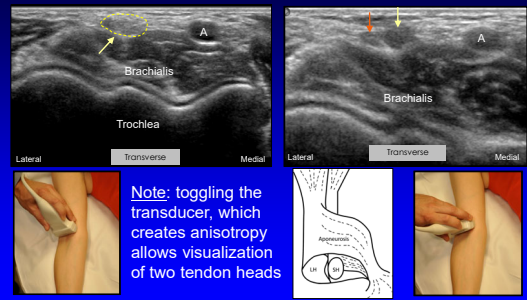
2

## Anterior Elbow: transverse



3

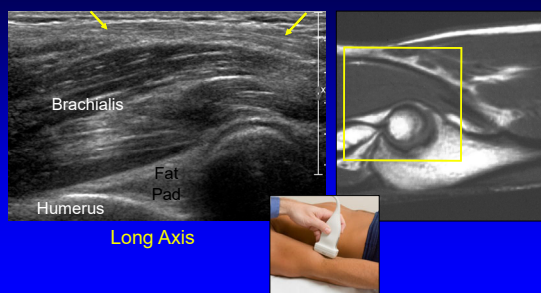
## Biceps Brachii: terminal bifurcation



Courtesy of M. Chiavaras, Hamilton, Ontario

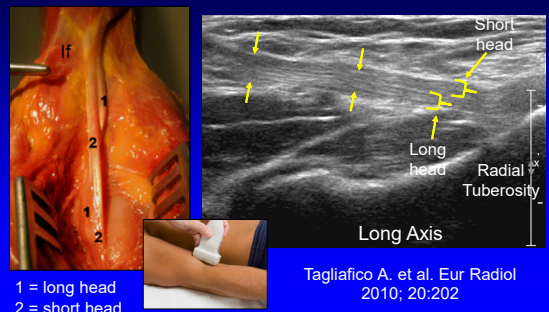
4

## Biceps, Brachialis, and Anterior Recess



5

## Biceps Brachii Tendon: distal



1 = long head  
2 = short head

Tagliafico A. et al. Eur Radiol  
2010; 20:202

6

### Biceps Tendon

- Medial approach
- "Pronator window"
- Transducer:
  - Distal aspect over medial epicondyle
  - Parallel to humerus
  - Slide transducer anterior

Smith J. et al. J Ultrasound Med 2010; 29:861

7

### Biceps Brachii Tendon: lateral approach

Long Axis: dynamic imaging

Kalume Brigido M. Eur Radiol 2009 ; 19:1817

8

### Biceps Tendon

- Flexion, pronation view
- Transverse: between radius and ulna
- Radial tuberosity rotated into view
- Limited diagnostic value
- Ideal biceps tendon injection

9

### UCL and Common Flexor Tendon

Coronal

10

### Technique: cubital tunnel

11

### Technique: ulnar nerve subluxation

Transverse

12

### Technique: lateral

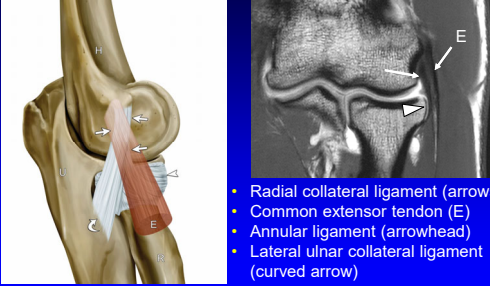
*elbow partially flexed*

- Common extensor tendon
- Radial collateral ligament
- Radial head & annular recess
- Capitellum



13

### Lateral Collateral Ligament Complex



- Radial collateral ligament (arrows)
- Common extensor tendon (E)
- Annular ligament (arrowhead)
- Lateral ulnar collateral ligament (curved arrow)

Jacobson J. et al. J Ultrasound Medicine 2013; 33:1041

14

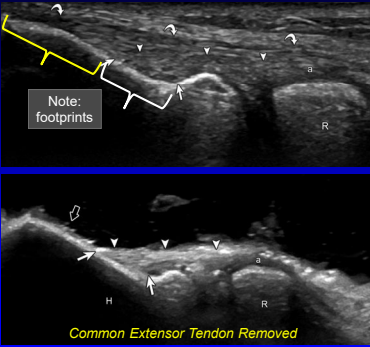
### Lateral Collateral Ligament Complex

- Common extensor tendon (curved arrows)
- Radial collateral ligament (arrowheads)
- Annular ligament (a)

Note: footprints

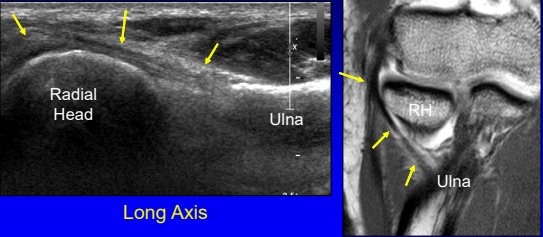
Common Extensor Tendon Removed

Jacobson J. et al. J Ultrasound Medicine 2013; 33:1041



15

### Lateral Ulnar Collateral Ligament (LUCL)

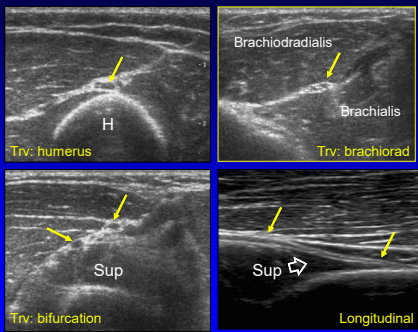


Long Axis

\*LUCL attaches at crista supinator of ulna

16

### Radial Nerve



Trv: humerus

Trv: brachiorad

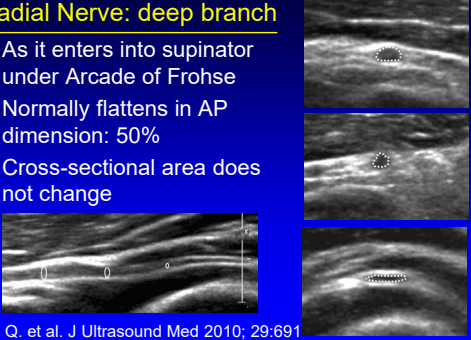
Trv: bifurcation

Longitudinal

17

### Radial Nerve: deep branch

- As it enters into supinator under Arcade of Frohse
- Normally flattens in AP dimension: 50%
- Cross-sectional area does not change




Dong Q. et al. J Ultrasound Med 2010; 29:691

18

**Technique: posterior**

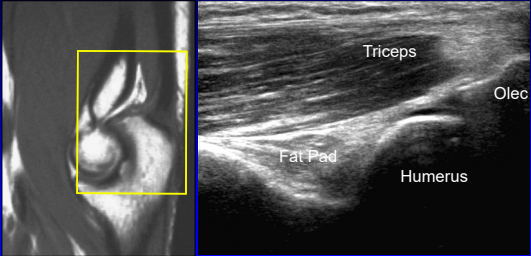
*elbow flexed*

- Olecranon recess
- Triceps brachii
- Olecranon bursa



19

**Olecranon Recess and Triceps**

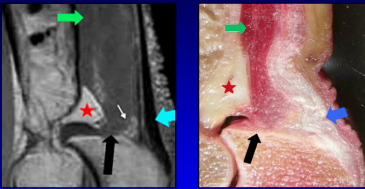


Triceps  
Fat Pad  
Humerus  
Olec

Sagittal

20

**Anatomy of the Distal Triceps Brachii**

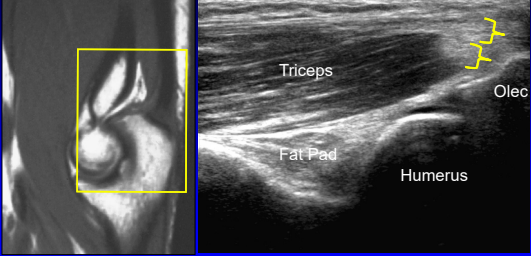


- Superficial (blue arrow): long + lateral heads
- Deep (black arrow): medial head
  - Primarily muscular insertion

\*From Resnick, Skeletal Radiol 2009; 38:171

21

**Olecranon Recess and Triceps**

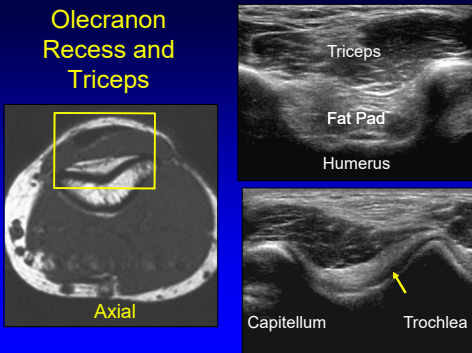


Triceps  
Fat Pad  
Humerus  
Olec

Sagittal

22

**Olecranon Recess and Triceps**



Triceps  
Fat Pad  
Humerus

Capitellum  
Trochlea

Axial


23

**Take-home Points:**

- Follow a scanning protocol
- Do not focus exam too much
- Use bone landmarks:
  - Orientation
  - Where tendon abnormalities occur
- Biceps scanning technique

24

Thank you!



Syllabus on line and other educational material:  
[www.jacobsonmskus.com](http://www.jacobsonmskus.com)

