

Wrist Ultrasound Anatomy and Scanning Protocol

Jon A. Jacobson, MD
FACR, FSRU, FAIUM, RMSK

Musculoskeletal Radiologist
Lenox Hill Radiology, NYC
University of California, San Diego



Syllabus PDF

1

Disclosures

- Consultant: Bioclinica
- Book Royalties: Elsevier
- Not relevant to this lecture

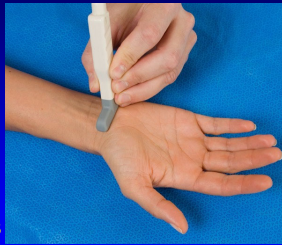*Note: all images from the textbook
Fundamentals of Musculoskeletal Ultrasound are
copyrighted by Elsevier Inc.*

See www.jacobsonmuskus.com for syllabus other educational material

2

Technique: volar

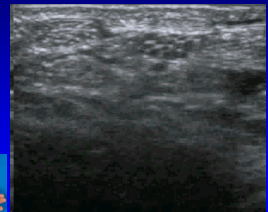
- Median nerve
- Flexor tendons
 - Flexor carpi radialis and radial artery
 - Occult ganglia
- Volar joint recesses



3

Normal Peripheral Nerve

- Ultrasound appearance:
 - Hypochoic nerve fascicles
 - Hyperechoic connective tissue
- Transverse:
 - Honeycomb appearance

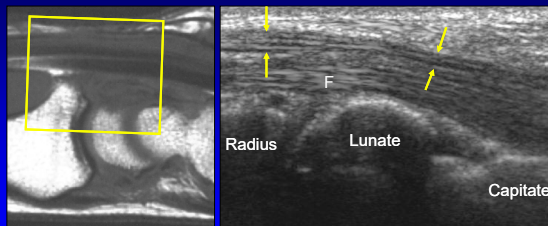


Median Nerve

Silvestri et al. Radiology 1995; 197:291

4

Volar Wrist: median nerve

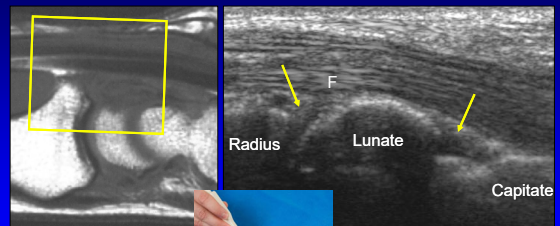


Sagittal T1w

Long Axis

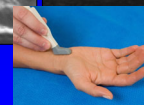5

Volar Wrist: joint recesses



Sagittal T1w

Long Axis



6

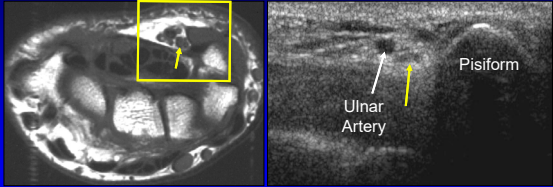
Technique: volar

- Median nerve
- Flexor tendons
- Volar joint recesses
- **Guyon's canal**
 - Ulnar artery and nerve



7

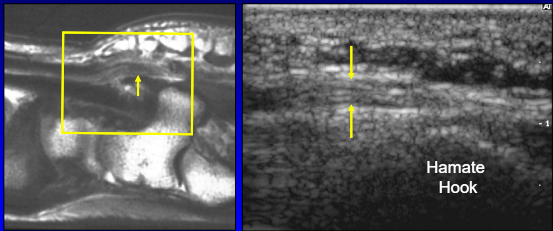
Volar Wrist: Guyon's canal



Axial T1w Short Axis

8

Volar Wrist: ulnar nerve



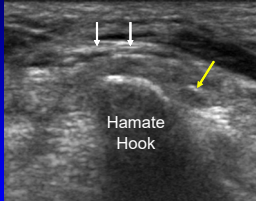
Sagittal T1w Long Axis

Hamate Hook

9

Ulnar Nerve

- At hook of hamate
- Sensory branch:
 - Superficial to hook
 - One or two trunks
 - White arrows
- Motor branch:
 - Ulnar side of hook
 - Yellow arrow



Hamate Hook

Silvestri et al. Radiology 1995; 197:291

10

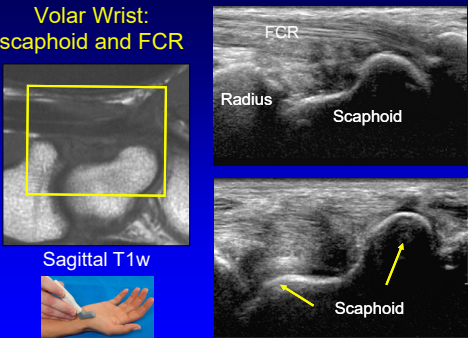
Technique: volar

- Median nerve
- Flexor tendons
- Volar joint recess
- Guyon's canal
- **Scaphoid and flexor carpi radialis**



11

Volar Wrist: scaphoid and FCR



Sagittal T1w

FCR
Radius
Scaphoid

Scaphoid

12

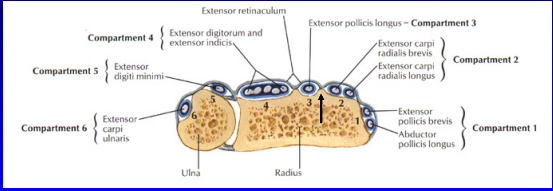
Technique: dorsal

- Extensor tendons



13

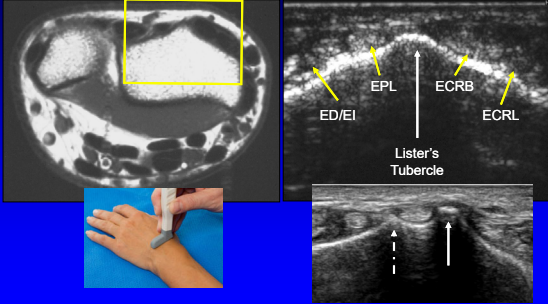
Dorsal Wrist



From: Netter's Atlas of Human Anatomy

14

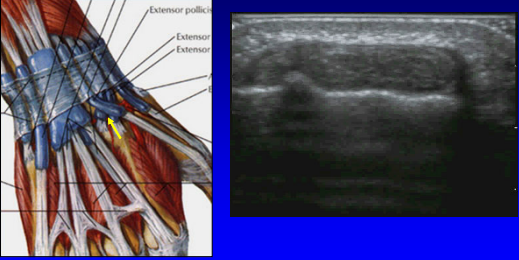
Dorsal Wrist: extensor tendons



Labels in ultrasound: EPL, ECRB, ED/EI, ECRL, Lister's Tubercle

15

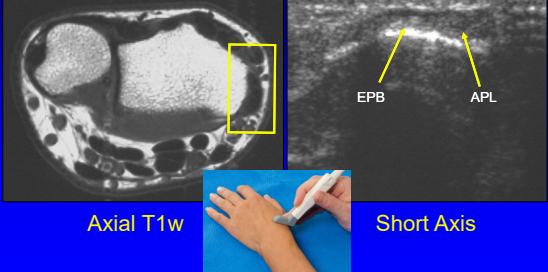
Dorsal Wrist: extensor pollicis longus



From: Netter's Atlas of Human Anatomy

16

Dorsal Wrist: 1st compartment



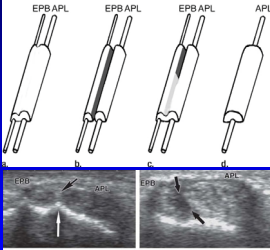
Labels: EPB, APL

Axial T1w, Short Axis

17

Subcompartmentalization

- First extensor compartment
- Complete or incomplete
- 73% incidence²
- Septum:
 - US: 95% accurate¹
 - Hyperechoic
 - Anisotropy
- Indirect sign:
 - Osseous ridge¹

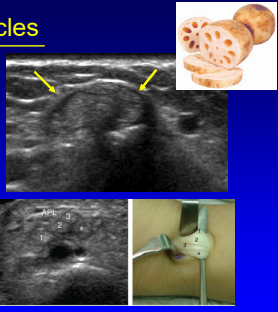


¹Rousset et al. Radiology 2010; 257:427
²Choi et al. Radiology 2011; 260:480

18

Multiple Tendon Fascicles

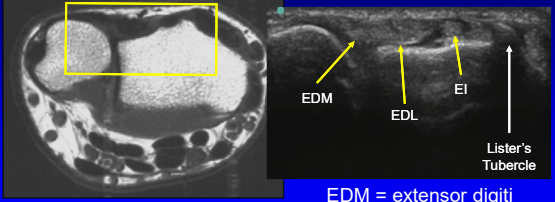
- Abductor pollicis longus
 - Incidence: 80%²
 - Up to 4 fascicles
 - US: 80% accuracy¹
- Extensor pollicis brevis
 - Incidence: 7%²
 - Up to 2 fascicles
 - US: 97% accuracy¹
- "Lotus Root Sign"²
 - Seen best distal to radius



¹Roussel et al. Radiology 2010; 257:427
²Choi et al. Radiology 2011; 260:480

19

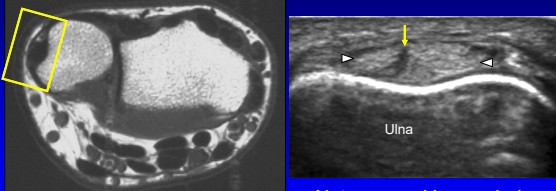
Dorsal Wrist: 4th and 5th compartments



EDM = extensor digiti minimi
Not Electronic Dance Music

20

Dorsal Wrist: 6th compartment



Note: normal hypochoic cleft

21

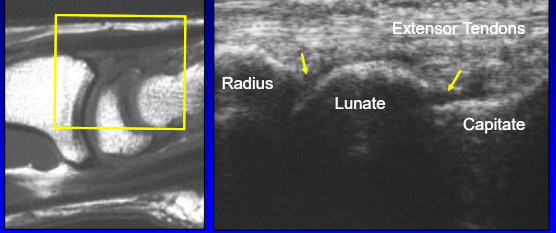
Technique: dorsal

- Extensor tendons
- Dorsal joint recesses



22

Dorsal Wrist: joint recesses




Sagittal T1w Longitudinal

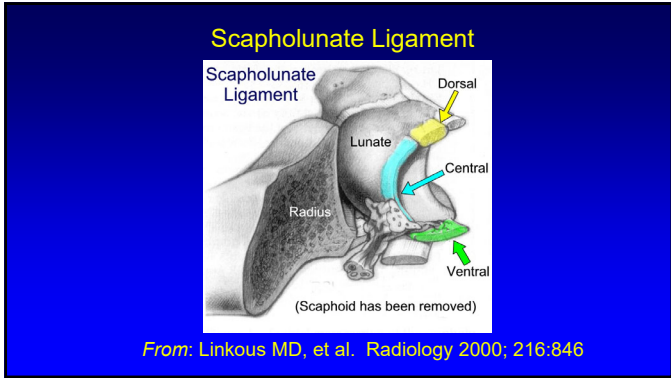
23

Technique: dorsal

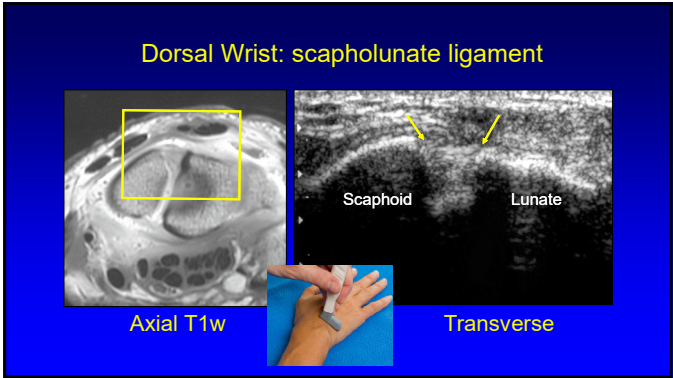
- Extensor tendons
- Dorsal joint recesses
- Scapholunate ligament



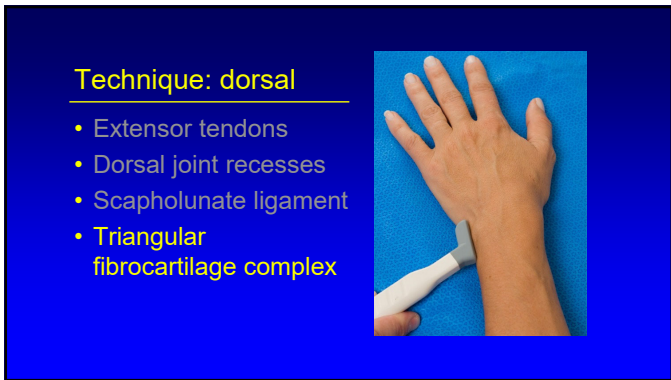
24



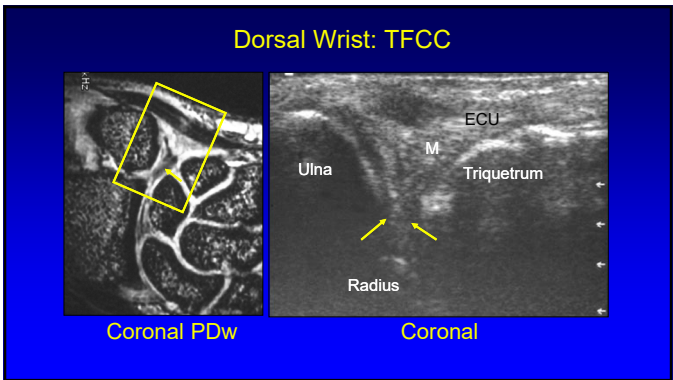
25



26






27




28

Thank you!

Syllabus on line and other educational material:
www.jacobsonmskus.com

Twitter handle: @jjacobsn



29