

# Wrist and Hand Ultrasound: Anatomy and Scanning Technique

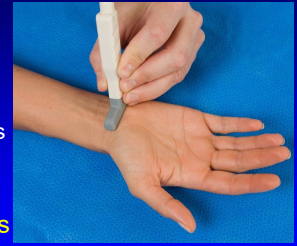Jon A. Jacobson, MD  
FACR, FSRU, FAIM, RMSK

Musculoskeletal Radiologist  
Lenox Hill Radiology, NYC

1

## Technique: volar

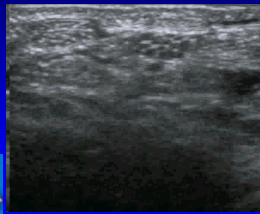
- Median nerve
- Flexor tendons
  - Flexor carpi radialis and radial artery
  - Occult ganglia
- Volar joint recesses



2

## Normal Peripheral Nerve

- Ultrasound appearance:
  - Hypochoic nerve fascicles
  - Hyperechoic connective tissue
- Transverse:
  - Honeycomb appearance

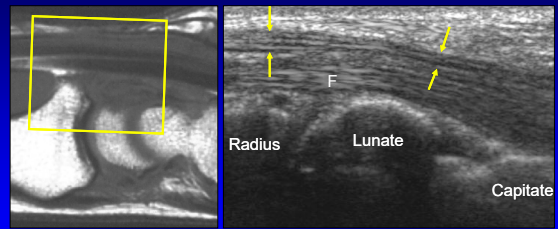


Median Nerve

Silvestri et al. Radiology 1995; 197:291

3

## Volar Wrist: median nerve

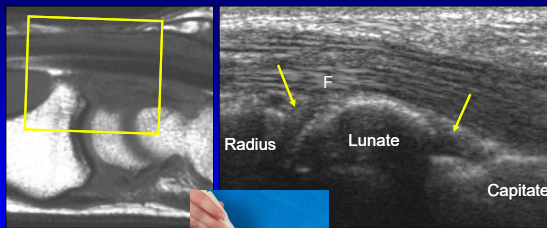


Sagittal T1w

Long Axis

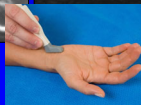4

## Volar Wrist: joint recesses



Sagittal T1w

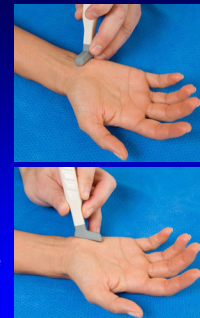Long Axis



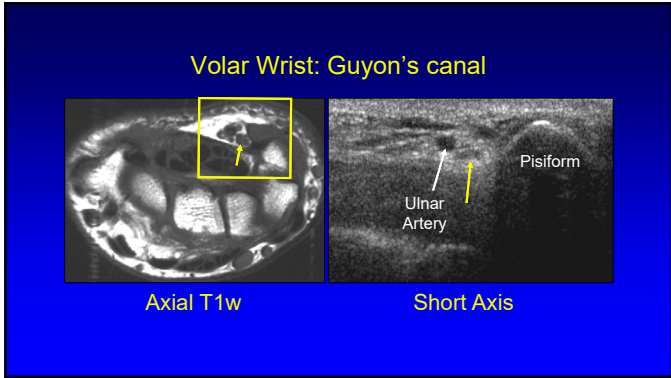
5

## Technique: volar

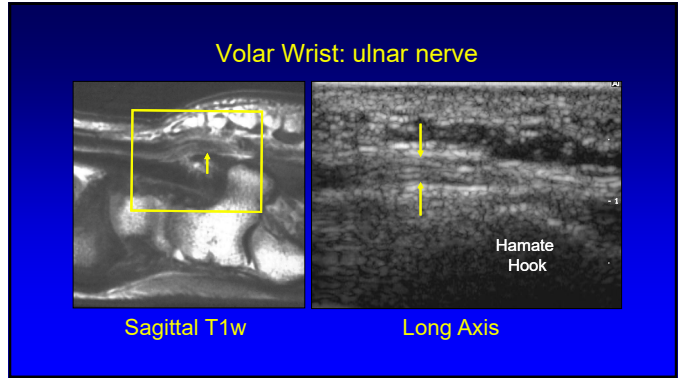
- Median nerve
- Flexor tendons
- Volar joint recesses
- Guyon's canal
  - Ulnar artery and nerve



6



7



8

**Ulnar Nerve**

- At hook of hamate
- Sensory branch:
  - Superficial to hook
  - One or two trunks
  - White arrows
- Motor branch:
  - Ulnar side of hook
  - Yellow arrow

Hamate Hook

Silvestri et al. Radiology 1995; 197:291

9

**Technique: volar**

- Median nerve
- Flexor tendons
- Volar joint recess
- Guyon's canal
- Scaphoid and flexor carpi radialis

10

**Volar Wrist: scaphoid and FCR**

FCR  
Radius      Scaphoid

Sagittal T1w

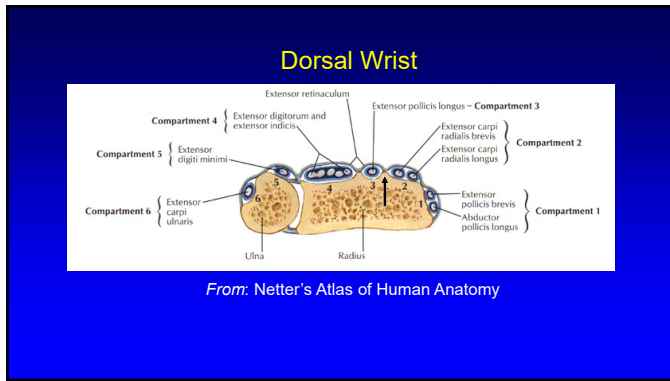
Scaphoid

11

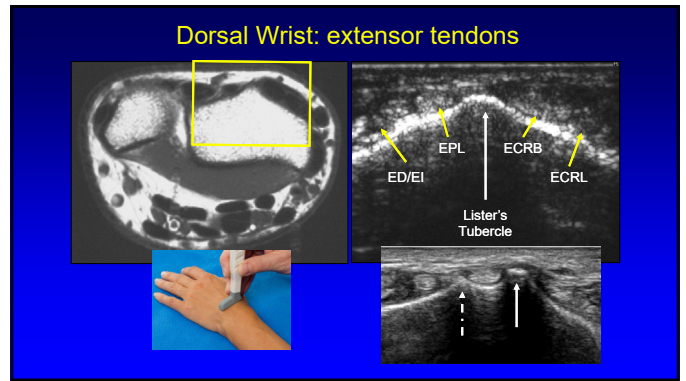
**Technique: dorsal**

- Extensor tendons

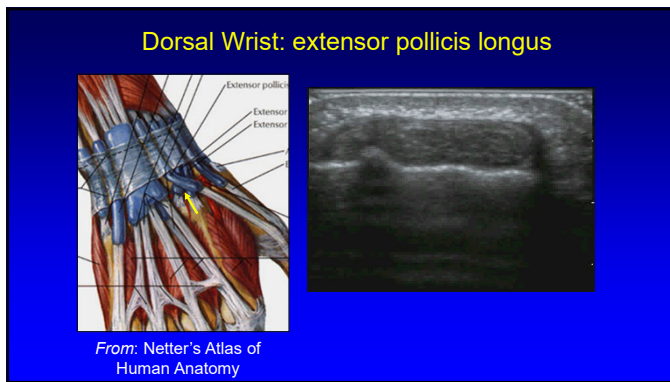
12



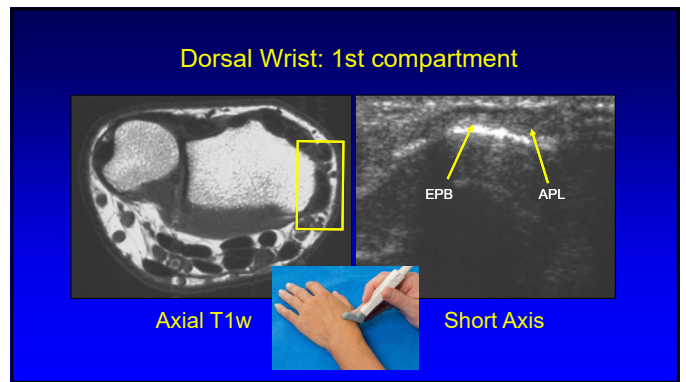
13



14



15



16

### Subcompartmentalization

- First extensor compartment
- Complete or incomplete
- 73% incidence<sup>2</sup>
- Septum:
  - US: 95% accurate<sup>1</sup>
  - Hyperechoic
  - Anisotropy
- Indirect sign:
  - Osseous ridge<sup>1</sup>

<sup>1</sup>Roussel et al. Radiology 2010; 257:427  
<sup>2</sup>Choi et al. Radiology 2011; 260:480

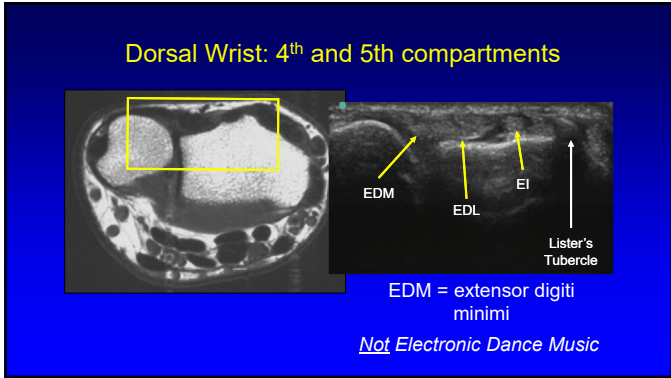
17

### Multiple Tendon Fascicles

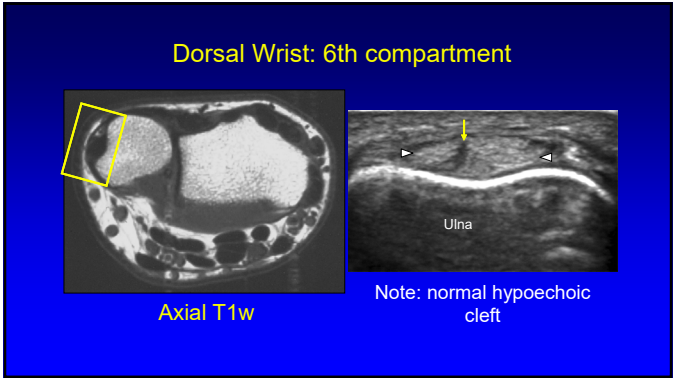
- Abductor pollicis longus
  - Incidence: 80%<sup>2</sup>
  - Up to 4 fascicles
  - US: 80% accuracy<sup>1</sup>
- Extensor pollicis brevis
  - Incidence: 7%<sup>2</sup>
  - Up to 2 fascicles
  - US: 97% accuracy<sup>1</sup>
- "Lotus Root Sign"<sup>2</sup>
  - Seen best distal to radius

<sup>1</sup>Roussel et al. Radiology 2010; 257:427  
<sup>2</sup>Choi et al. Radiology 2011; 260:480

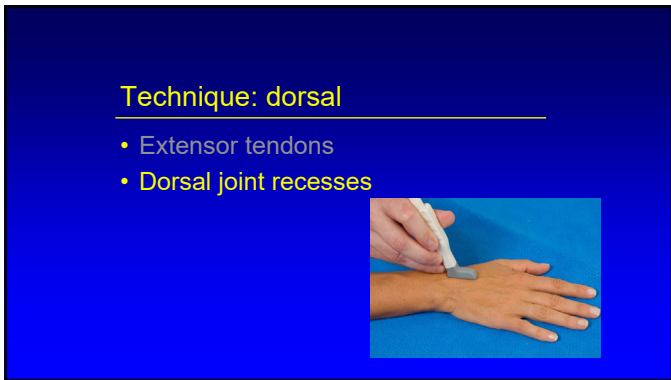18



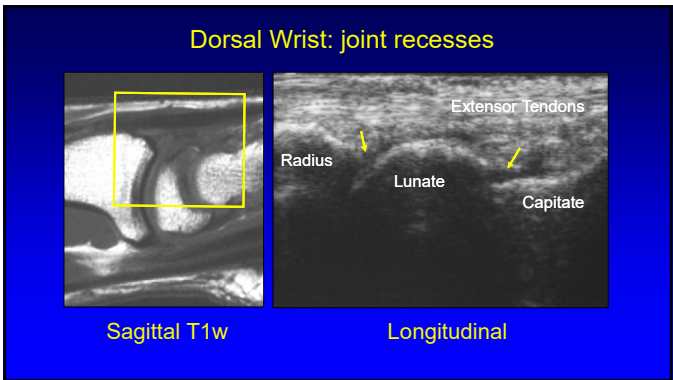
19



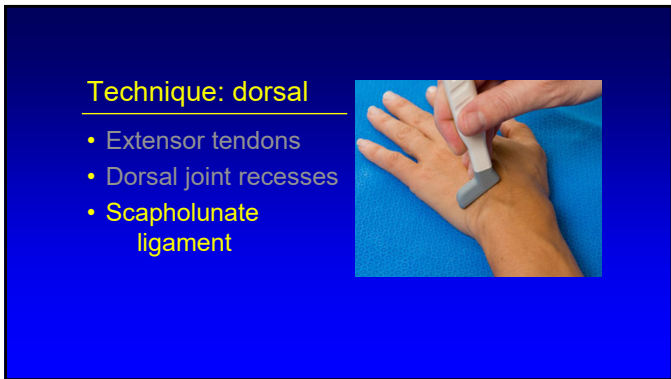
20



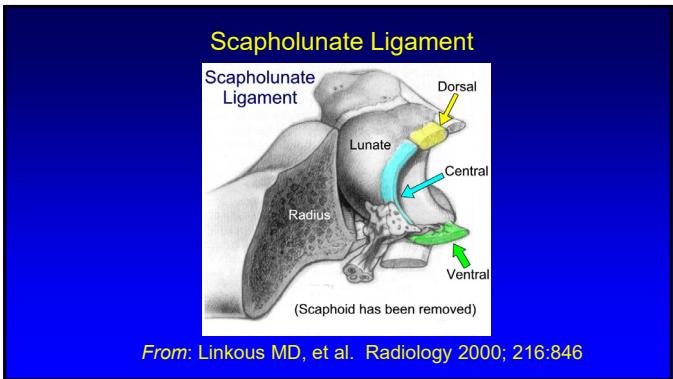
21



22

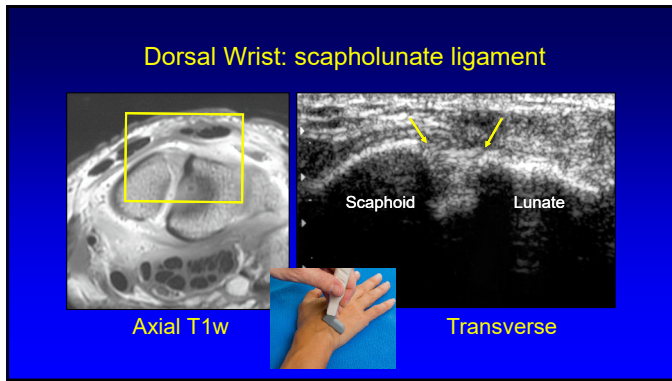


23

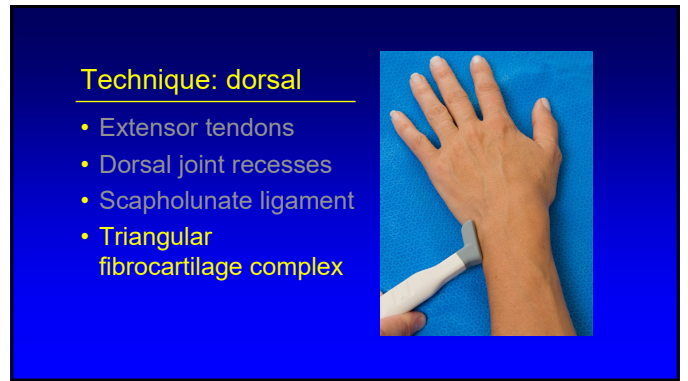


24

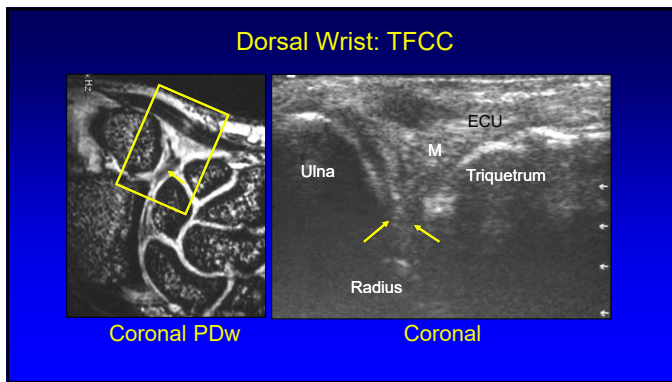




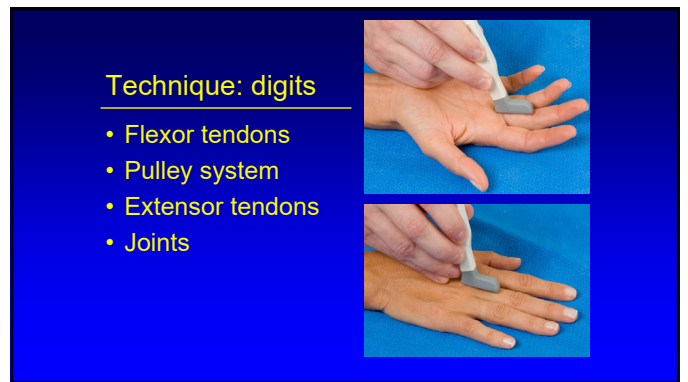25



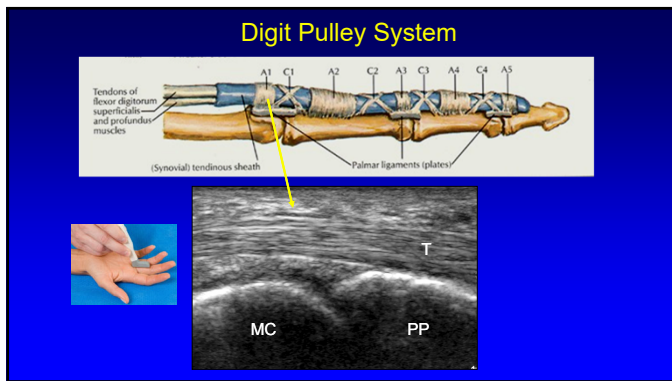
26



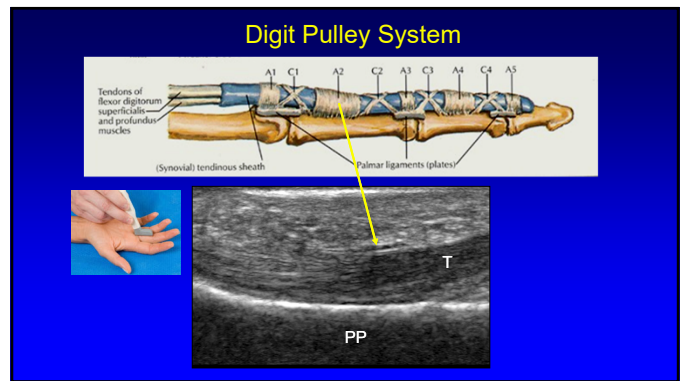
27



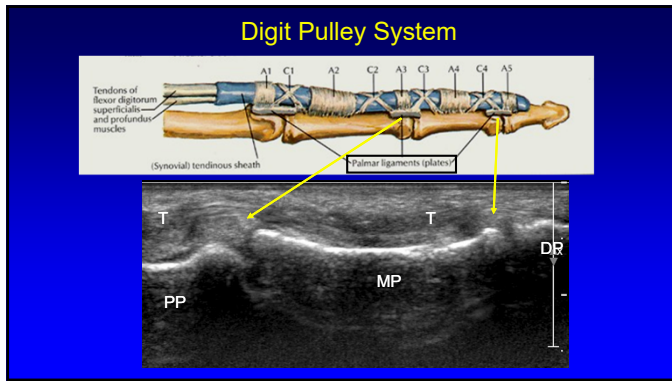
28



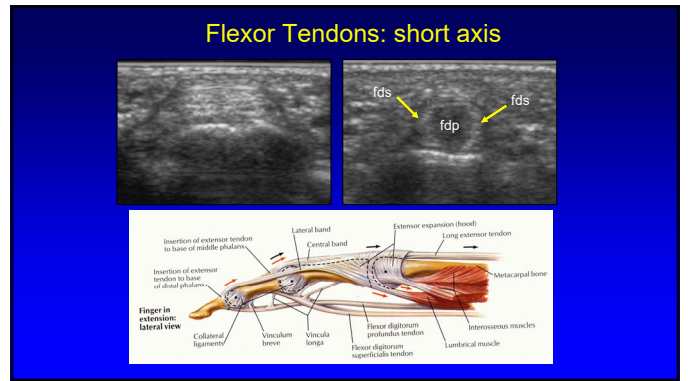
29



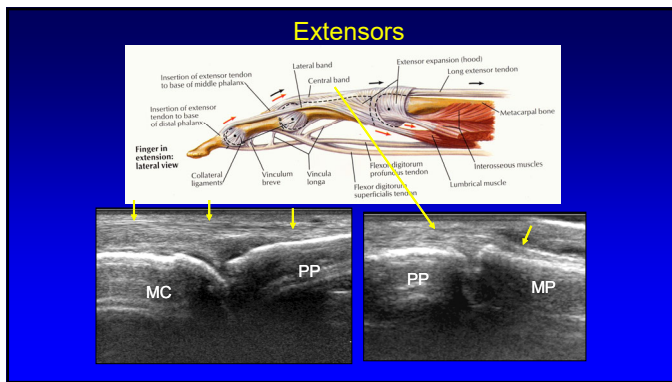
30



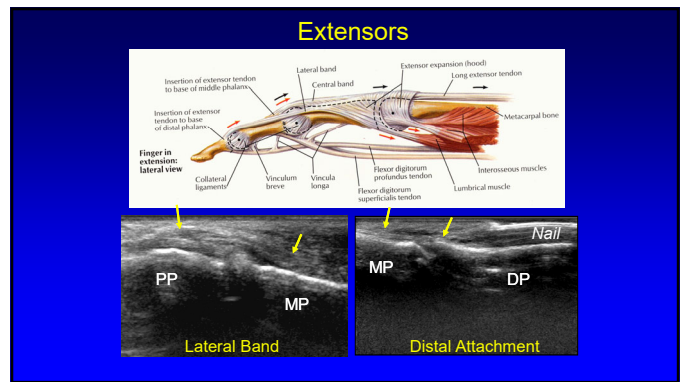
31



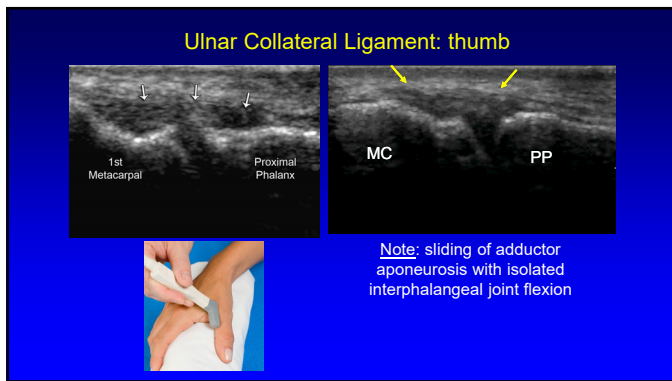
32



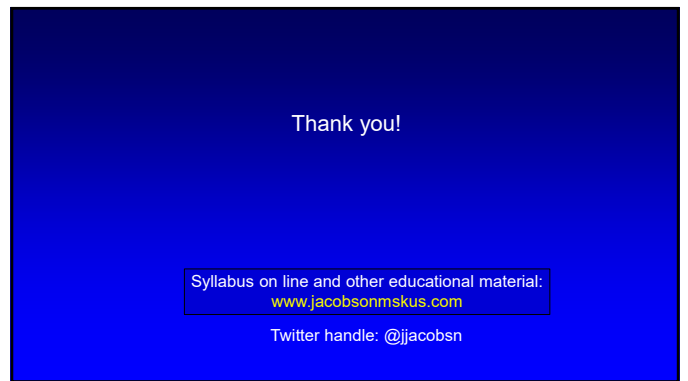
33



34



35



36