

Ultrasound of Common Wrist and Hand Pathology

Jon A. Jacobson, MD
FACR, FSRU, FAIM, RMSK

Musculoskeletal Radiologist
Lenox Hill Radiology, NYC

1

Disclosures

- Book Royalties: Elsevier
- Consultant: Bioclinica
- Advisory Board: POCUSPRO
- Not relevant to this talk

Syllabus on line and other educational material:
www.jacobsonmskus.com

2

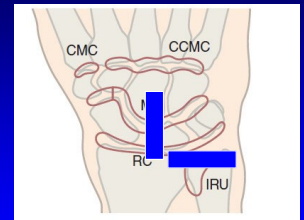
Outline

- Joint effusion / synovitis
- De Quervain tenosynovitis
- Carpal tunnel syndrome
- Gamekeeper's thumb
- Pulley abnormalities
- Ganglion

3

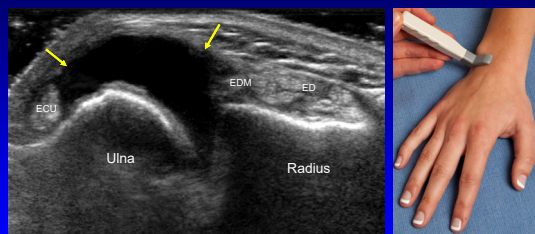
Joint Assessment: dorsal

- Wrist:
 - Radiocarpal joint (RC)
 - Midcarpal joint (MC)
 - Distal or inferior radioulnar joint (IRU)
- Hand:
 - MCP and PIP joints
 - 1st CMC (if symptomatic)



4

Joint Effusion: distal radioulnar joint



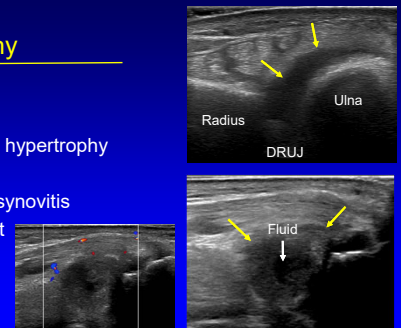
Transverse

5

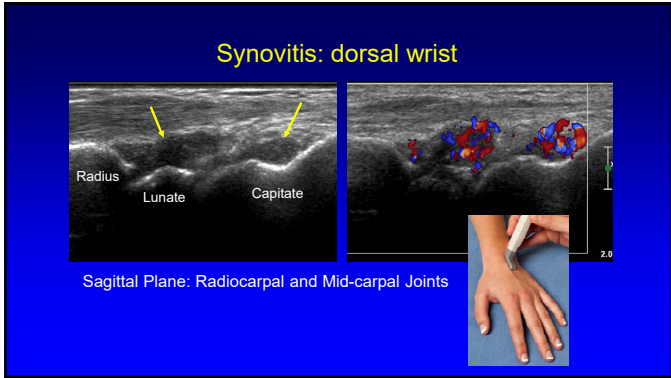
Joint Effusion vs Synovial Hypertrophy

- Anechoic: fluid
 - Hypoechoic:
 - Effusion vs. synovial hypertrophy
 - Compressible: fluid
 - Internal hyperemia: synovitis
- *flow may be absent

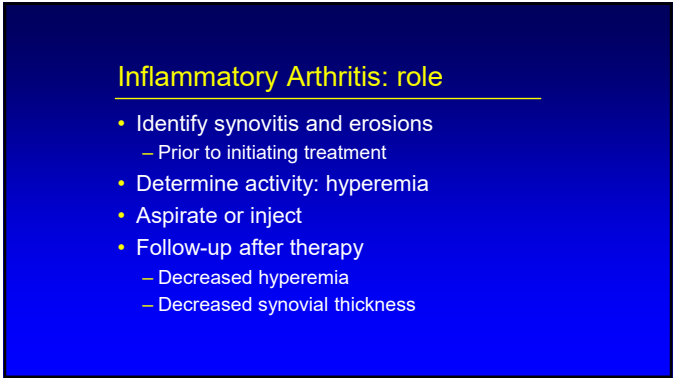
AJR 2000; 174: 1353



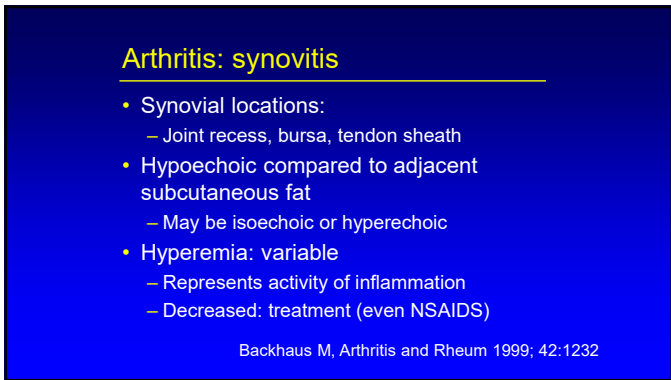
6



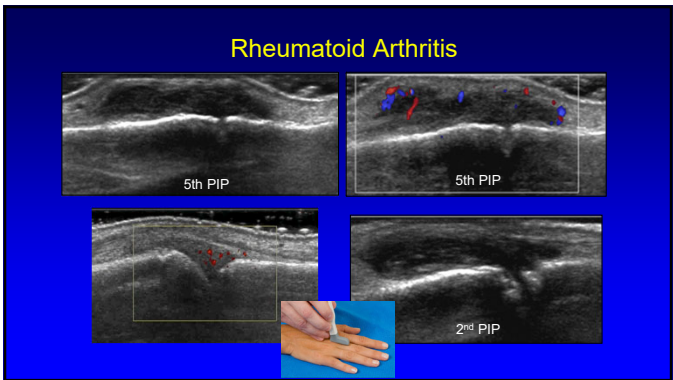
7



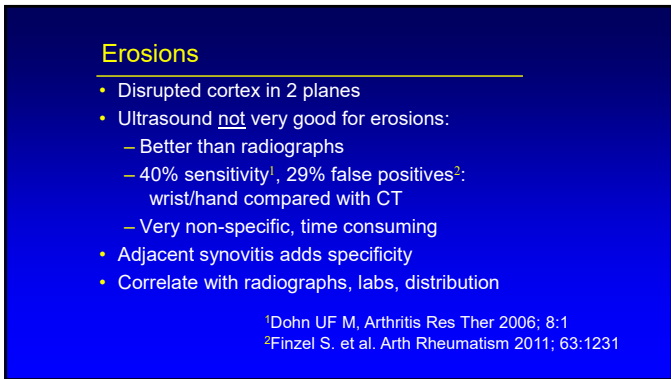
8



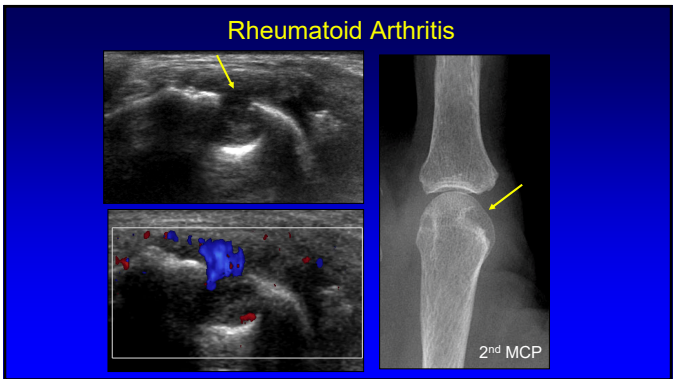
9



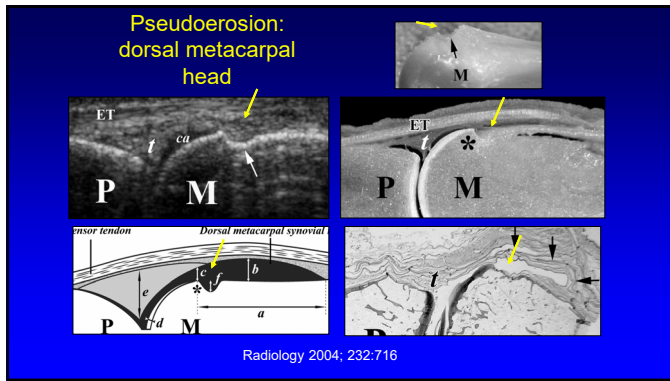
10



11



12



13

Pitfall Alert! Pseudoerosions Are Everywhere!

- 200 hands/wrists
- Pseudoerosions: 100%
- Metacarpal heads: all
 - 2nd: 92%
 - 3rd: 86%
- Carpal bones:
 - Lunate: 82%
 - Triquetrum: 84%
 - Distal ulna: 22%

**Unpublished Data*

**Note lack of adjacent synovitis*

14

Osteoarthritis: ultrasound

- Osteophytes
- Joint effusion
- Minimal synovial hypertrophy
- Variable hyperemia
- Possible intra-articular bodies

First CMC Joint: Thumb

Sagittal Plane: dorsal
 Note: osteophytes (arrow) and intra-articular body (open arrow)

Keen HI et al. Radiol Clin N Am 2009; 47:581

15

Inflammatory Arthritis: screening

- Hand:
 - MCP (dorsal): especially 2nd
 - PIP (dorsal, volar)
- Wrist:
 - Radiocarpal, midcarpal, distal radioulnar (dorsal)
- Foot:
 - MTP (dorsal): 5th most common

16

Outline:

- Joint effusion / synovitis
- **De Quervain tenosynovitis**
- Carpal tunnel syndrome
- Gamekeeper's thumb
- Pulley abnormalities
- Ganglion

17

de Quervain Tenosynovitis

- Stenosing tenosynovitis
 - Overuse, primary care givers
- 1st dorsal wrist compartment:
 - Extensor pollicis brevis + abductor pollicis longus
- Ultrasound findings:
 - Thick synovial sheath
 - Tendinosis
 - Cortical irregularity, hyperemia

J Ultrasound Med 1997; 16:685

18


Outline

- Joint effusion / synovitis
- De Quervain tenosynovitis
- **Carpal tunnel syndrome**
- Gamekeeper's thumb
- Pulley abnormalities
- Ganglion

19

Carpal Tunnel Syndrome:

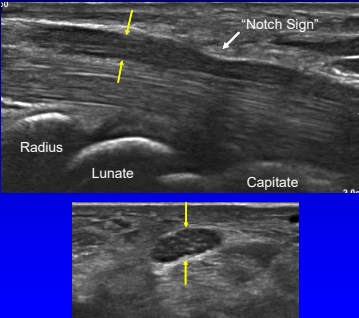
- Proximal median nerve swelling
 - Area: circumferential trace
 - Normal: <9 mm²
 - Borderline: 9 – 12 mm²
 - Abnormal: > 12 mm²
 - 12.8 mm² = moderate (83% sens, 95% spec)
 - 14.0 mm² = severe (77% sens, 100% spec)



Klauser AS et al. Sem Musculoskel Rad 2010; 14:487
Ooi et al. Skeletal Radiol 2014; 43:1387

20

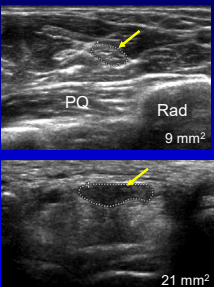
Carpal Tunnel Syndrome



21

Carpal Tunnel Syndrome

- Compare areas:
 - Proximal: pronator quadratus
 - Distal: carpal tunnel
- = or >2 mm² = carpal tunnel syndrome
- 99% sensitivity
- 100% specificity

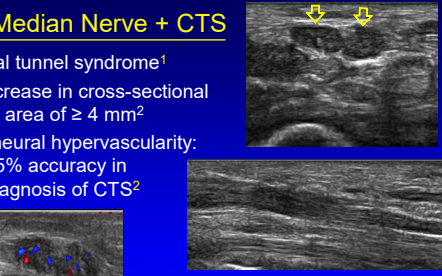


Klauser AS. Radiology 2009; 250:171

22

Bifid Median Nerve + CTS

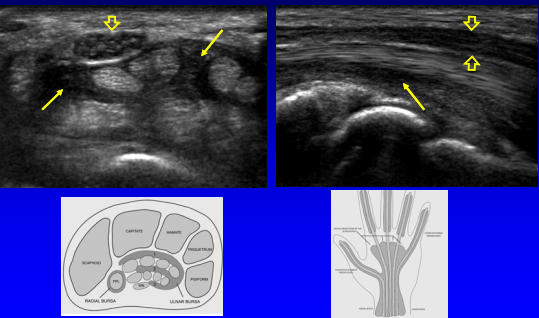
- Carpal tunnel syndrome¹
 - Increase in cross-sectional area of ≥ 4 mm²
- Intraneural hypervascularity: 95% accuracy in diagnosis of CTS²



¹Klauser et al. Radiology 2011; 259; 808
²Mallouhi et al. AJR 2006; 186:1240

23

Carpal Tunnel Syndrome: ulnar bursa distention

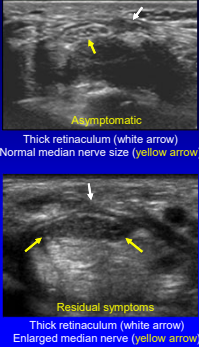


24

Postoperative Carpal Tunnel

- Discontinuous or thickened transverse carpal ligament
- Anterior displacement of transverse carpal ligament¹
- Median nerve size:
 - May decrease²
 - Does not correlate with success³

¹Lee CH et al. Ann Plast Surg 2005; 54:143
²Abicalaf CA et al. Clin Radiol 2007; 62:891
³Naranjo A et al. Scand J Rheum 2010; 39:49



25

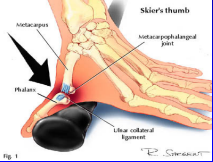
Outline:

- Joint effusion / synovitis
- De Quervain tenosynovitis
- Carpal tunnel syndrome
- Gamekeeper's thumb**
- Pulley abnormalities
- Ganglion


26

Gamekeeper's or Skier's Thumb

- Injury: ulnar collateral ligament of first MCP joint
- Chronic (gamekeeper's thumb): historically in Scottish gamekeepers
- Acute (skier's thumb): acute hyperabduction



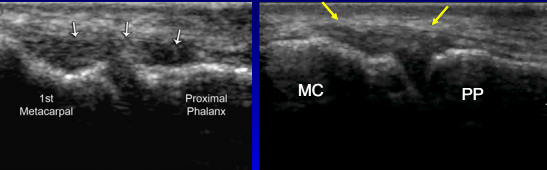
Acute Mechanism




Chronic Mechanism

27

Ulnar Collateral Ligament: thumb

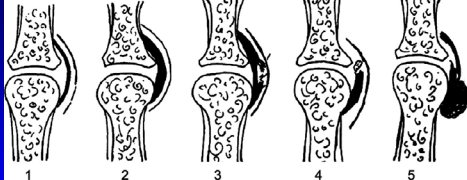


Note: sliding of adductor aponeurosis with isolated interphalangeal joint flexion




28

Ulnar Collateral Ligament: thumb



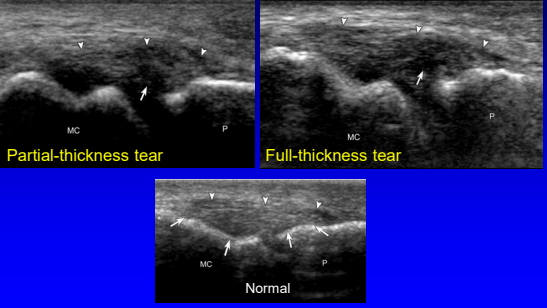
1 Normal 2 Sprain 3 Partial Tear 4 Nondisplaced Complete Tear 5 Displaced Complete Tear (Stener Lesion) (+ fracture)

RadioGraphics 2006;26:1007



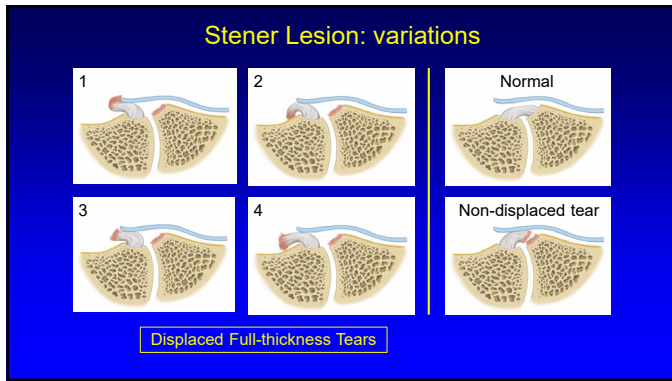
29

UCL: tears

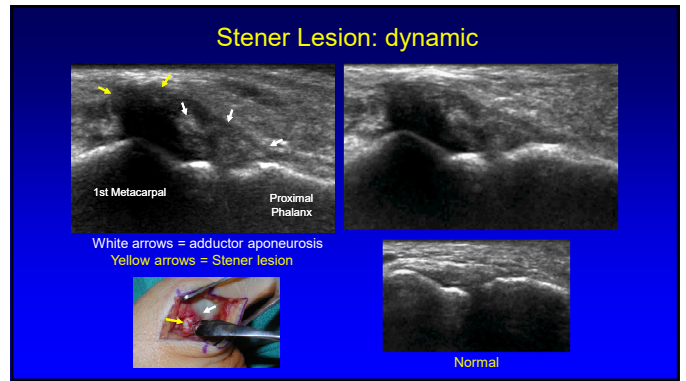


Partial-thickness tear Full-thickness tear Normal

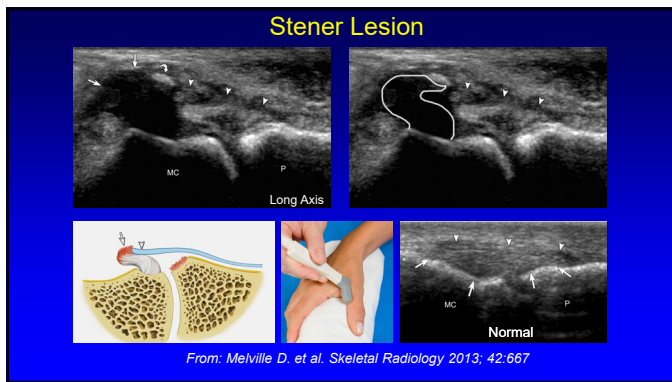
30



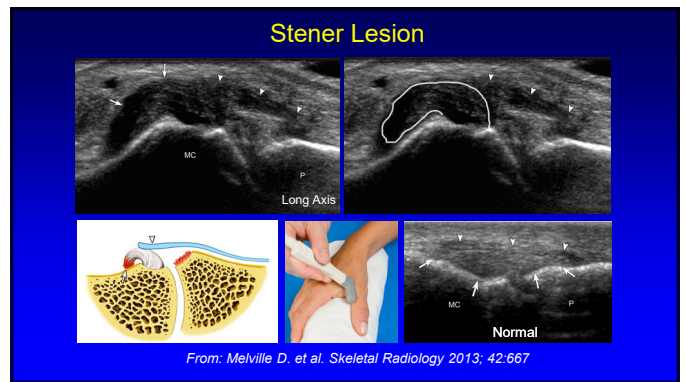
31



32



33



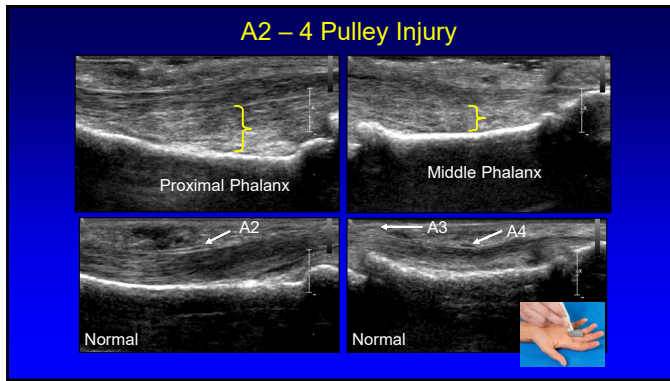
34

- ### Outline:
- Joint effusion / synovitis
 - De Quervain tenosynovitis
 - Carpal tunnel syndrome
 - Gamekeeper's thumb
 - **Pulley abnormalities**
 - Ganglion

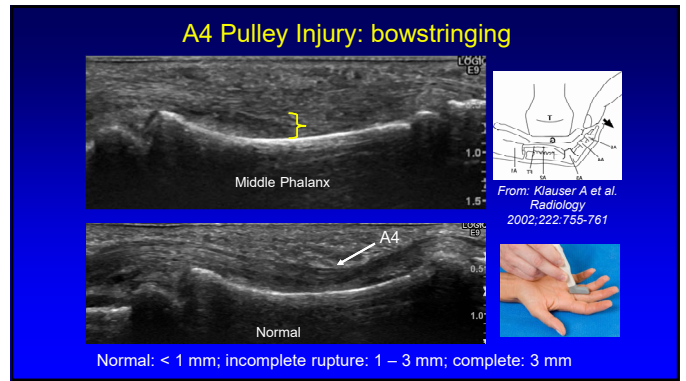
35

- ### Pulley Tear
- A2 and A4 pulleys: most important
 - Sagittal image
 - Bowstringing
 - Hypoechoic edema / hemorrhage
 - Dynamic evaluation*
-
- A5 C3 A4 A2 A1 C2 A3 C1
- *Radiology 2002; 222:755
Radiology 1998; 206:339

36



37



38

Trigger Finger

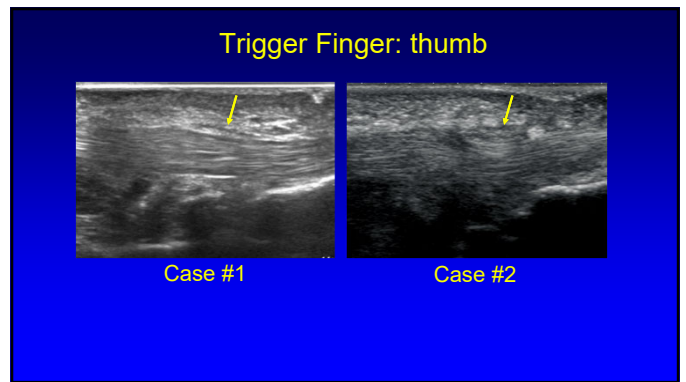
- Stenosing tenosynovitis: A1 pulley
- Thick and hypochoic pulley
- Hyperemia: 91%
- Tendinosis: 48%
- Tenosynovitis: 55%

Guerini et al. J Ultrasound Med 2008; 27:1407

Case #1

Case #2

39



40

Outline:

- Joint effusion / synovitis
- De Quervain tenosynovitis
- Carpal tunnel syndrome
- Gamekeeper's thumb
- Pulley abnormalities
- **Ganglion**

41

Soft Tissue Mass: wrist ganglia

- Most wrist masses are ganglion cysts
- Volar (69%): radial artery & flexor carpi radialis
 - Proximal from radioscaphoid joint capsule
- Dorsal: scapholunate ligament
 - Not compressible (unlike joint recess)

Zhang A et al. J Ultrasound Med 2019; 38:2155

42

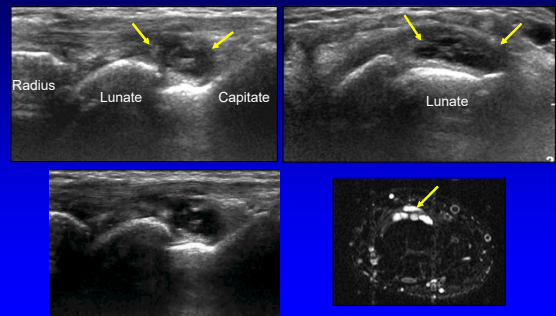
Soft Tissue Mass: wrist ganglia

- Anechoic or hypoechoic
- Multilocular (except digits)
- Non-compressible
- Joint or tendon sheath communication
- <10 mm: hypoechoic without posterior acoustic enhancement

*Wang et al. J Ultrasound Med 2007; 26:1323

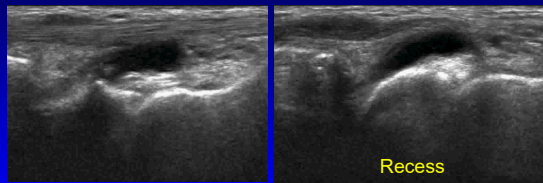
43

Ganglion: dorsal



44

Ganglion vs Dorsal Recess



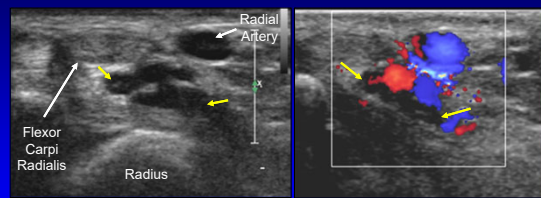
Ganglion: not compressible

Recess: compressible

Sagittal with Wrist Flexion

45

Ganglion: volar



Axial

color Doppler

46

Take Home Points:

- Arthritis: emphasize synovitis
- De Quervain: separate sheaths
- Carpal tunnel syndrome:
 - 2 mm² enlargement
- Gamekeeper: Stener lesion
- Pulley: bowstringing
- Ganglion: multilocular, location

47

Thank you!

Syllabus on line and other educational material:
www.jacobsonmskus.com

Twitter handle: @jjacobsn

48