

Ankle and Foot Ultrasound: Anatomy and Scanning Technique

Jon A. Jacobson, MD FACR
FSRU, FAIUM, RMSK

Professor of Radiology
Lenox Hill Radiology, NYC
University of California, San Diego

1

Disclosures

- Consultant: Bioclinica
- Advisor: Philips
- Book Royalties: Elsevier
- Not relevant to this lecture

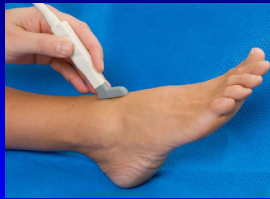*Note: all images from the textbook
Fundamentals of Musculoskeletal Ultrasound are
copyrighted by Elsevier Inc.*

See www.jacobsonmskus.com for syllabus other educational material

2

Technique: anterior

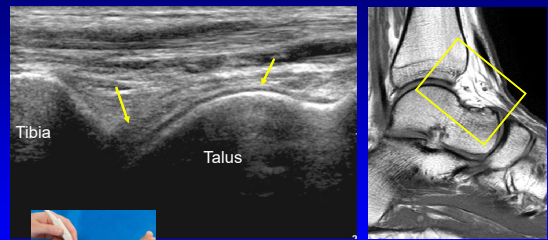
- Anterior joint recess
 - Plantar flexion
 - Hyperechoic extracapsular fat pad
 - Hypoechoic hyaline cartilage



AJR 1998; 170:1231

3

Tibiotalar Joint

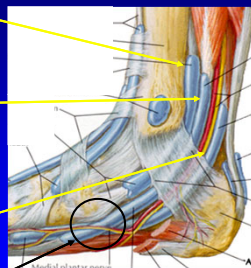


Sagittal

4

Medial Tendons

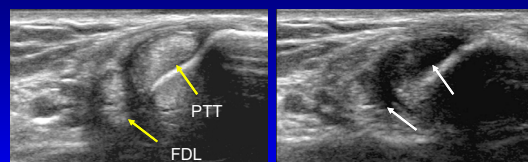
- Tibialis posterior
 - Navicular > cuneiforms
 - Metatarsals 2 – 4
- Flexor digitorum longus
 - Distal phalanges #2 – 5
- Tibial nerve, artery, veins
- Flexor hallucis longus
 - Base of distal 1st phalanx
 - *Knot of Henry: FHL & FDL



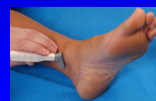From: Netter's Atlas of Human Anatomy

5

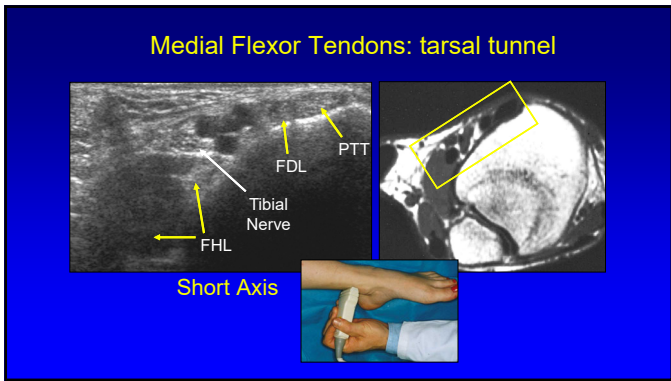
Medial Tendons: short axis



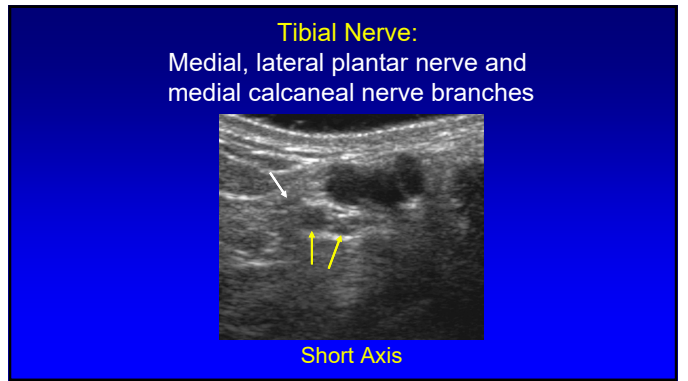
Anisotropy



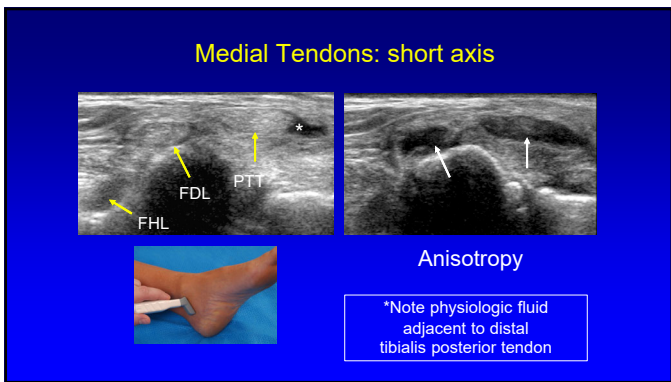
6



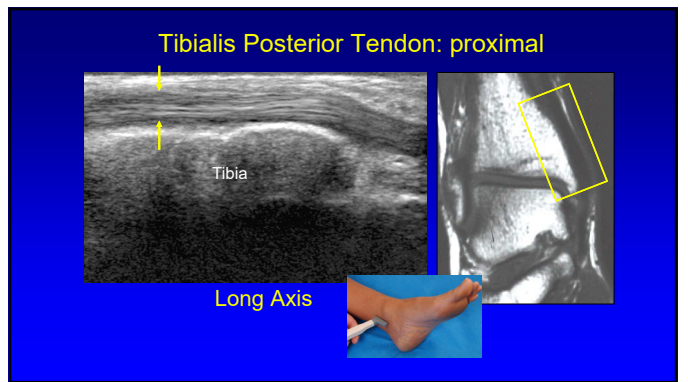
7



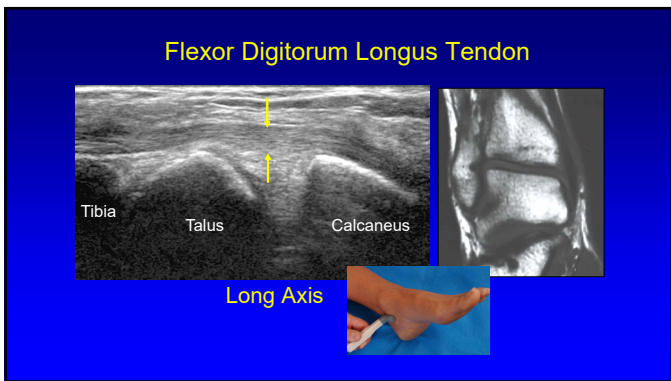
8



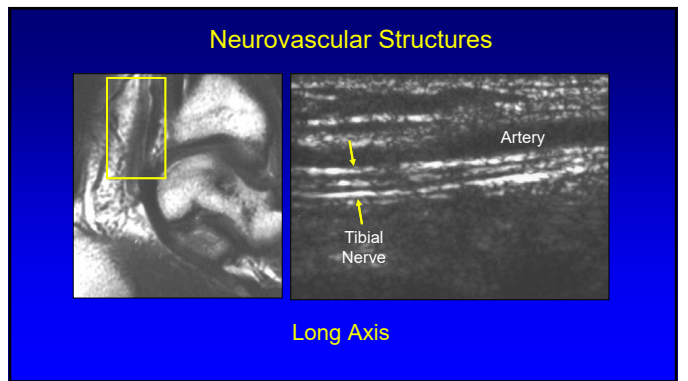
9



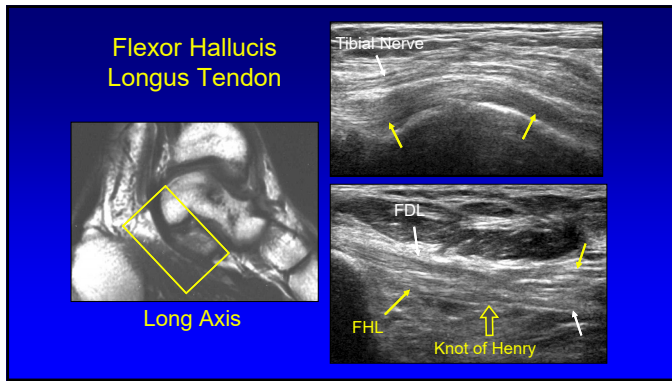
10



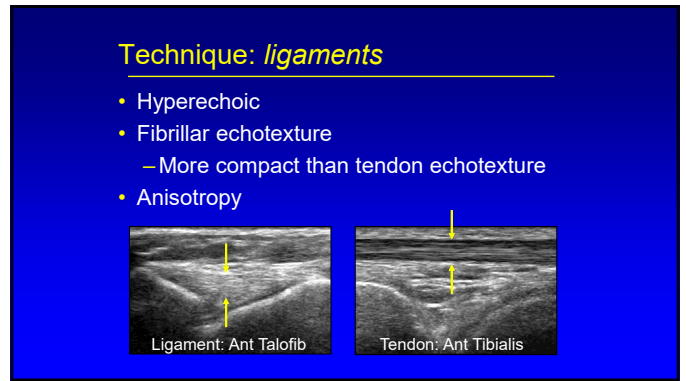
11



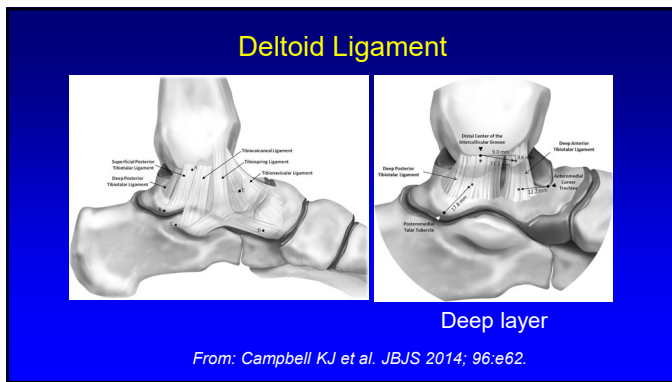
12



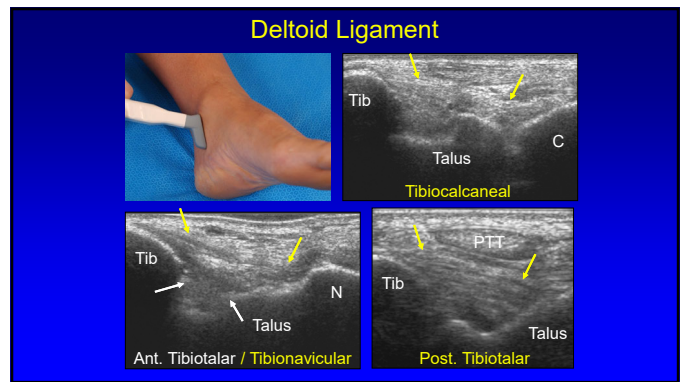
13



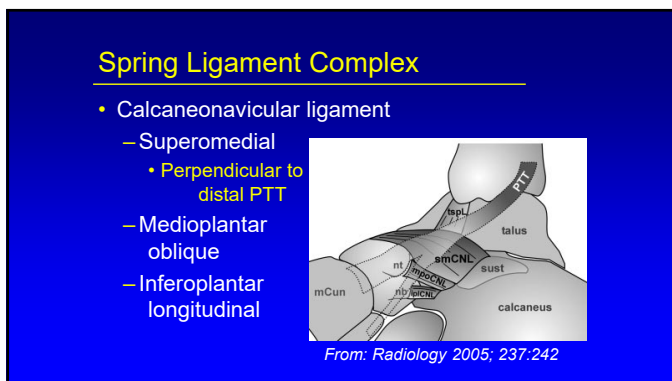
14



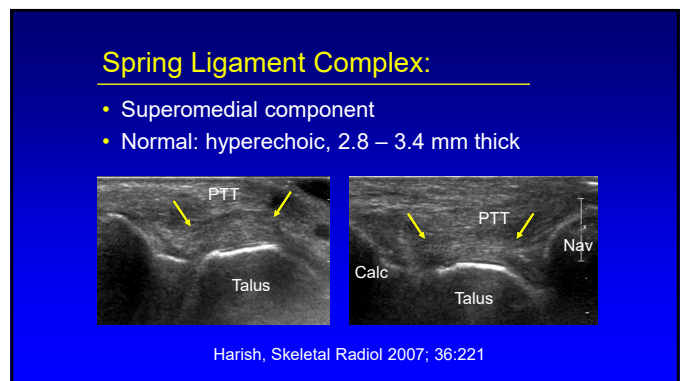
15



16



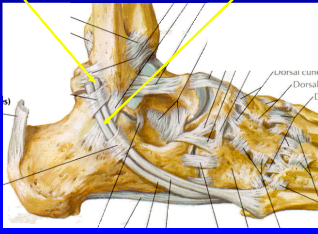
17



18

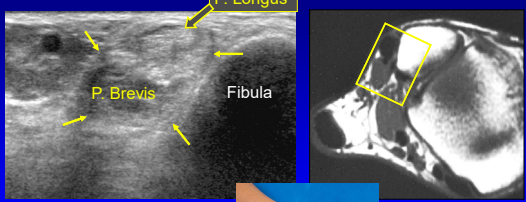
Lateral Tendons

- Peroneus brevis:
 - Oval or crescent shaped
 - Inserts of 5th metatarsal
- Peroneus longus
 - Plantar 1st MT base
 - Medial cuneiform




19

Peroneus Longus and Brevis

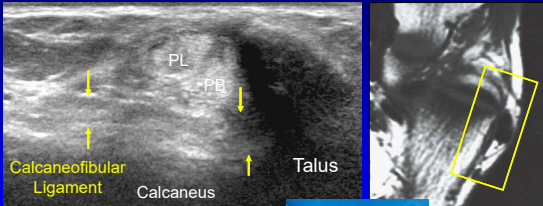


Short Axis




20

Peroneus Longus and Brevis

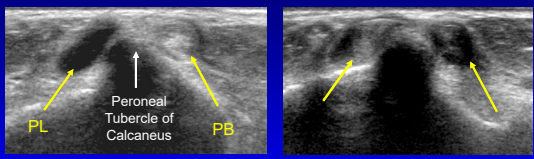


Short Axis




21

Peroneus Longus and Brevis

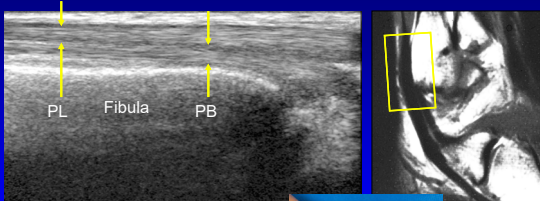


Short Axis Anisotropy




22

Peroneus Longus and Brevis

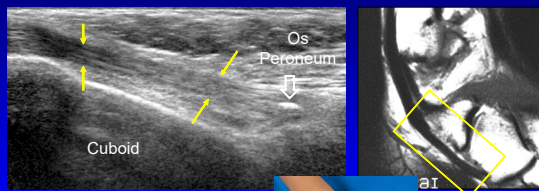


Long Axis




23

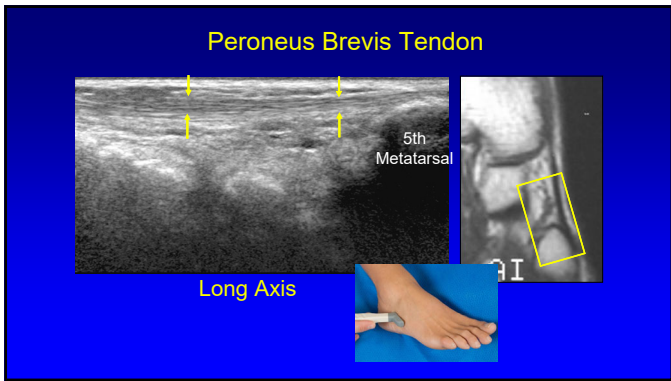
Peroneus Longus Tendon



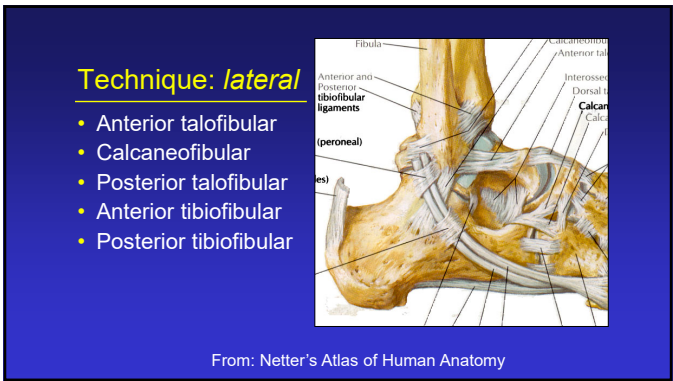
Long Axis



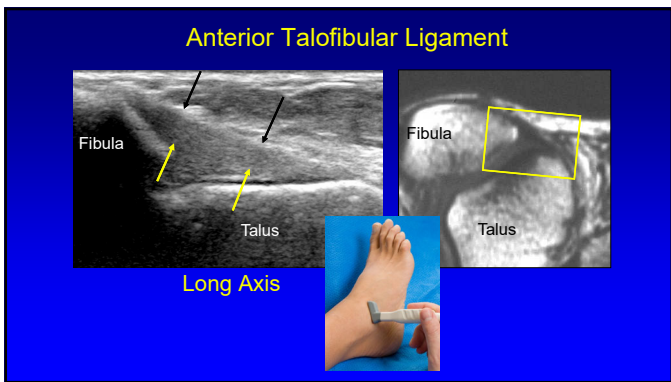
24



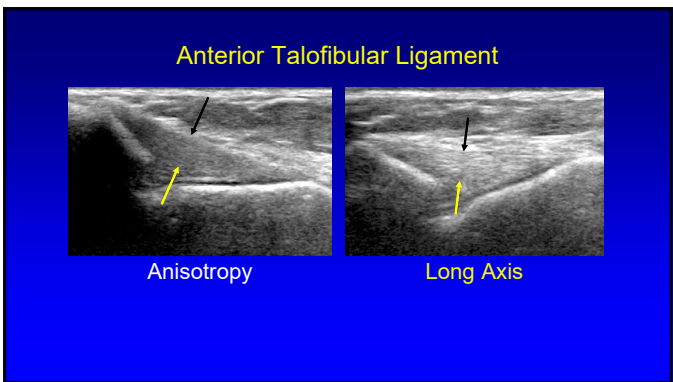
25



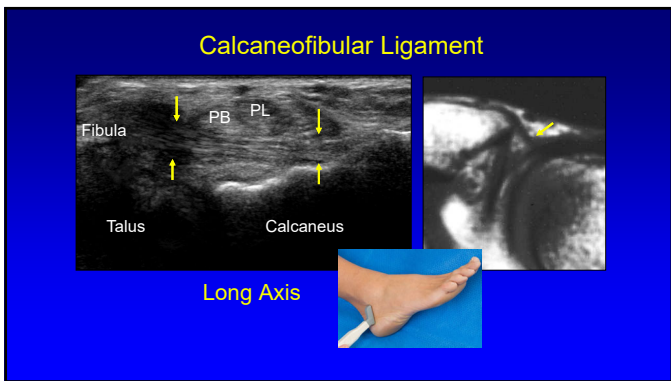
26



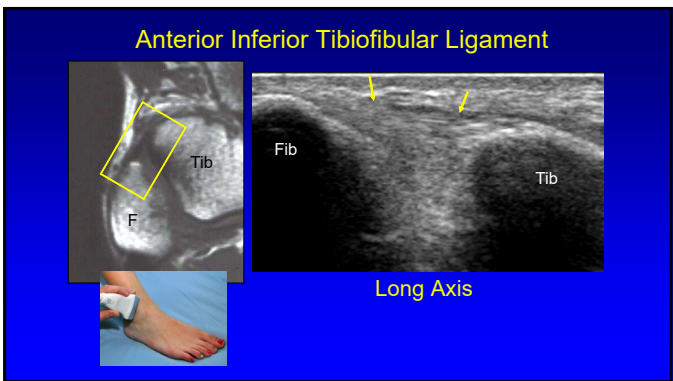
27



28




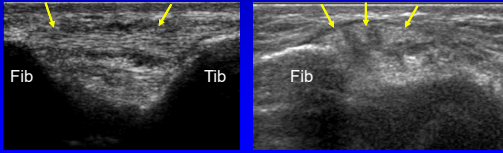
29



30

Inferior Tibiofibular Ligament

- Several bands
- Accessory inferior band (Bassett ligament)
 - Seen in 80 – 90%: more horizontal
 - Potential site of impingement

Radiology 2010; 254:827

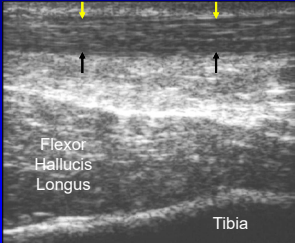
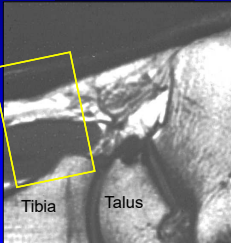
31

Technique: *posterior*

- Tendons / Muscles:
 - Achilles
 - Flexor hallucis longus

32

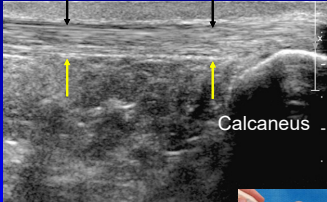
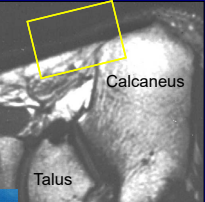
Achilles Tendon: proximal

Long Axis

33

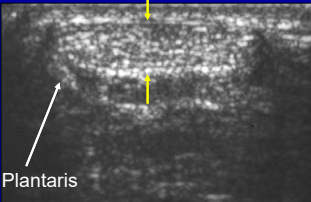
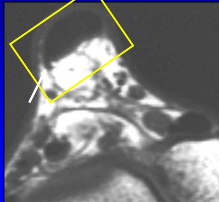
Achilles Tendon: distal

Long Axis

34

Achilles Tendon

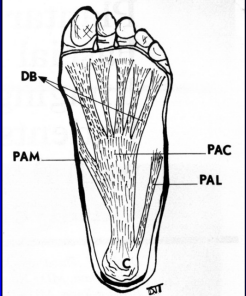



Short Axis

35

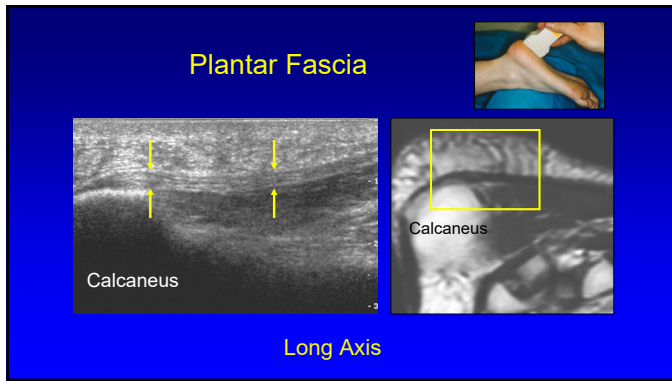
Plantar Fascia or Aponeurosis:

- 3 components:
 - Medial cord
 - Lateral cord
 - Central cord
 - Most important
 - Fibers envelop flexor digitorum brevis



RadioGraphics 2000; 20:181

36

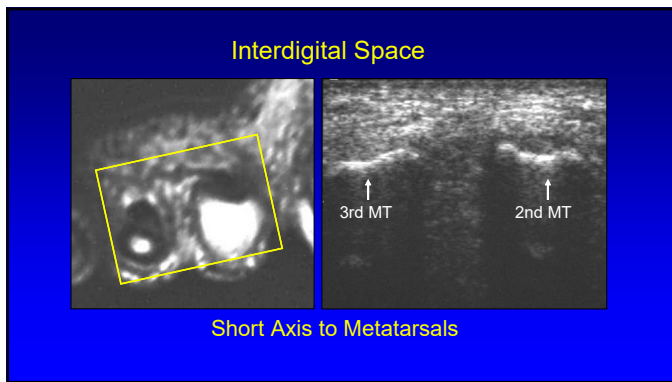


37

Technique: *other*

- Interdigital space
 - Normal digital nerve difficult to visualize
 - Morton's neuroma

38



39

Thank you!

NYC

Ann Arbor

San Diego

Syllabus on line and other educational material:
www.jacobsonmskus.com

40