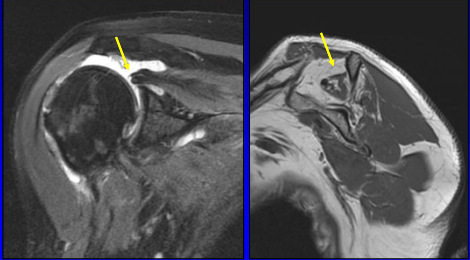


**Musculoskeletal Imaging
Case Conference**

Jon A. Jacobson, MD
FACR, FSRU, FAIM, RMSK
*Musculoskeletal Radiologist
Lenox Hill Radiology, NYC*

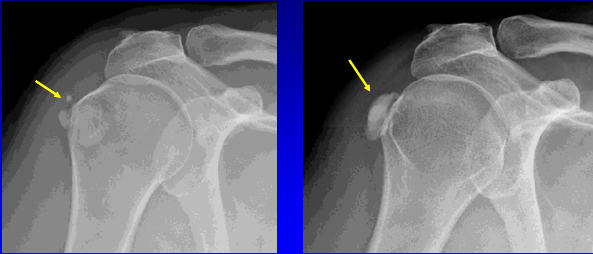
1

Full-thickness Tear: supraspinatus



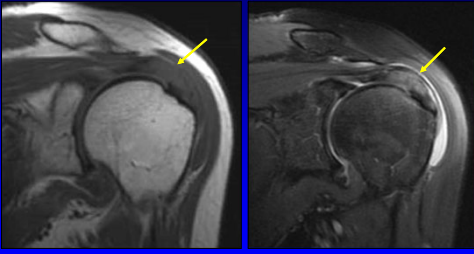
2

Calcium Hydroxyapatite Deposition



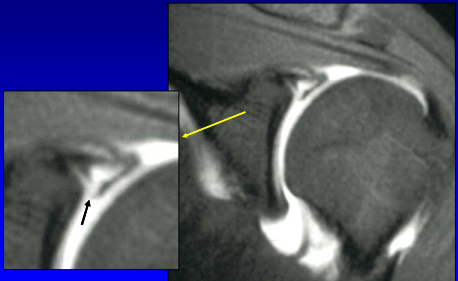
3

Tendinosis: supraspinatus



4


SLAP Tear: Type 2



Coronal-oblique T1w fat-sat

5

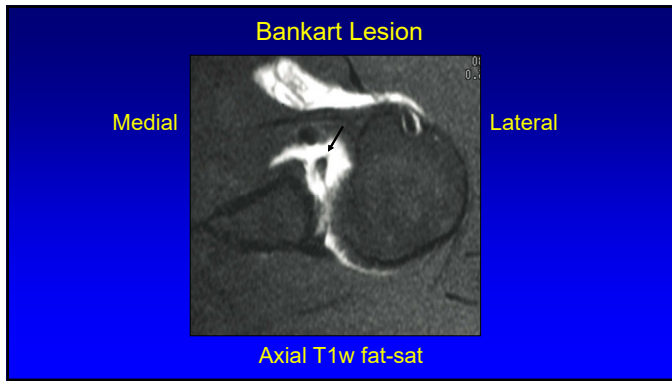
SLAP Tear: Type 2



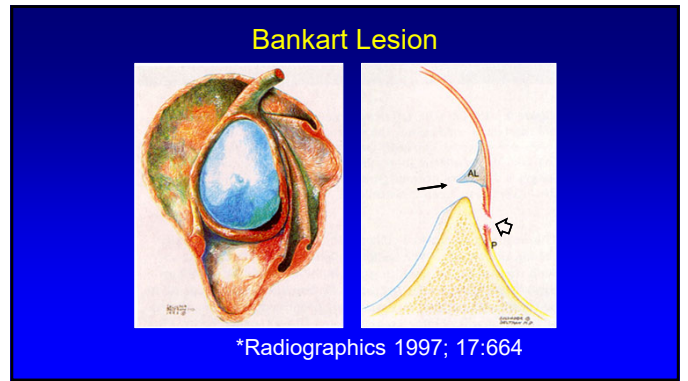
Posterior Anterior

*Radiographics 1997; 17:670

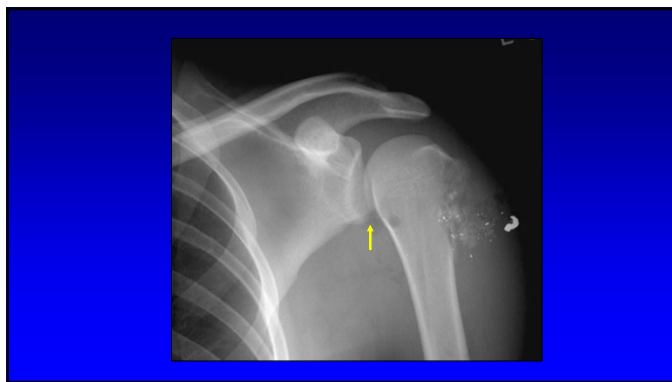
6



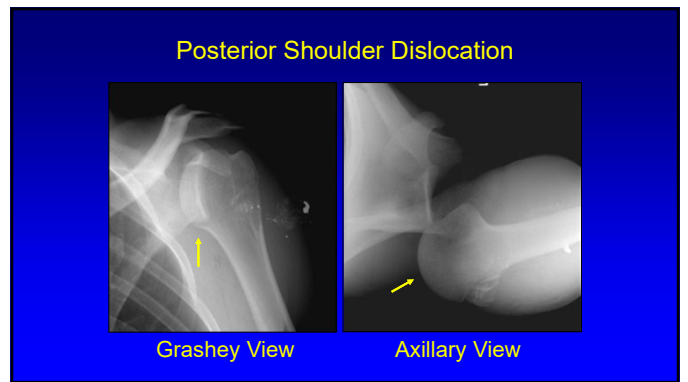
7



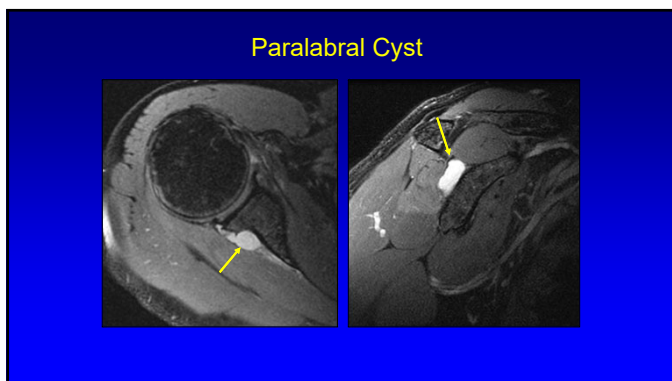
8



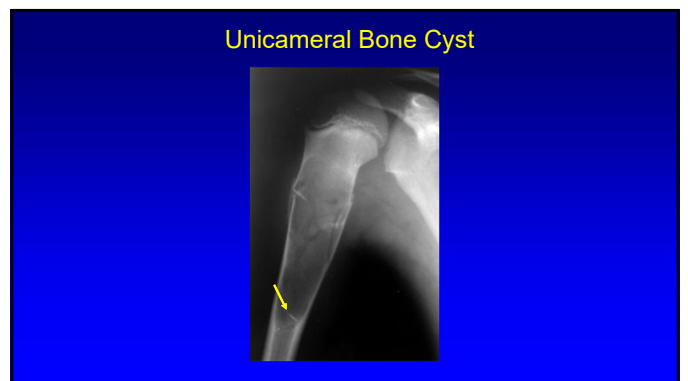
9



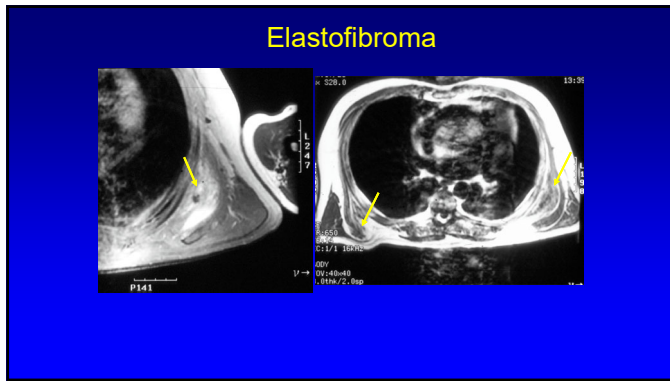
10



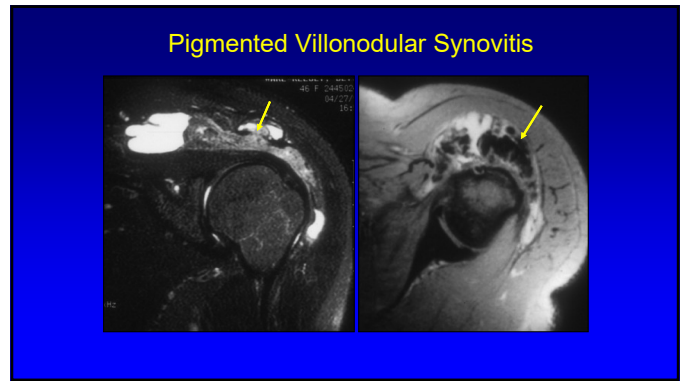
11



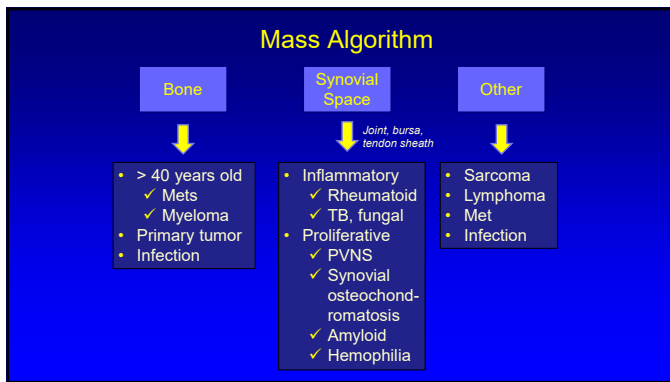
12



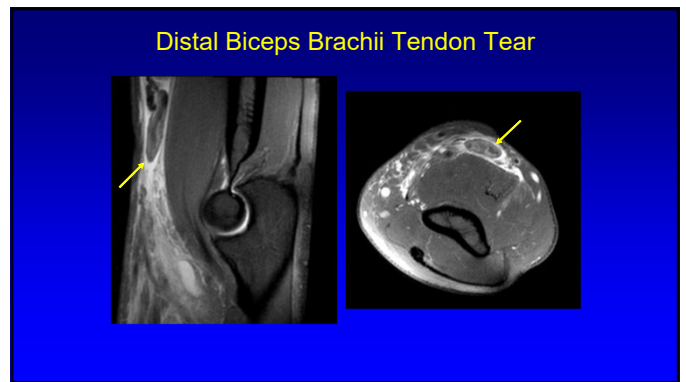
13



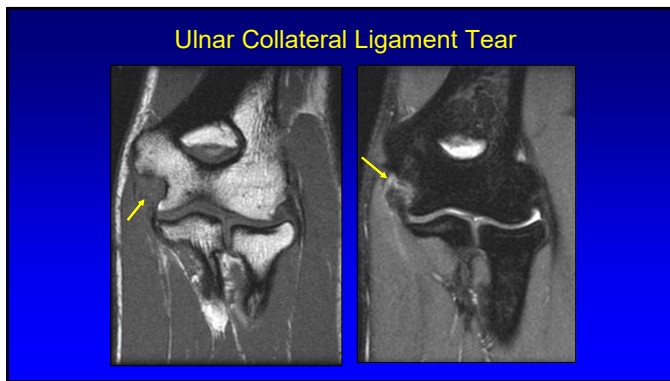
14



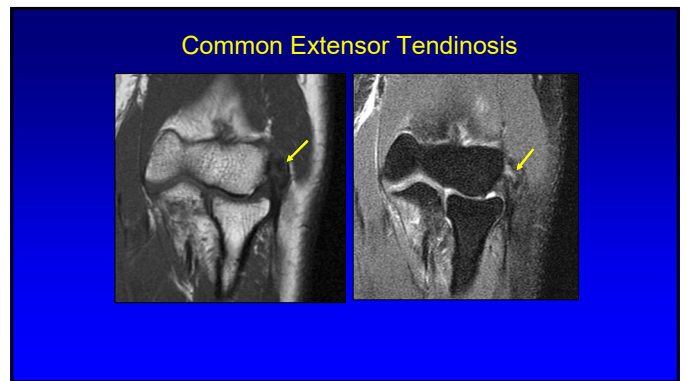
15



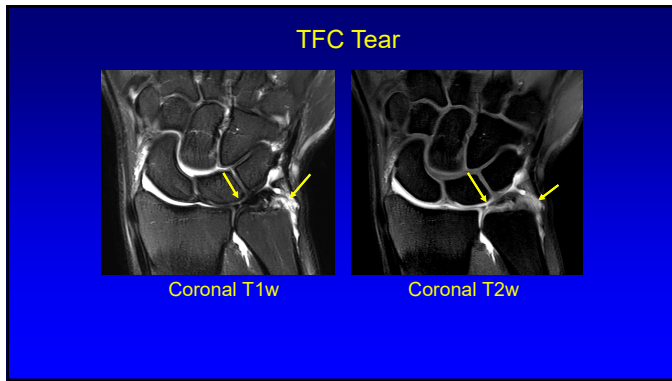
16



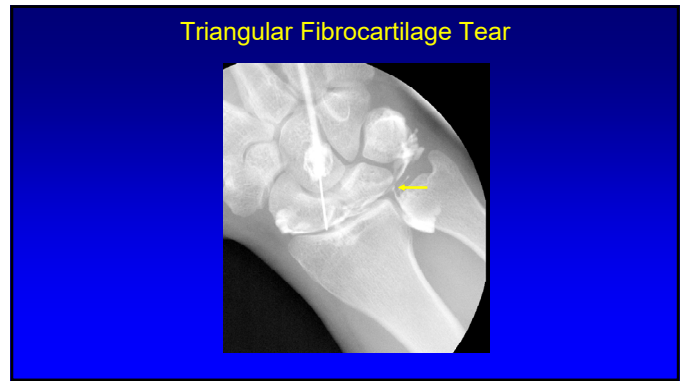
17



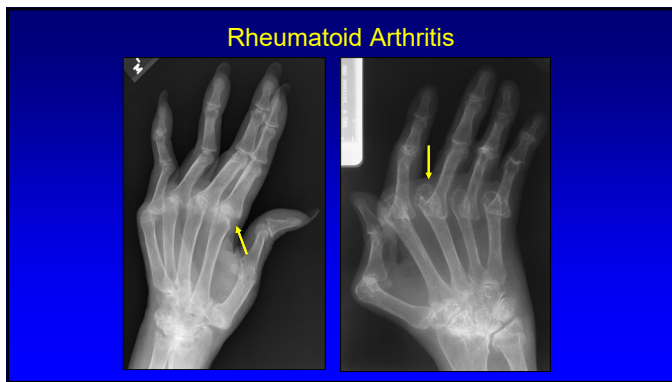
18



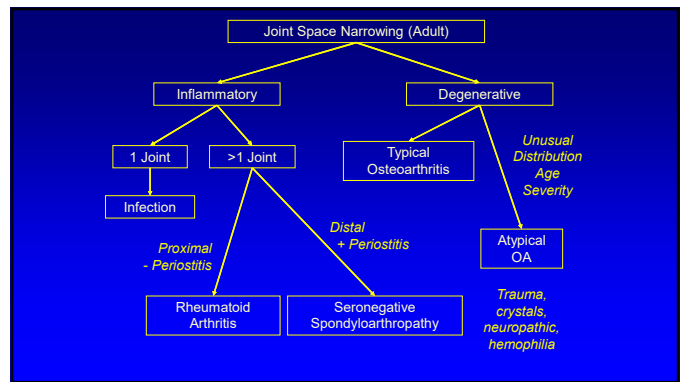
19



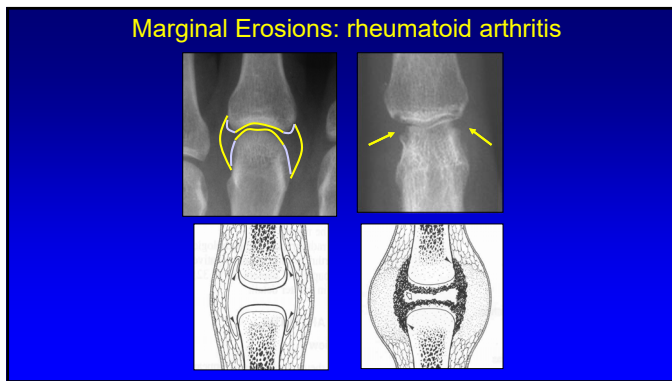
20



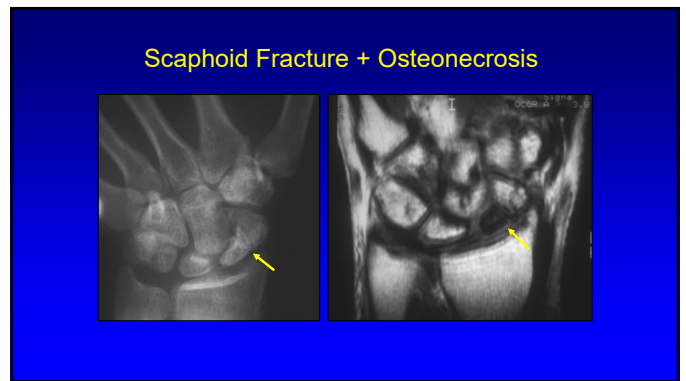
21



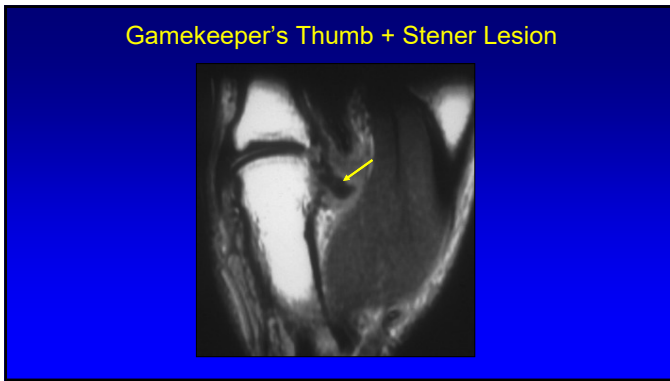22



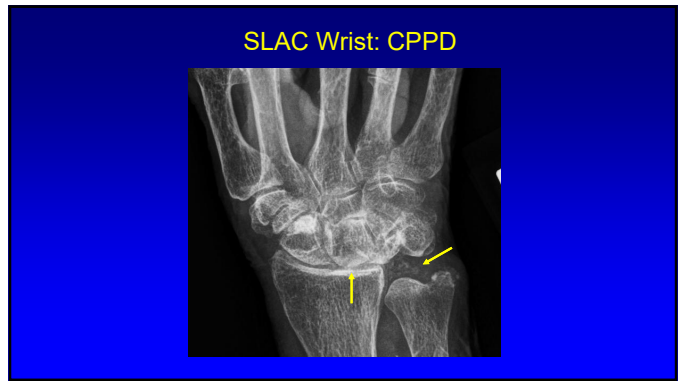23



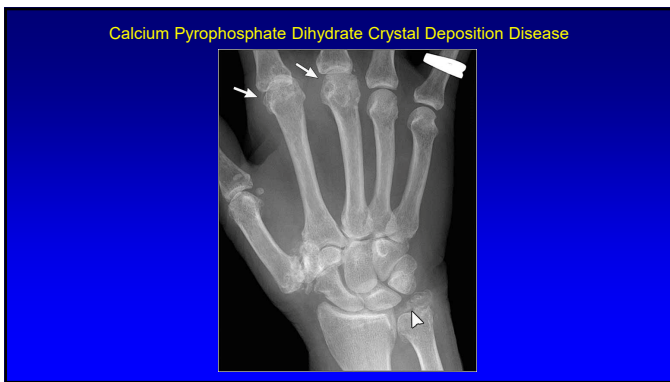24



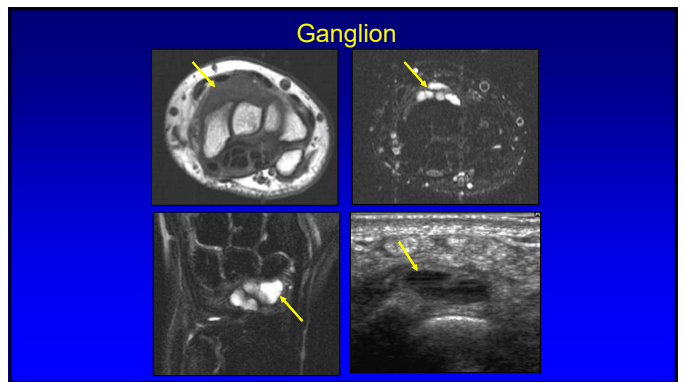
25



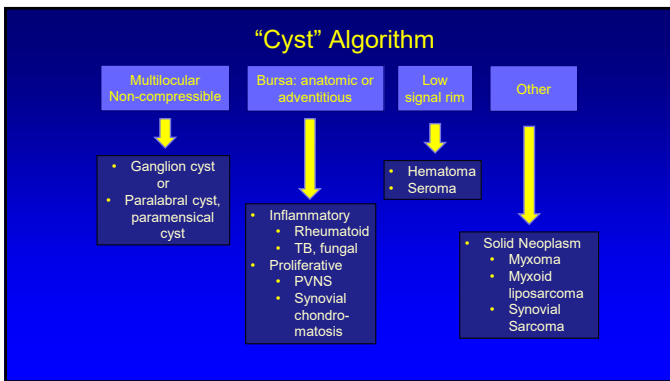
26



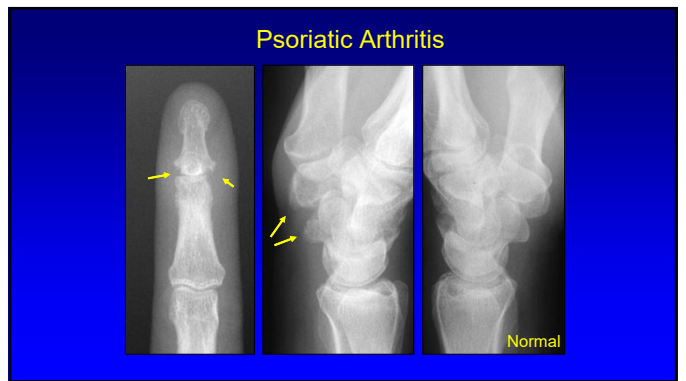
27



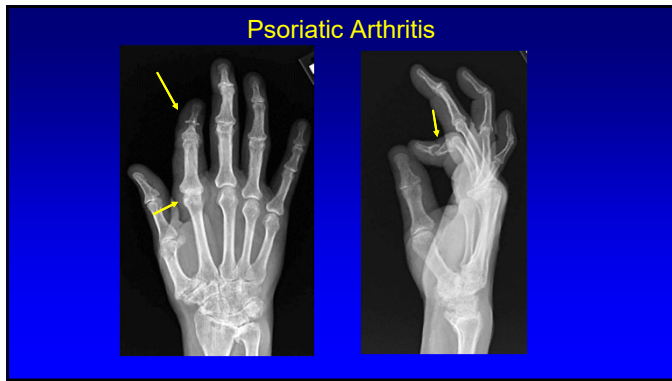
28



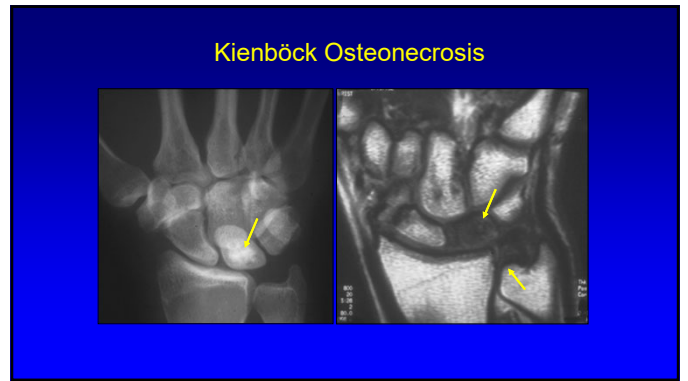
29



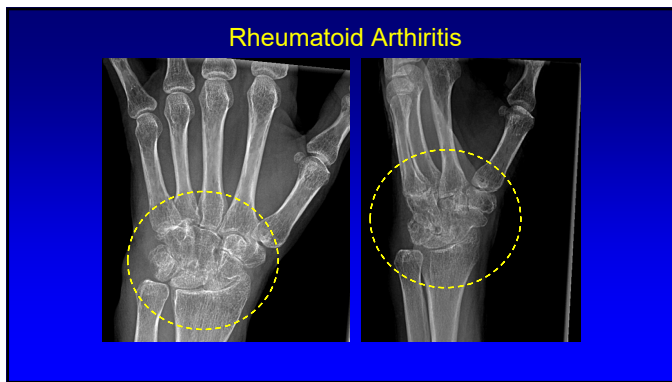
30



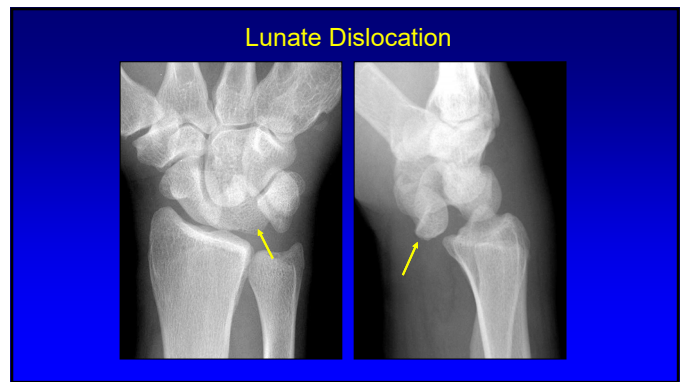
31



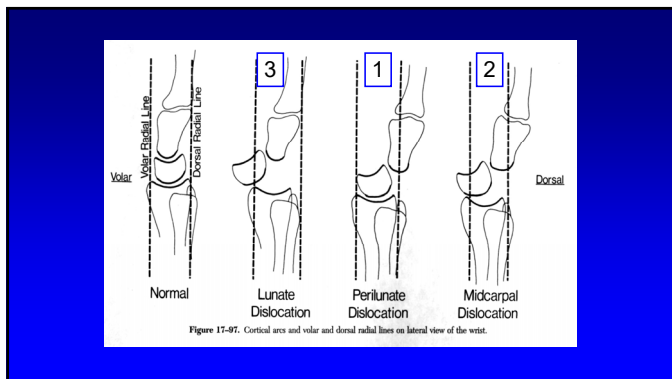
32



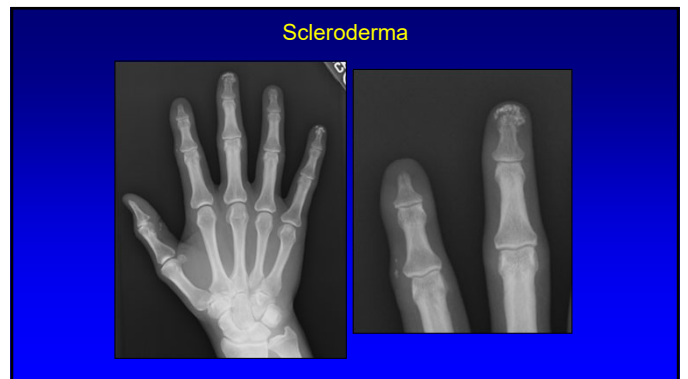33



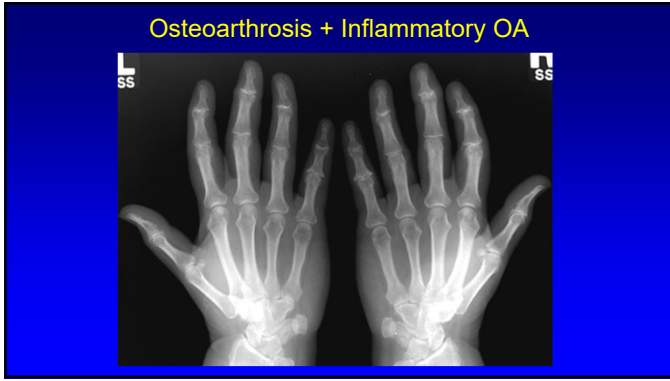34



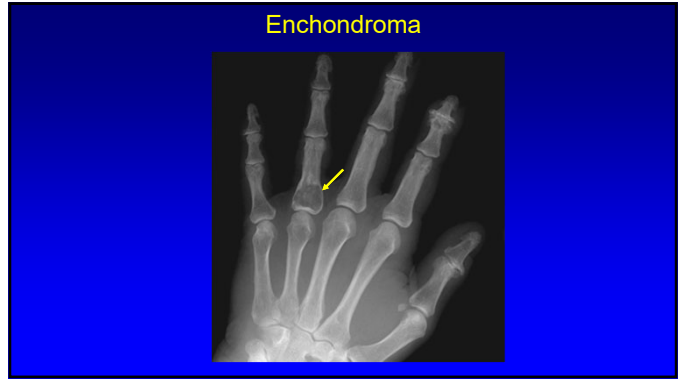35



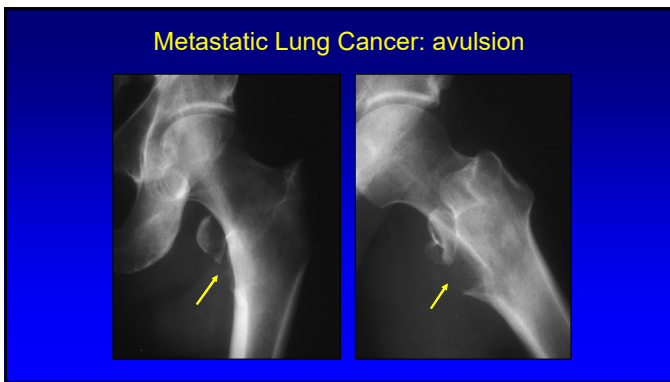
36



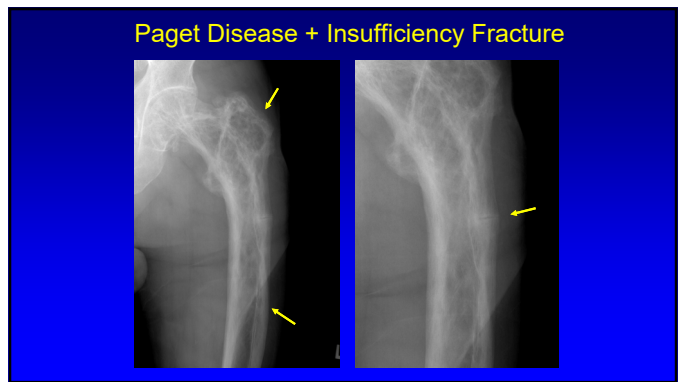
37



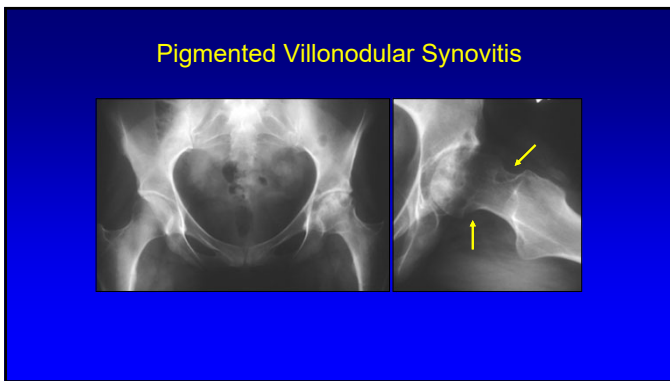
38



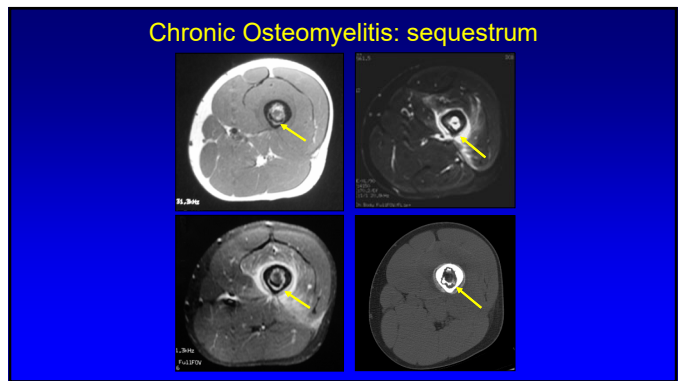
39



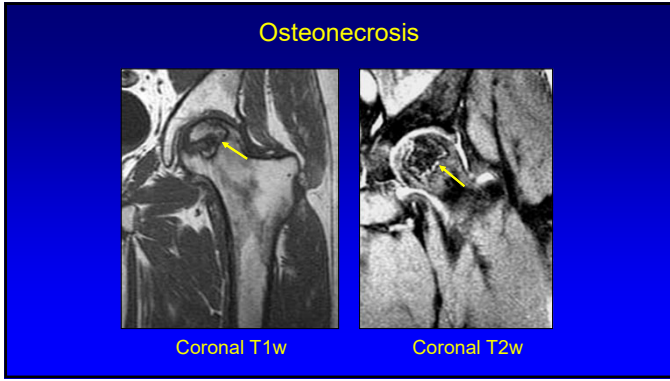
40



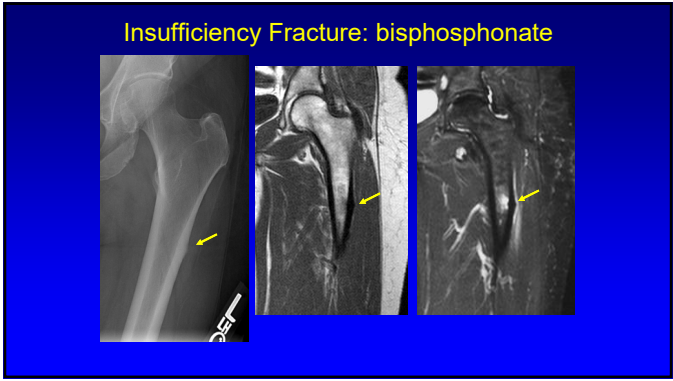
41



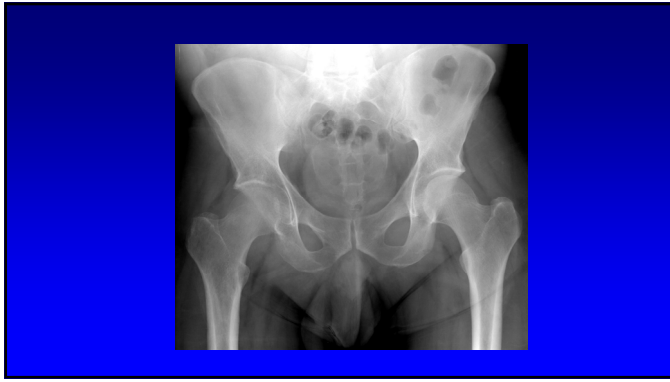42



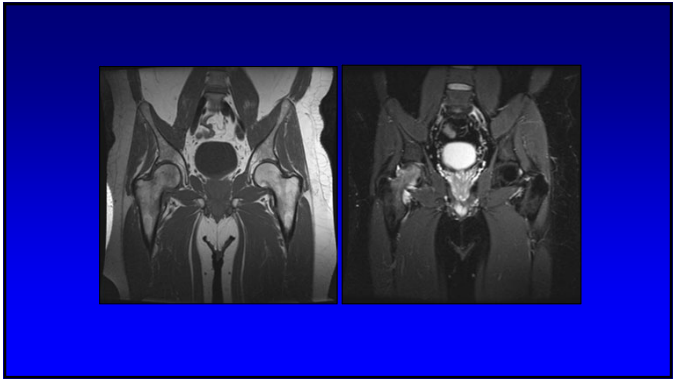
43



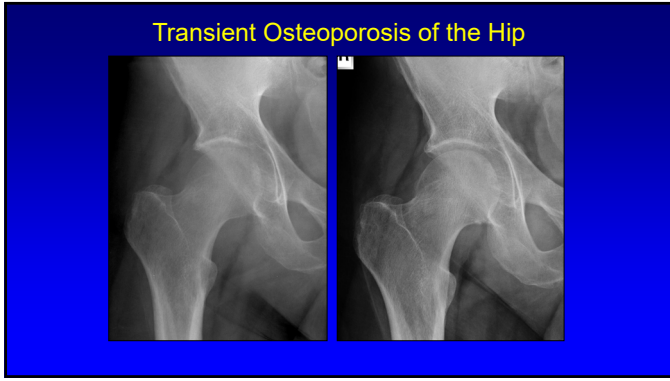
44



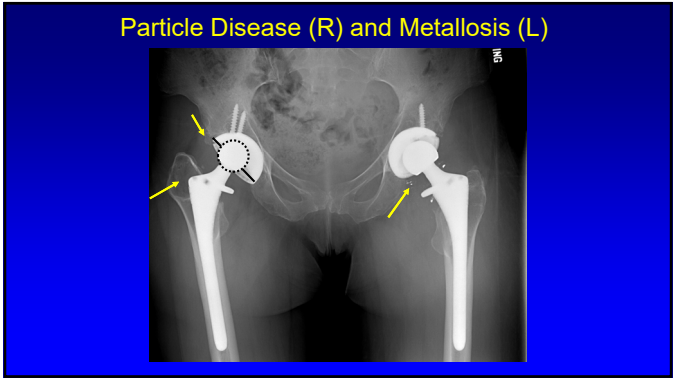
45



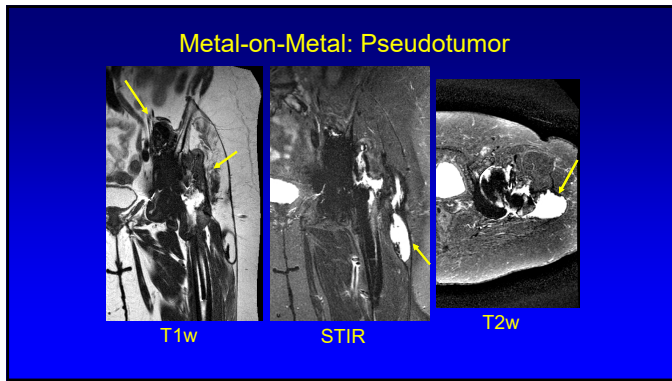
46



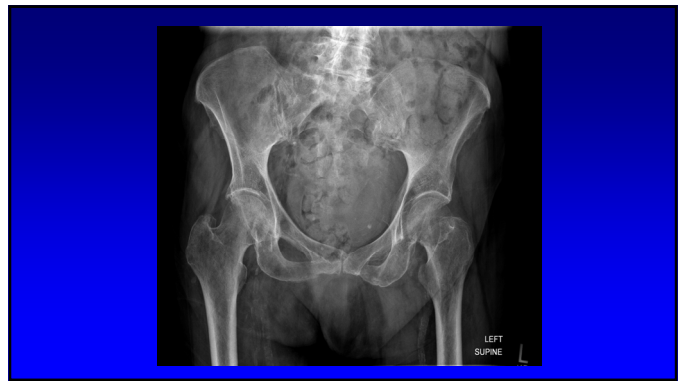47



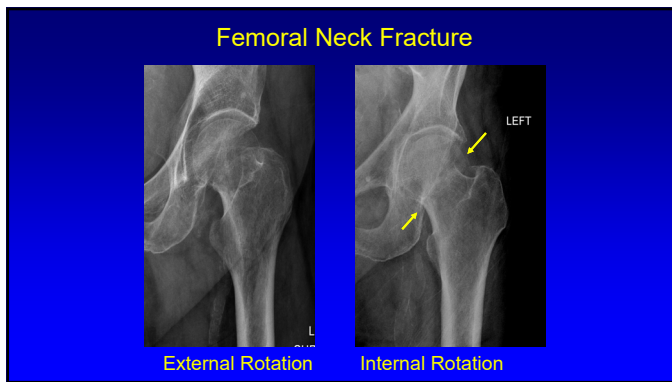
48



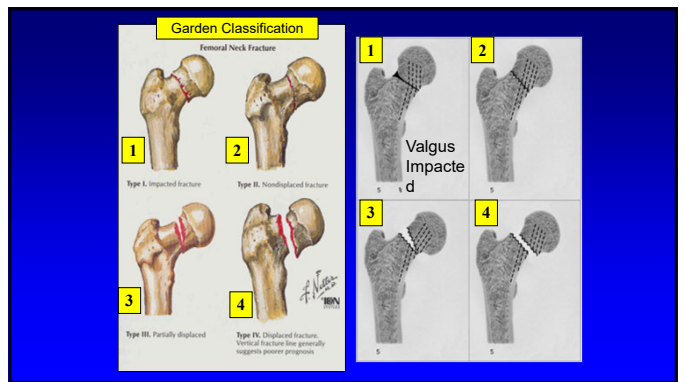
49



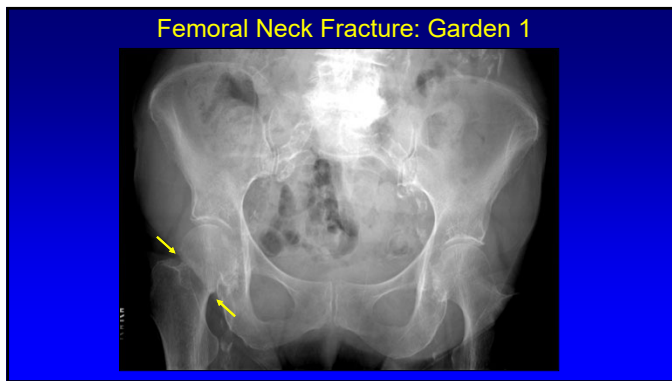
50



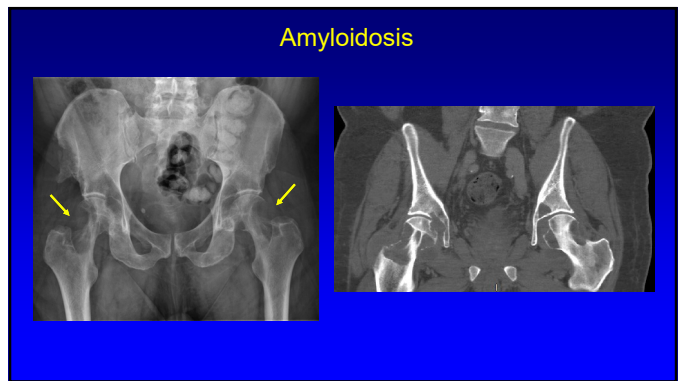
51



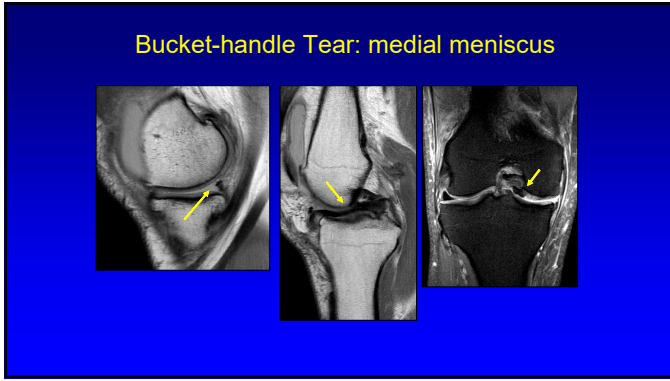
52



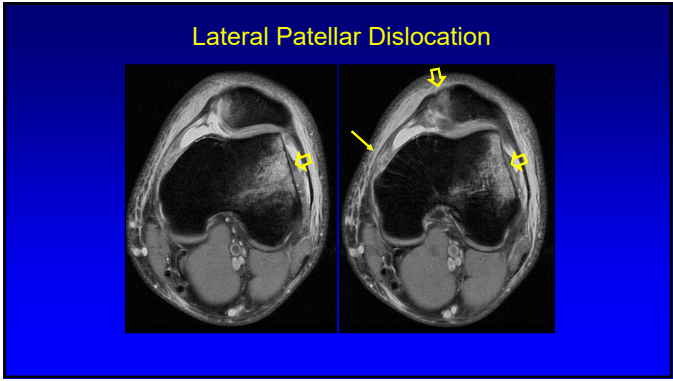
53



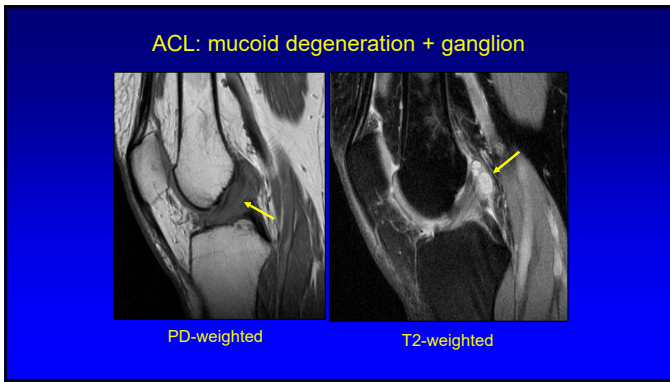
54



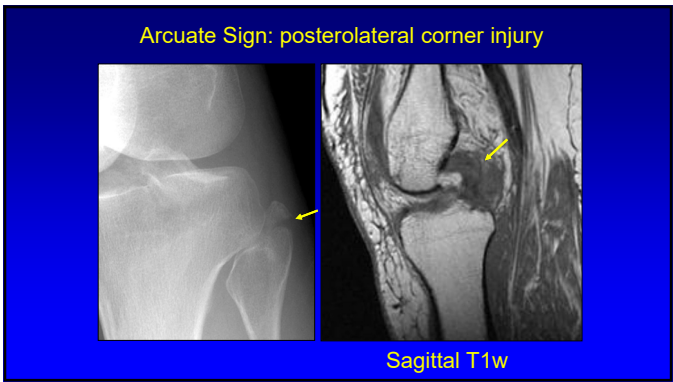
55



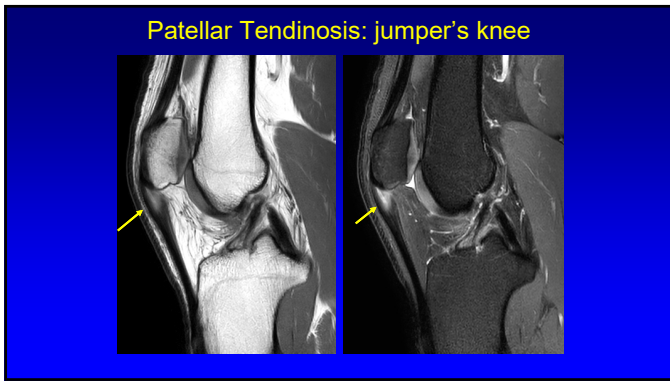
56



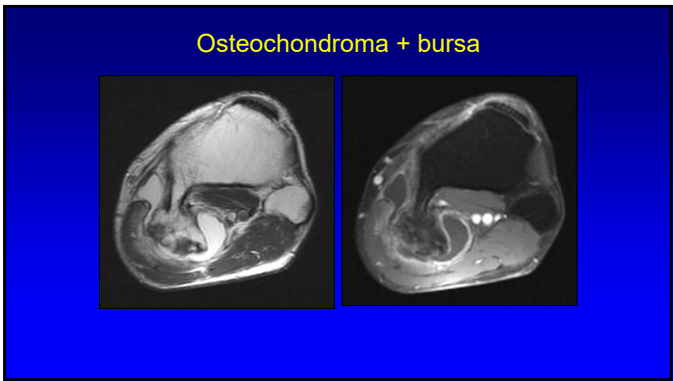
57



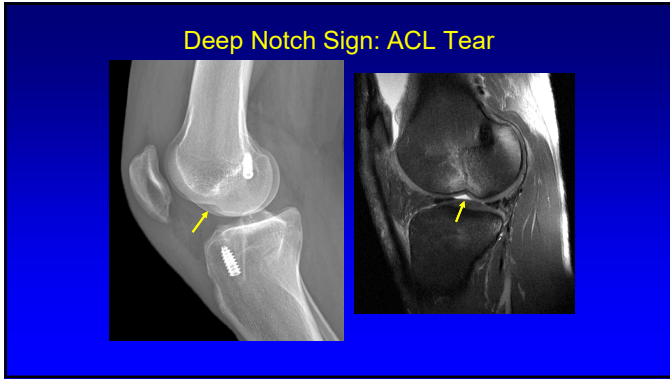
58



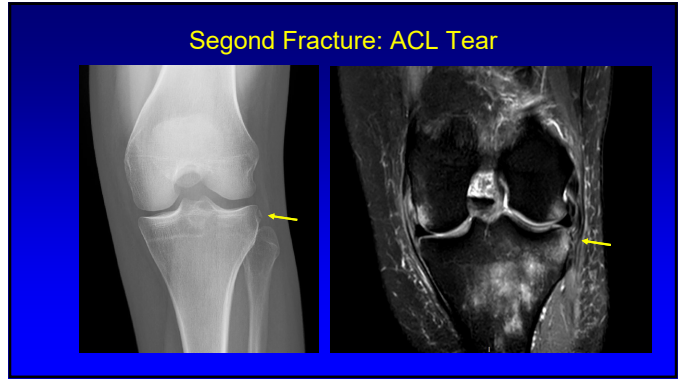
59



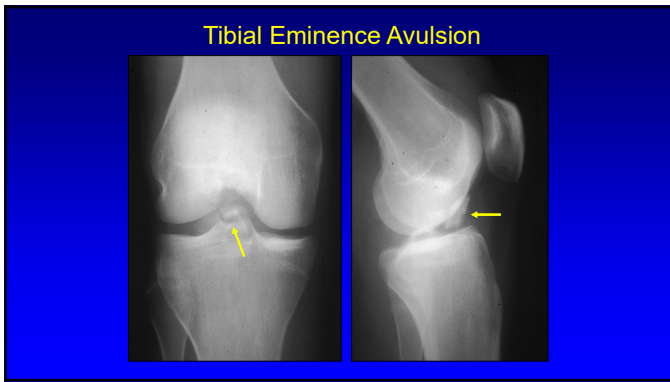
60



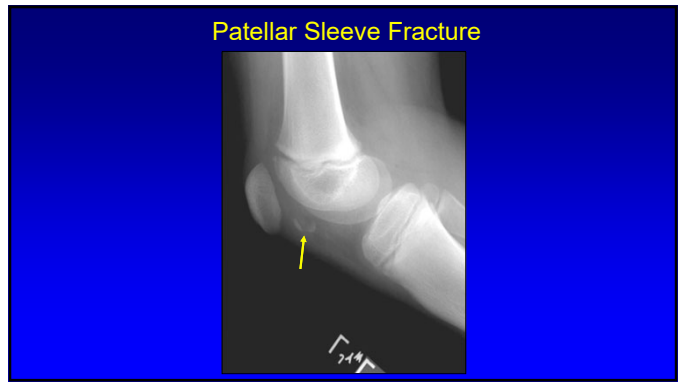
61



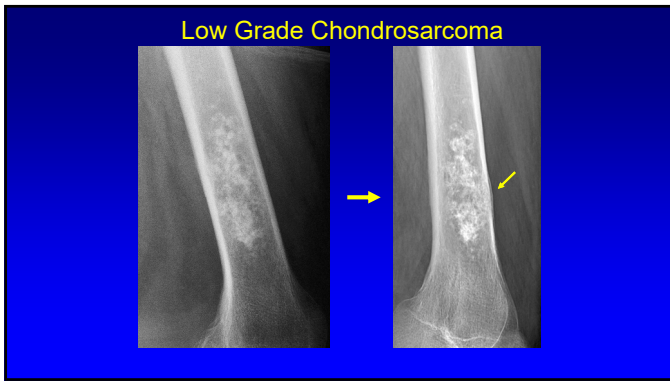
62



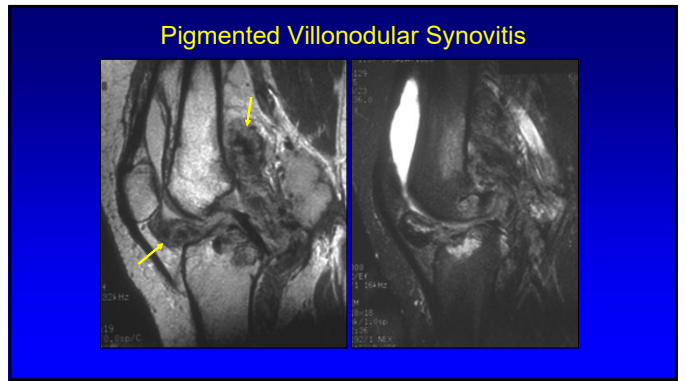
63



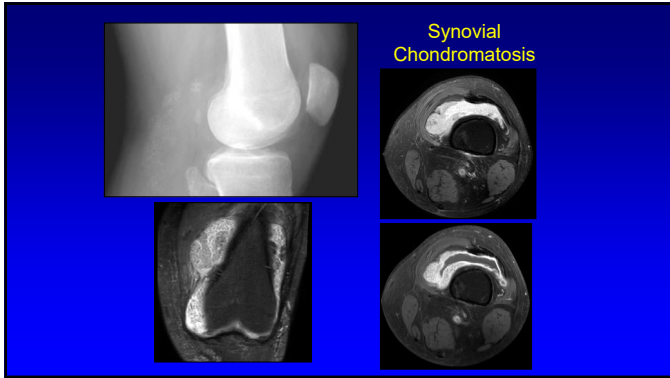
64



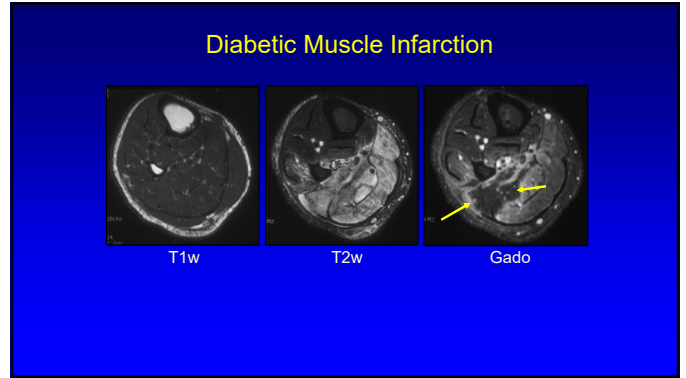
65



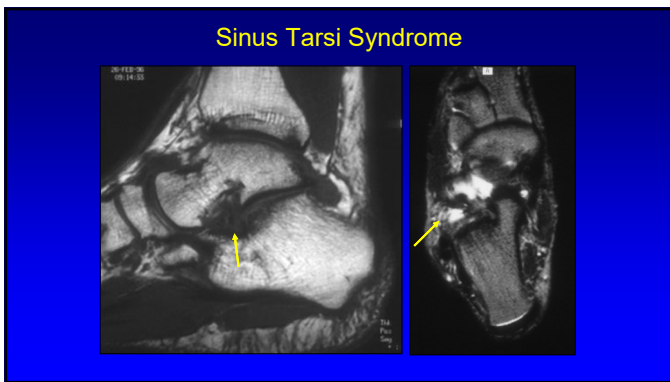
66



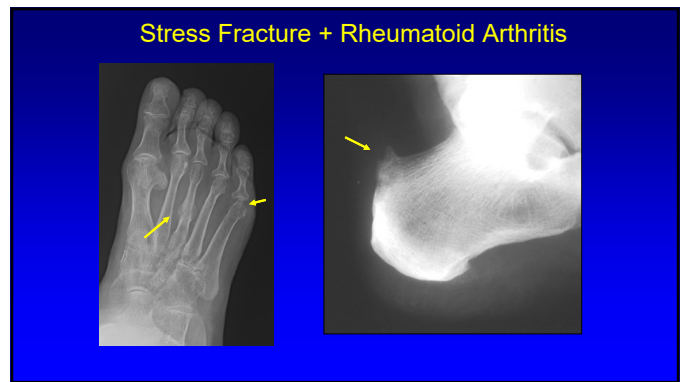
67



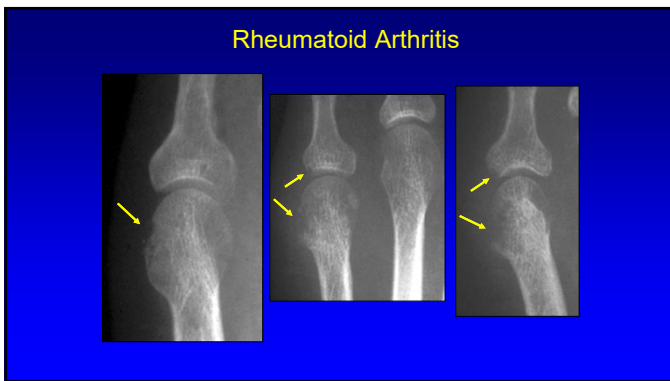
68



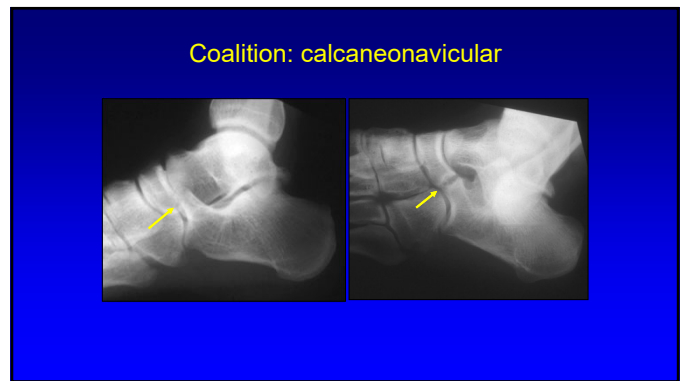
69



70

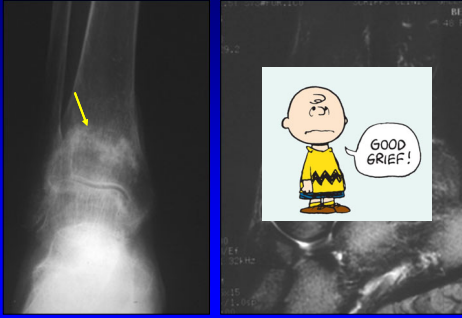


71



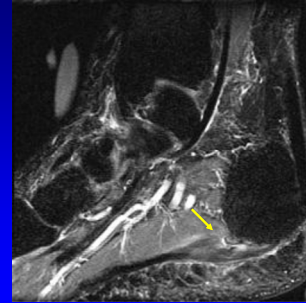
72

Insufficiency Fracture



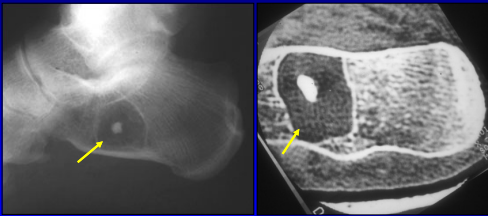
73

Plantar Fasciopathy



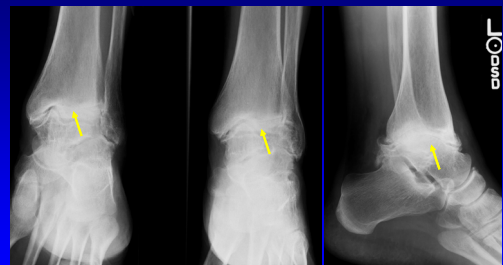74

Intra-osseous Lipoma



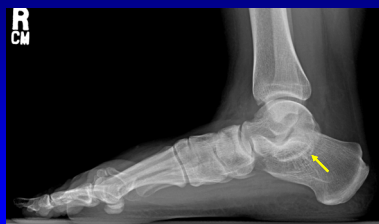75

Hemophilia



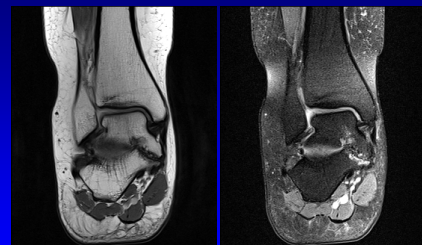
76

Subtalar Coalition

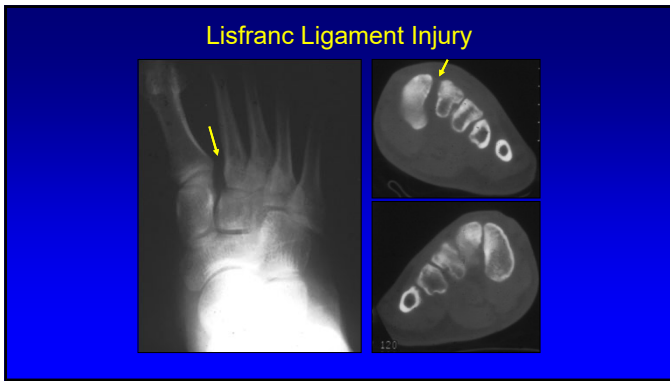


77

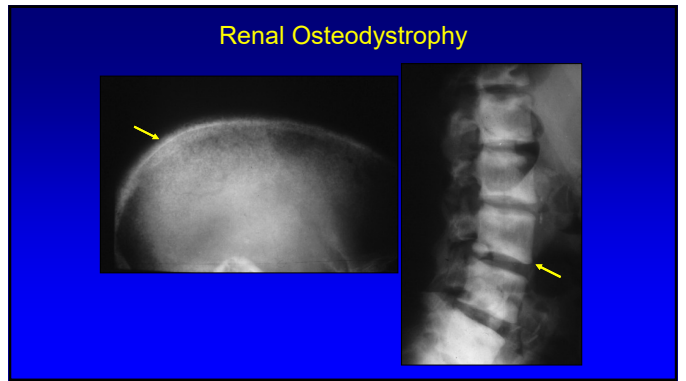
Subtalar Coalition



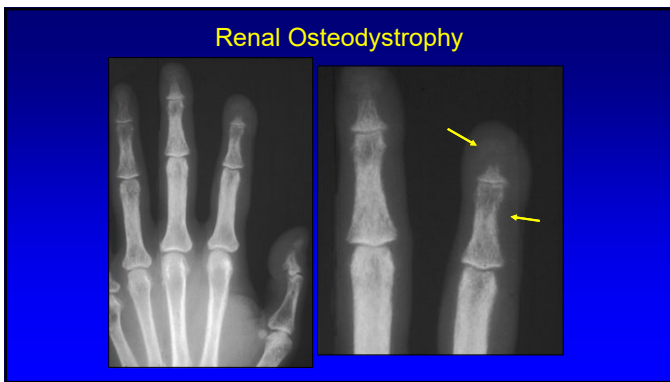78



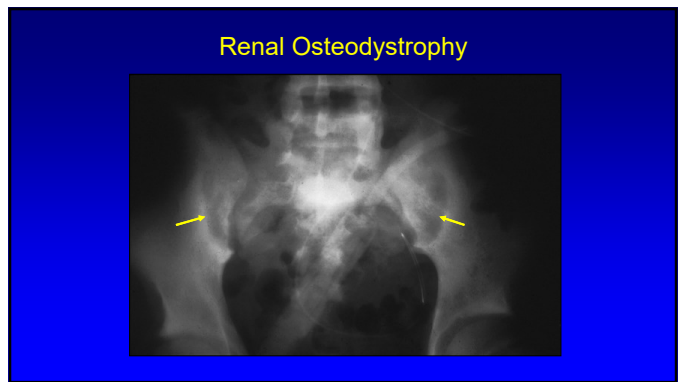
79



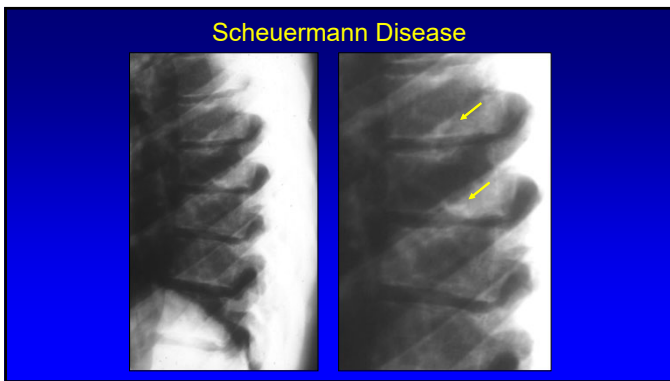
80



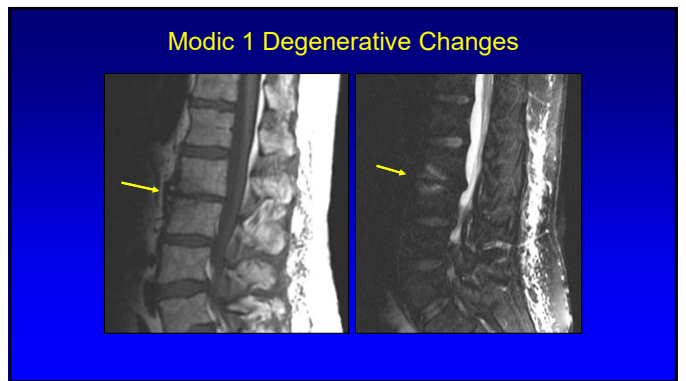
81



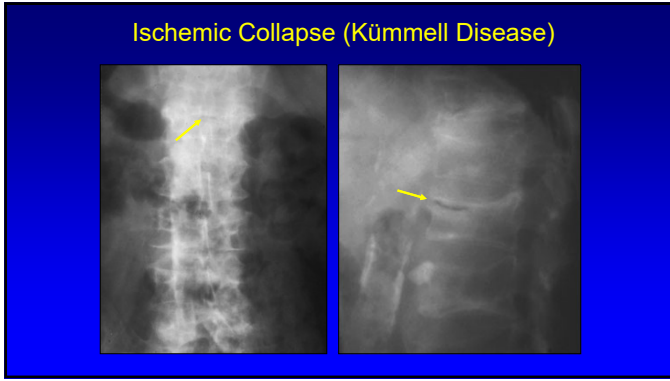
82



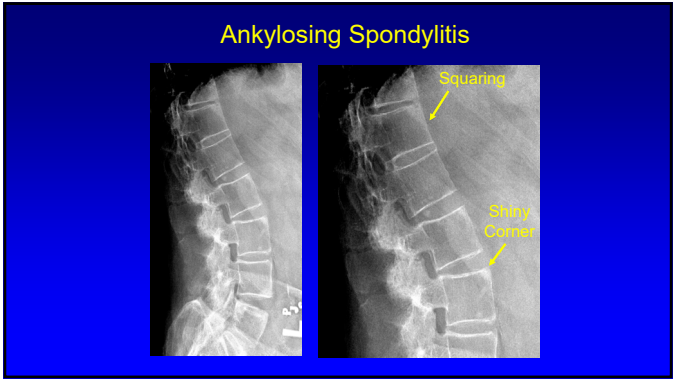
83



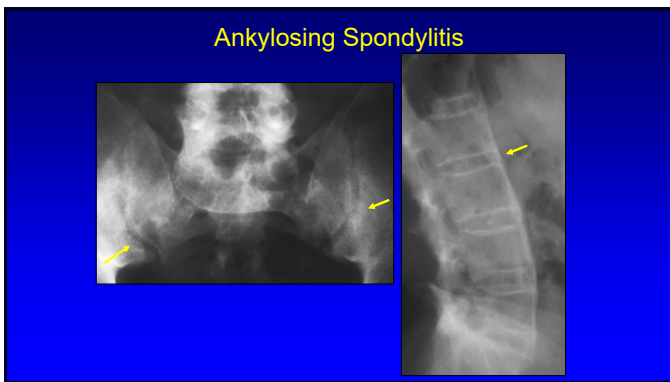
84



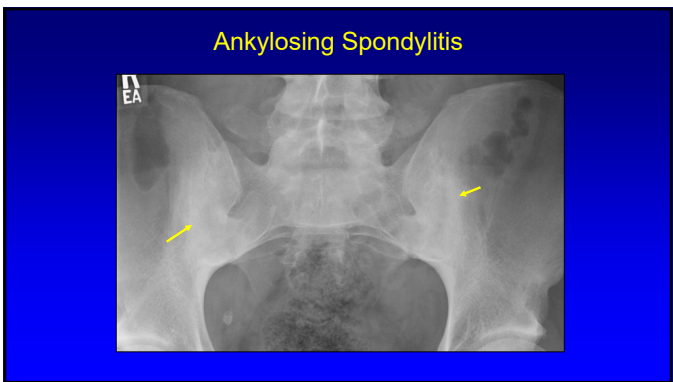
85



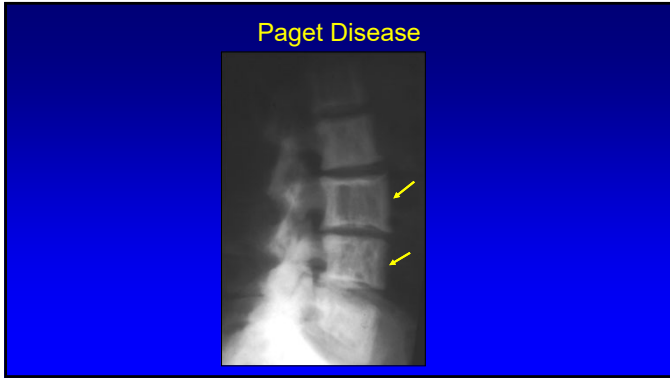
86



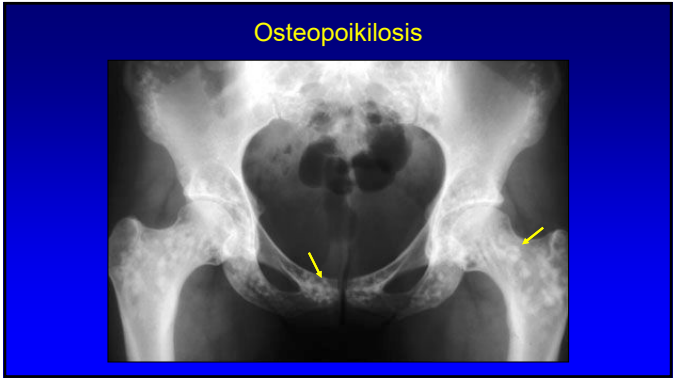
87



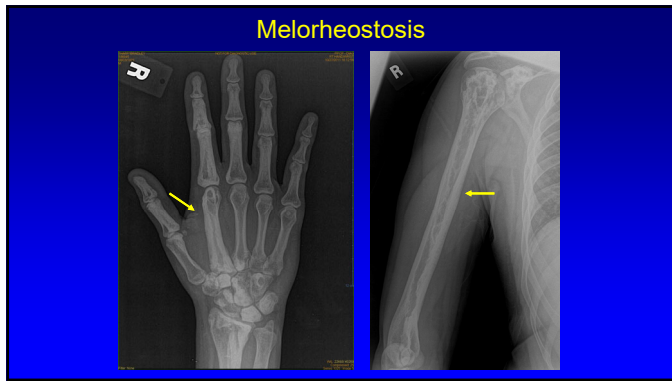
88



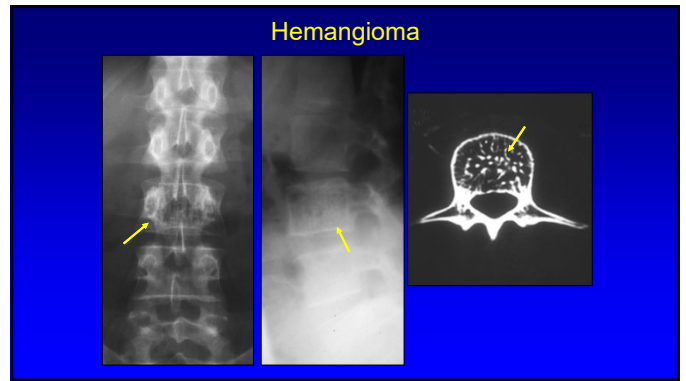
89



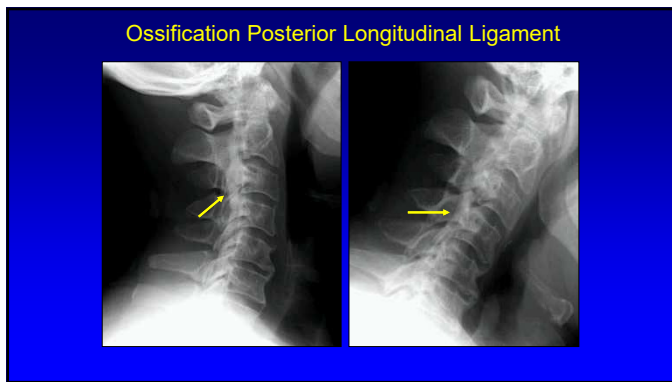
90



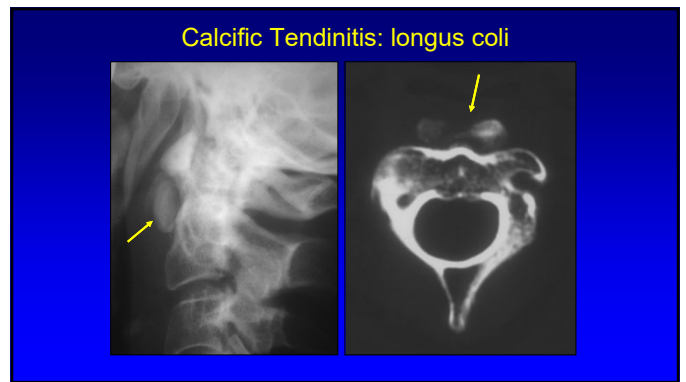
91



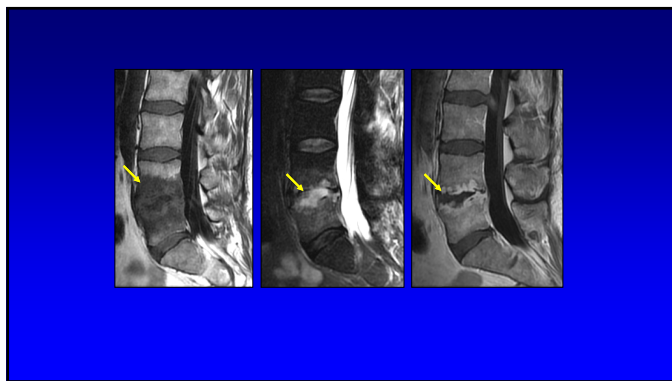
92



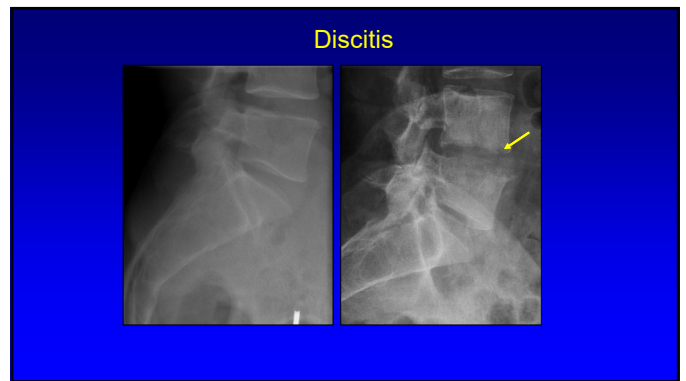
93



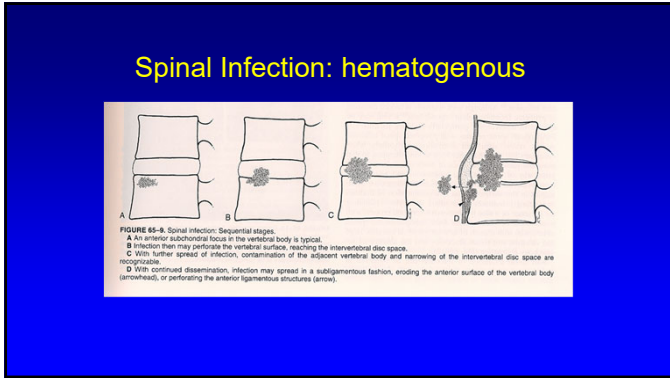
94



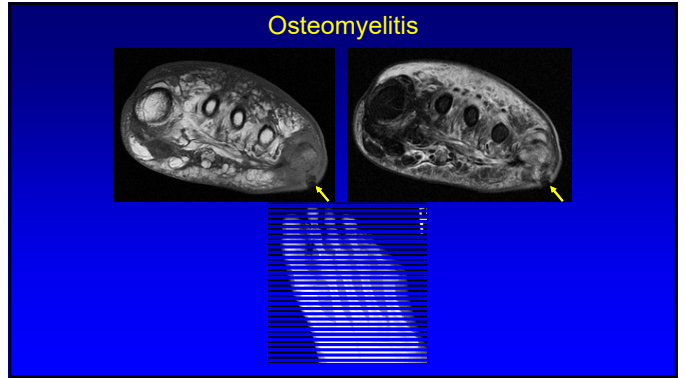
95



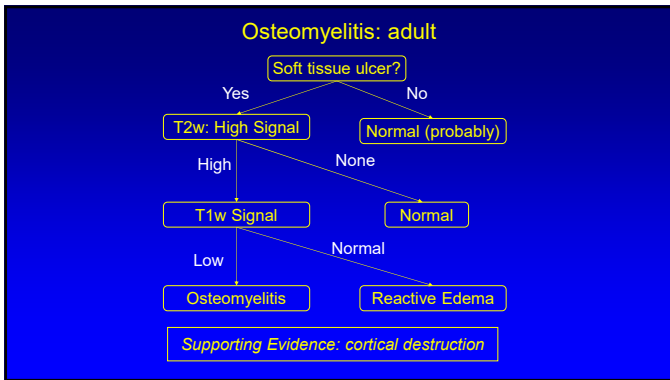
96



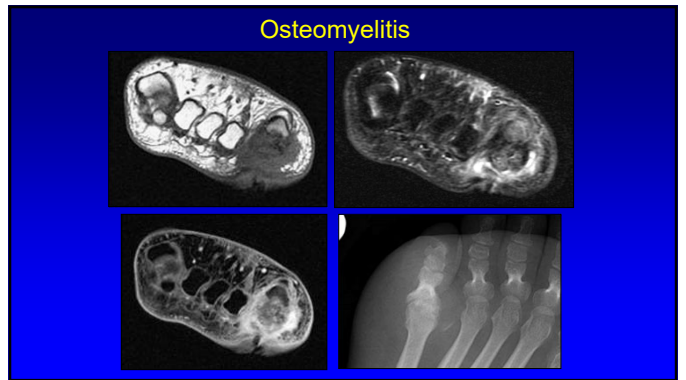
97



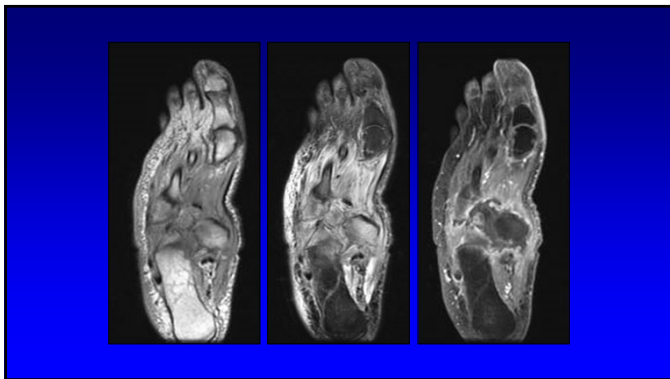
98



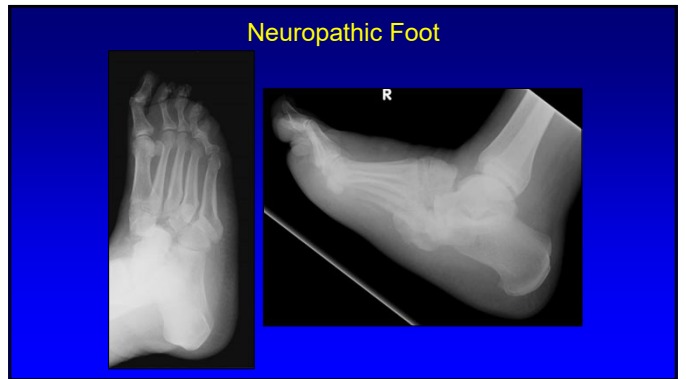
99



100



101



102

Thank you!

Syllabus on line and other educational material:
www.jacobsonmskus.com

Twitter handle: @jjacobsn

103