

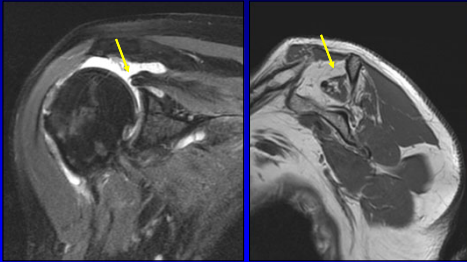
**Musculoskeletal Imaging
Case Conference**

Jon A. Jacobson, MD
FACR, FSRU, FAIUM, RMSK

*Musculoskeletal Radiologist
Lenox Hill Radiology, NYC*

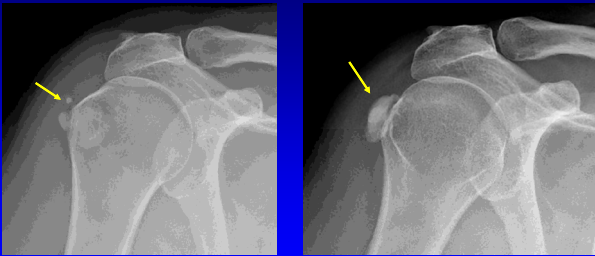
1

Full-thickness Tear: supraspinatus



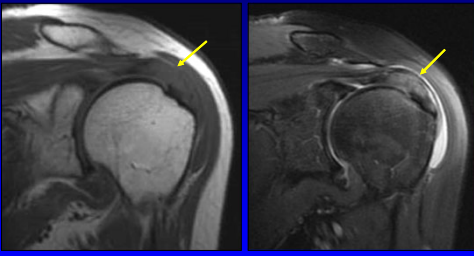
2

Calcium Hydroxyapatite Deposition



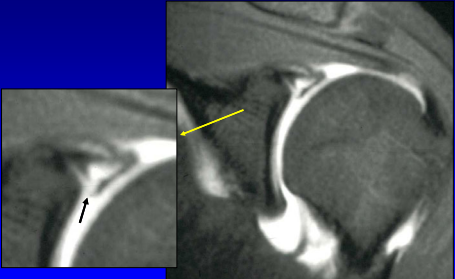
3

Tendinosis: supraspinatus



4


SLAP Tear: Type 2



Coronal-oblique T1w fat-sat

5

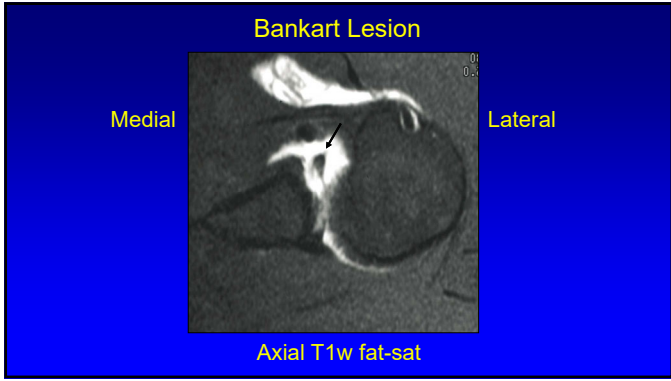
SLAP Tear: Type 2



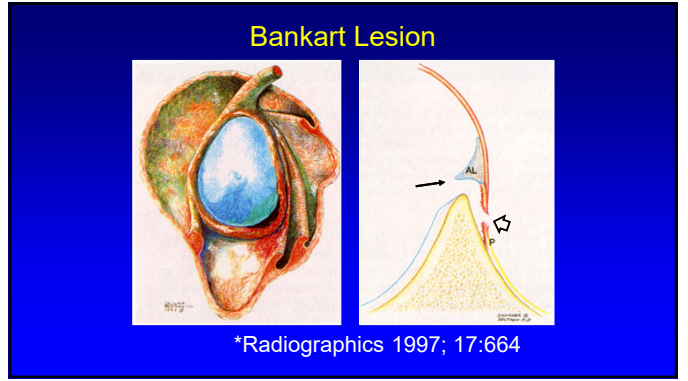
Posterior Anterior

*Radiographics 1997; 17:670

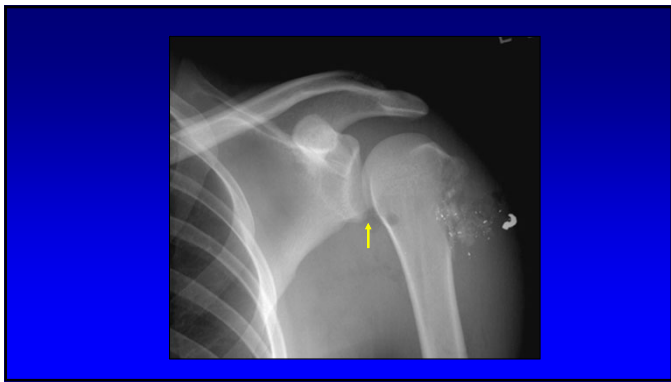
6



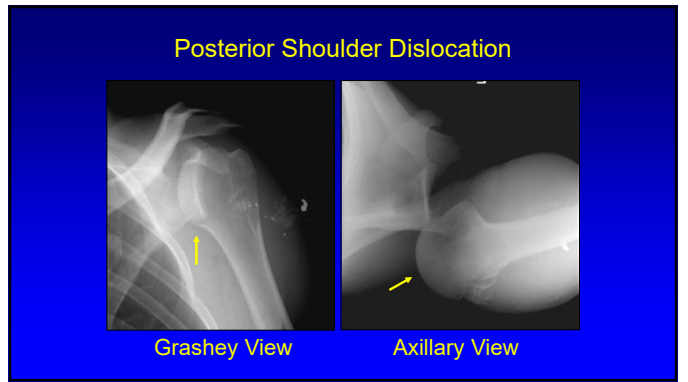
7



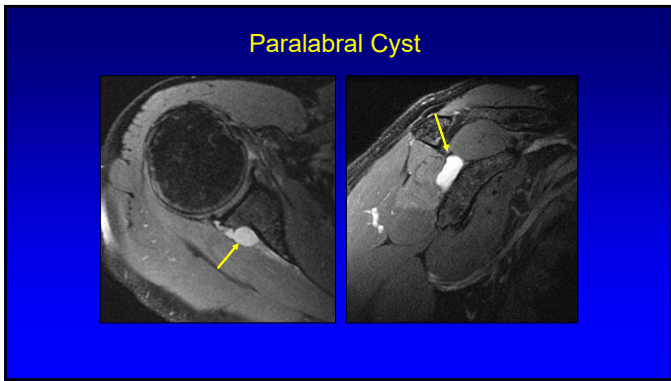
8



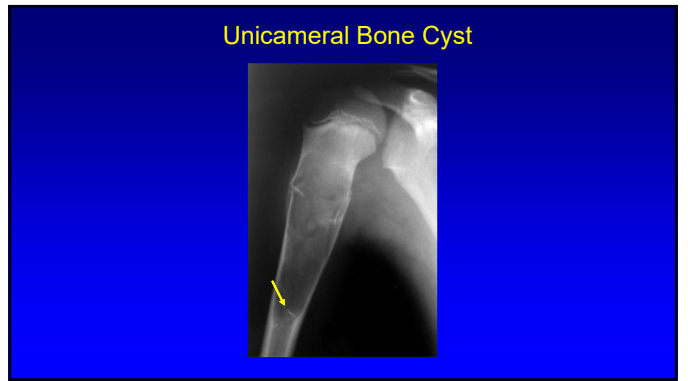
9



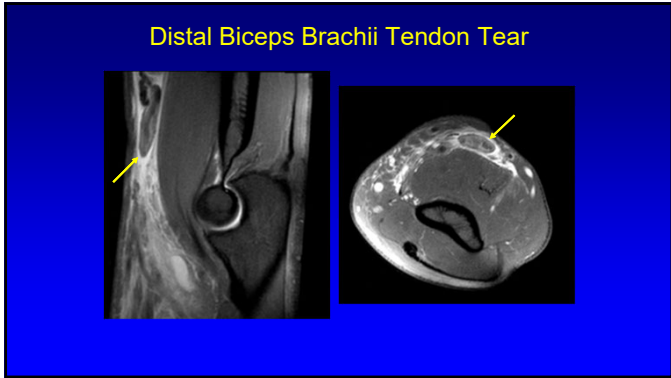
10



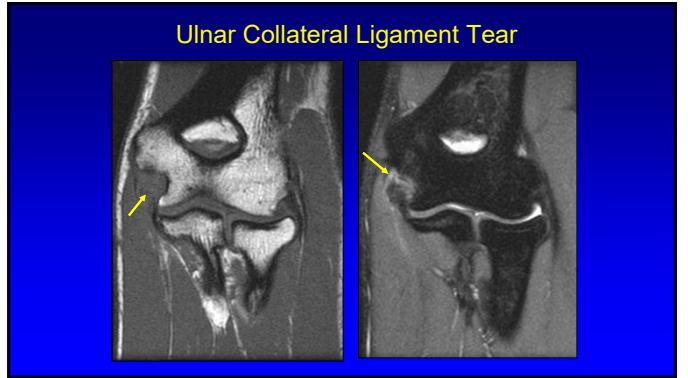
11



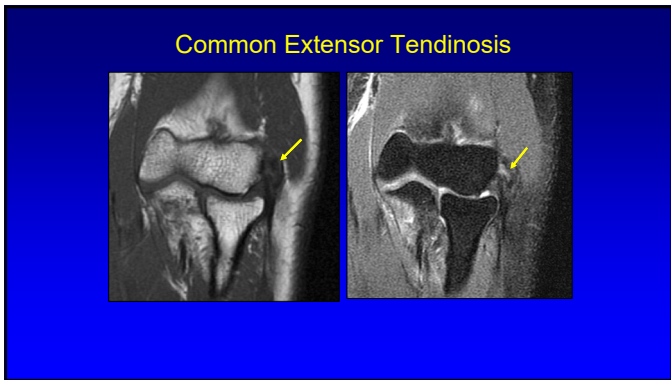
12



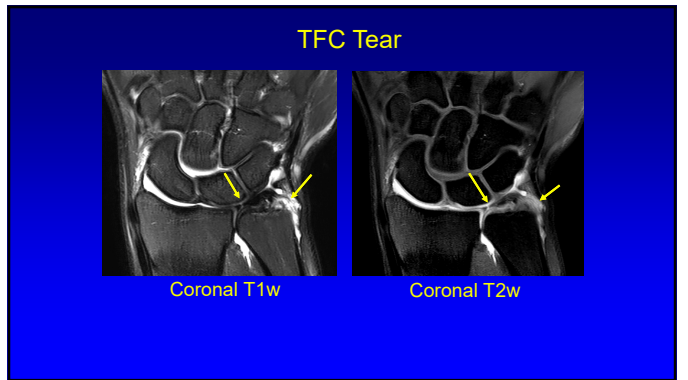
13



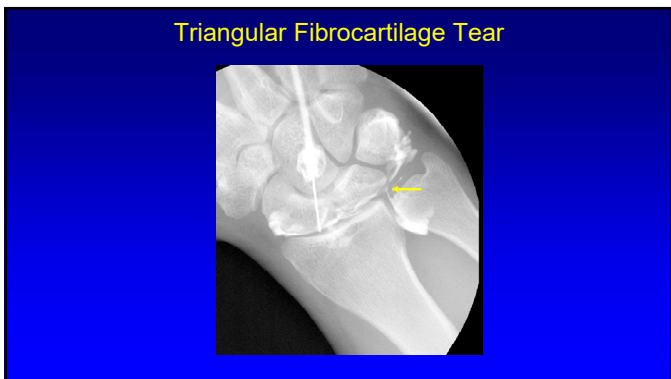
14



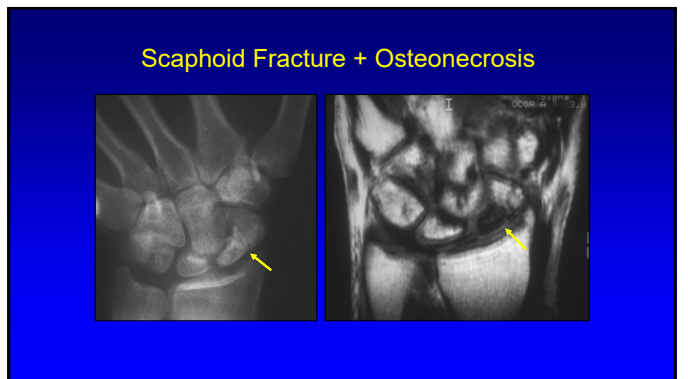
15



16

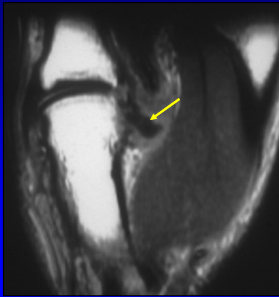


17



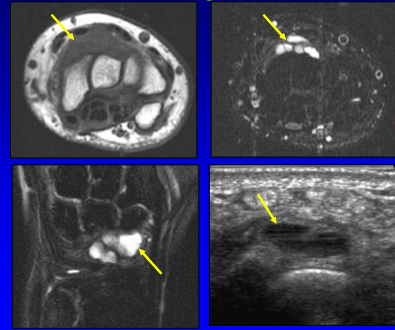
18

Gamekeeper's Thumb + Stener Lesion



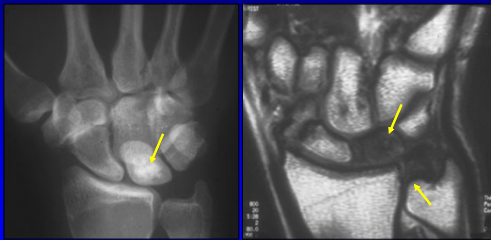
19

Ganglion



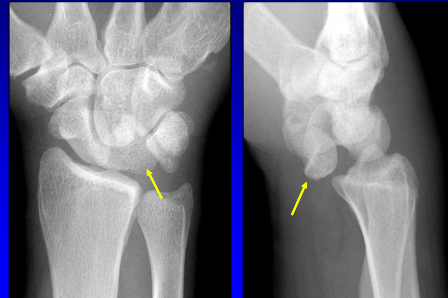
20

Kienböck Osteonecrosis

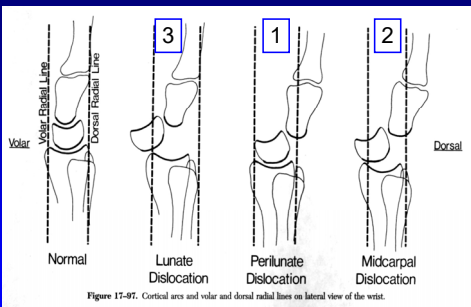


21

Lunate Dislocation

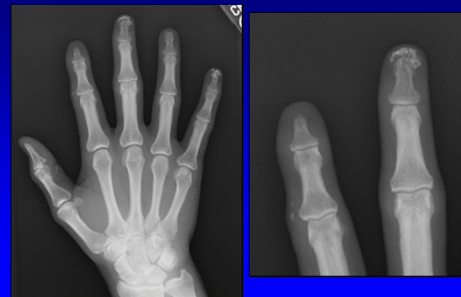


22

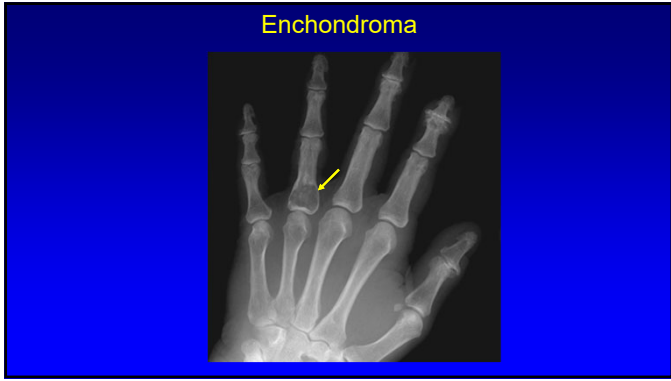


23

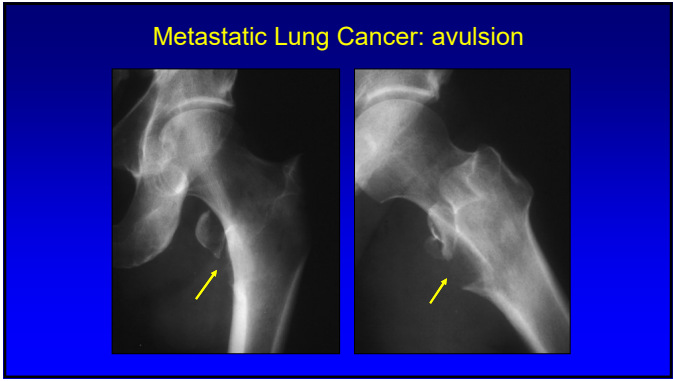
Scleroderma



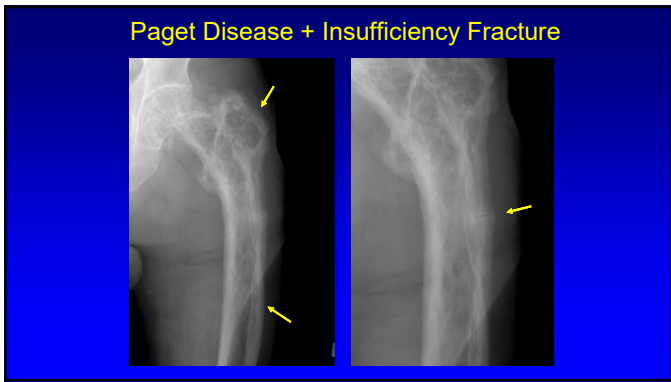
24



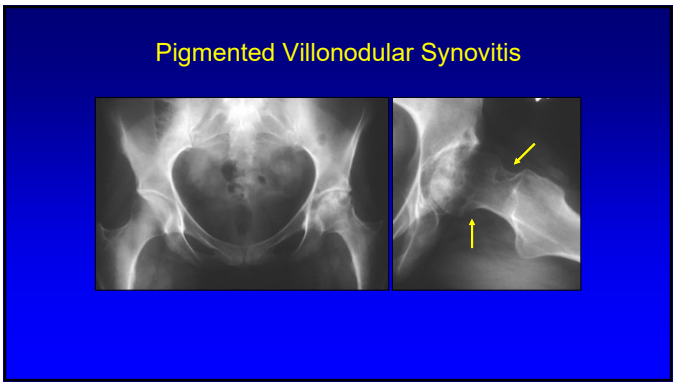
25



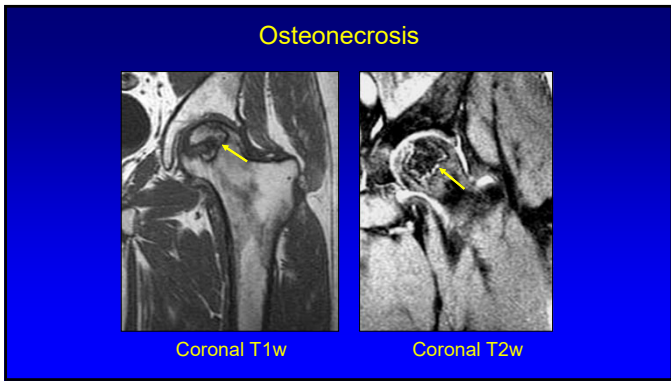
26



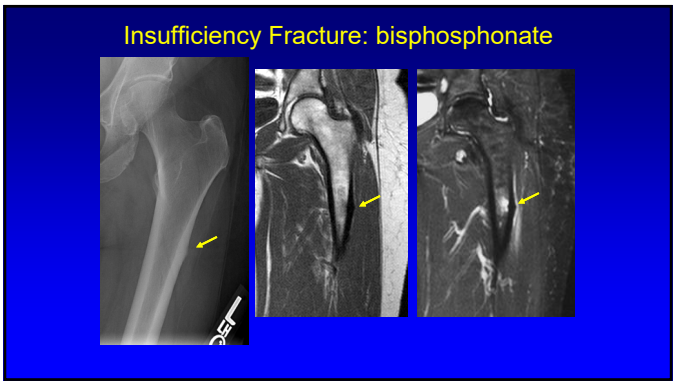
27



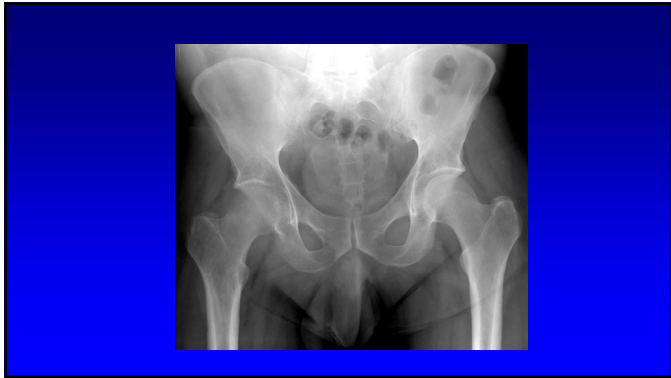28



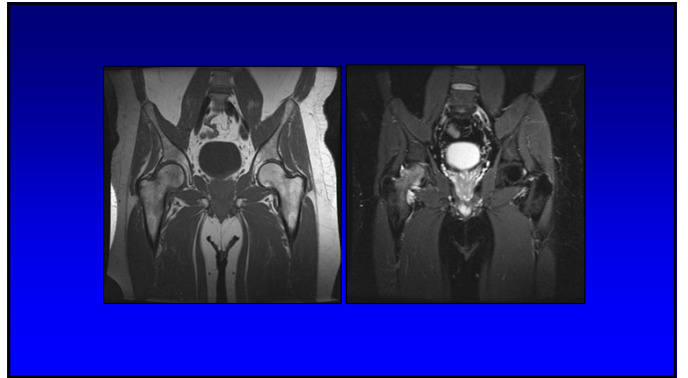
29



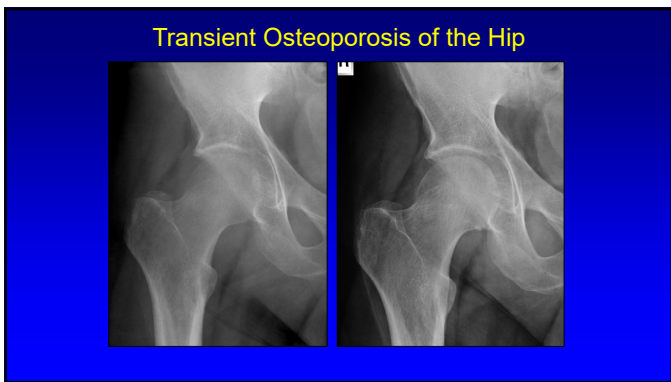
30



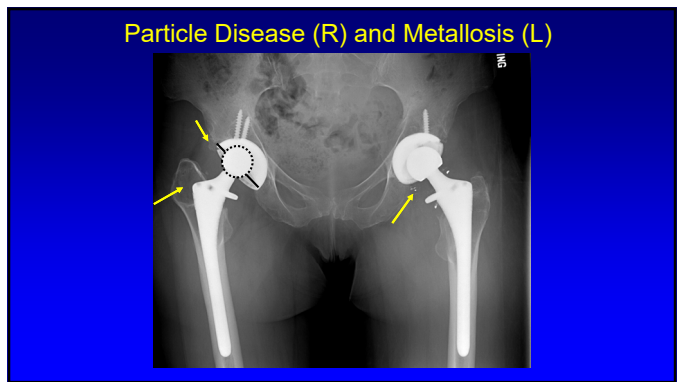
31



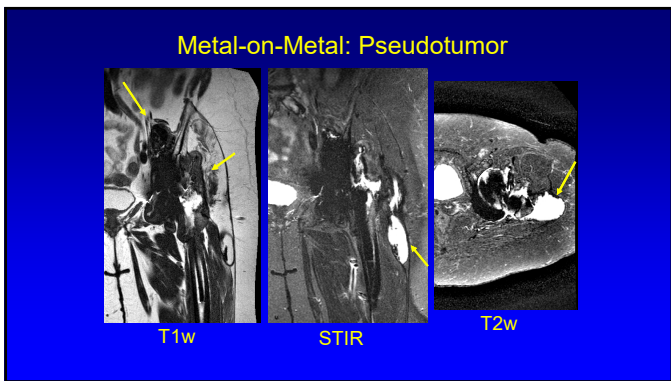
32



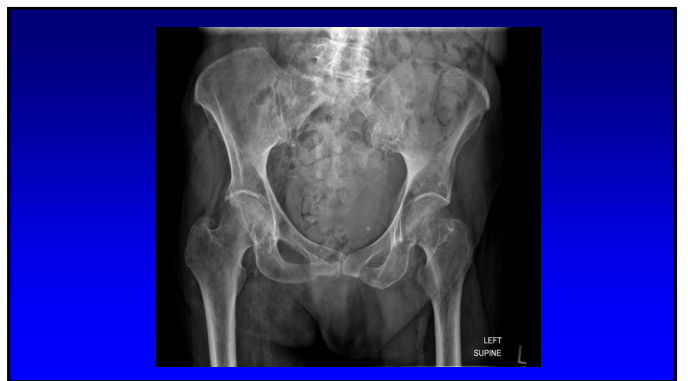33



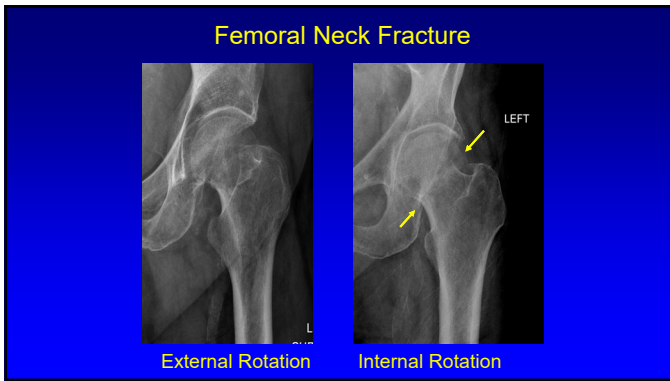
34



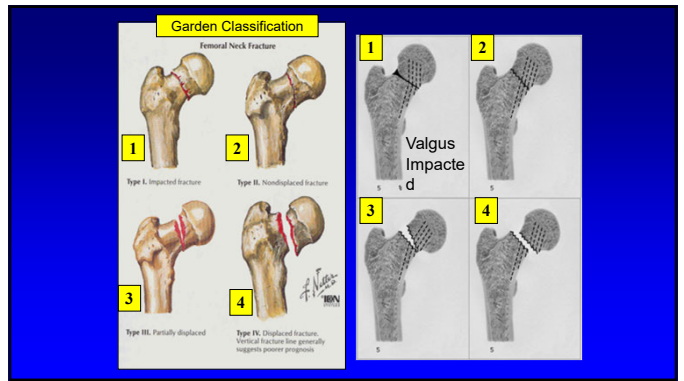
35



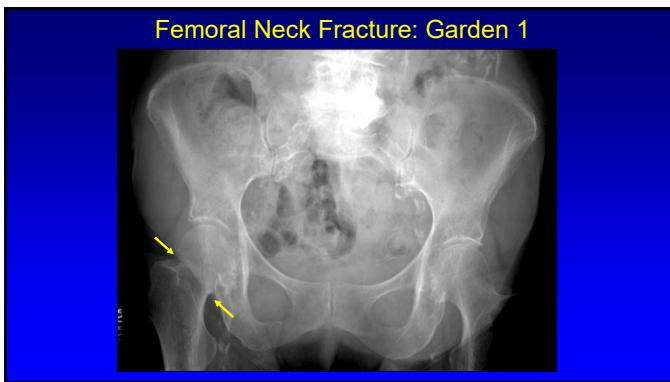
36



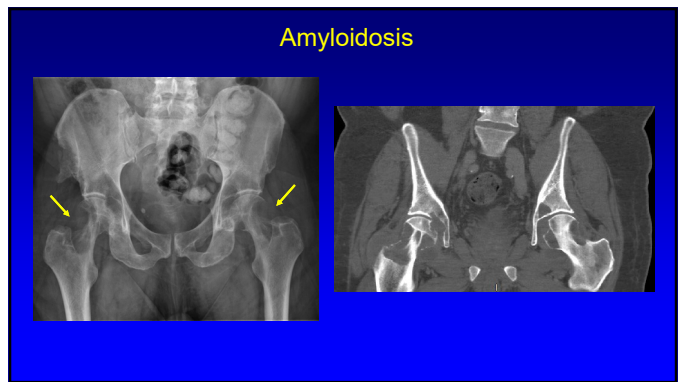
37



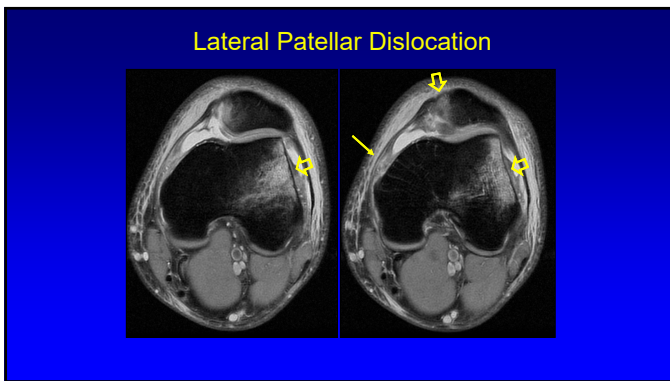
38



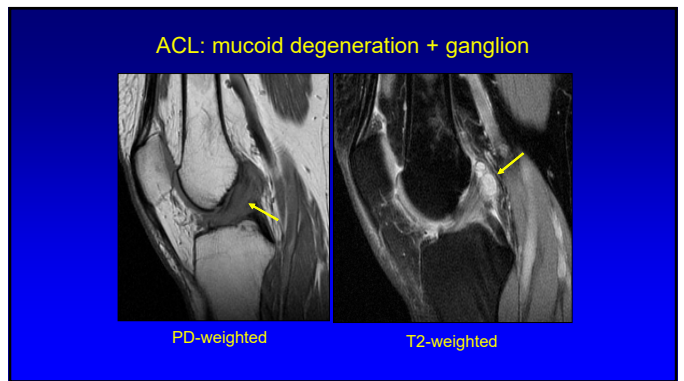
39



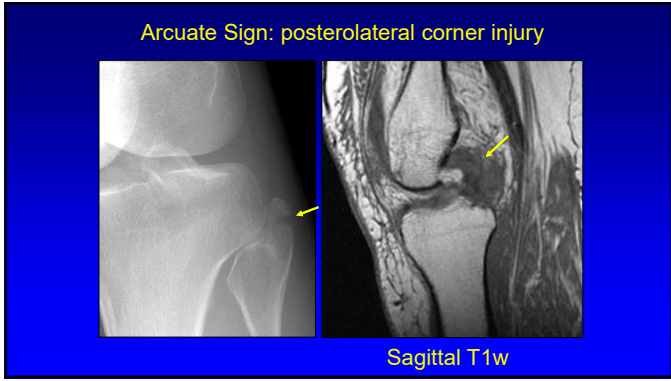
40



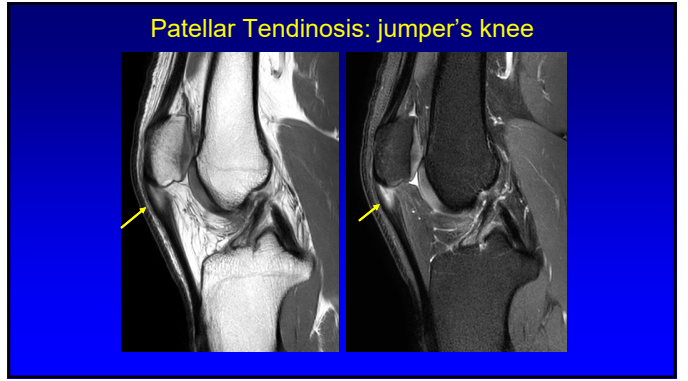
41



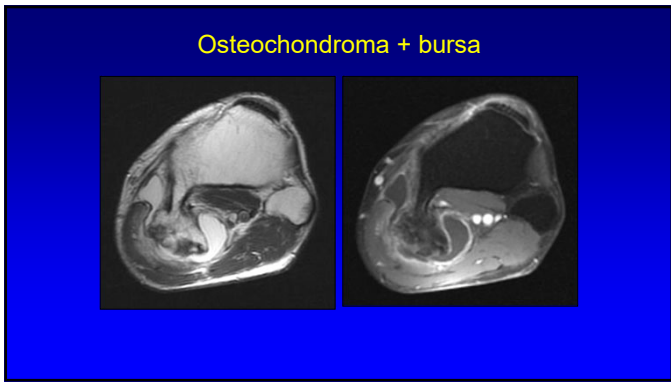
42



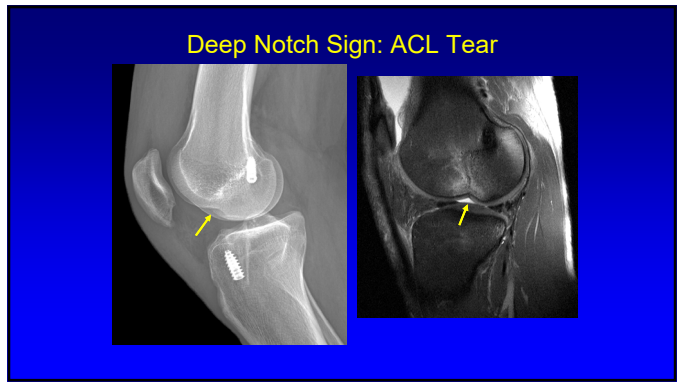
43



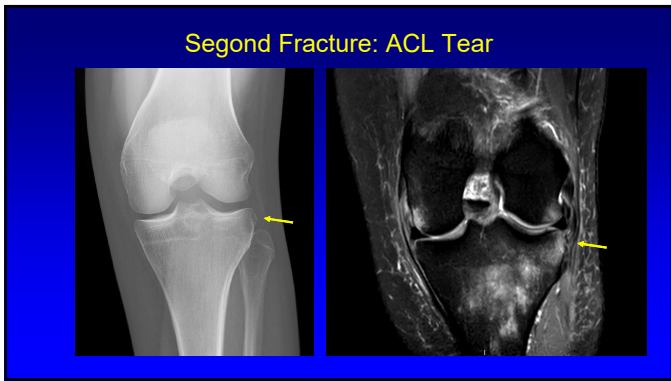
44



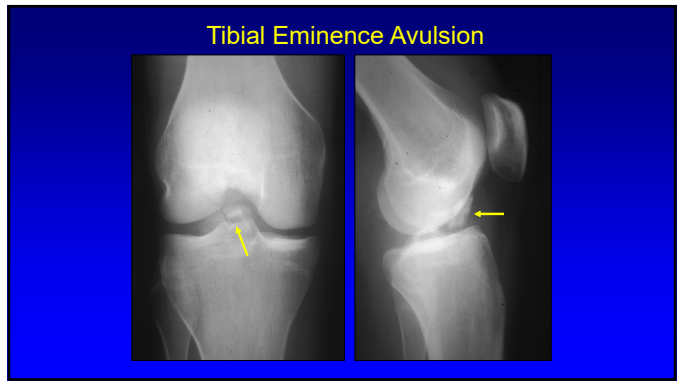
45



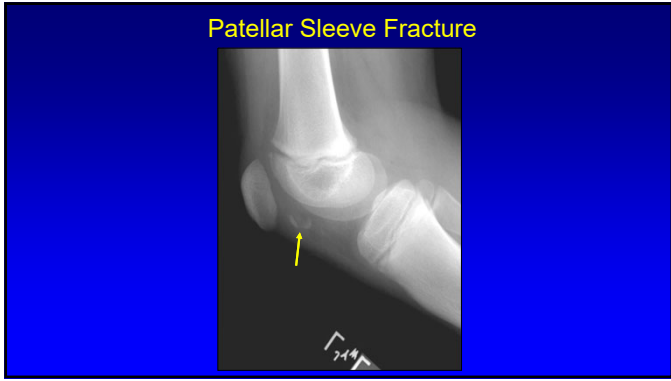
46



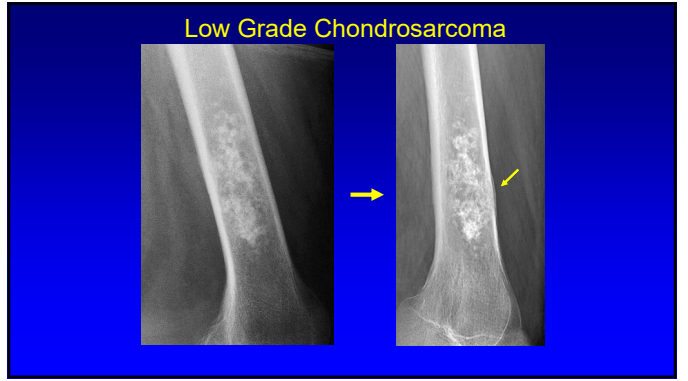
47



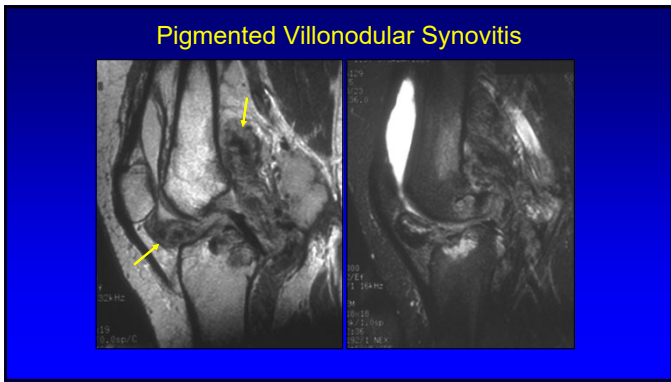
48



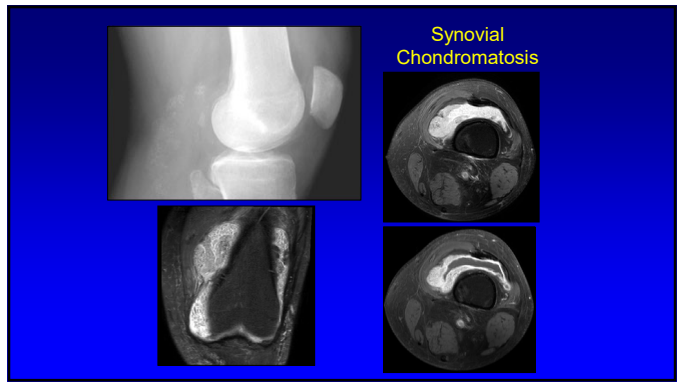
49



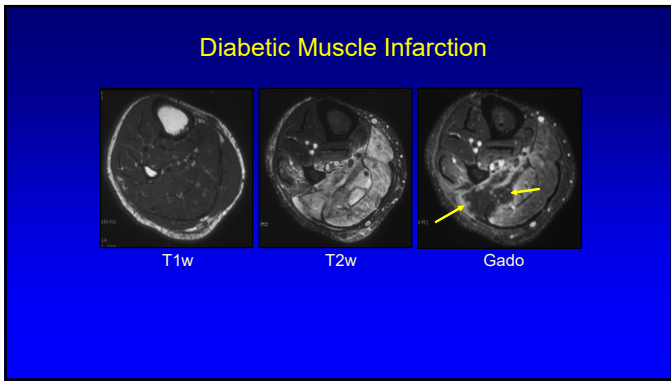
50



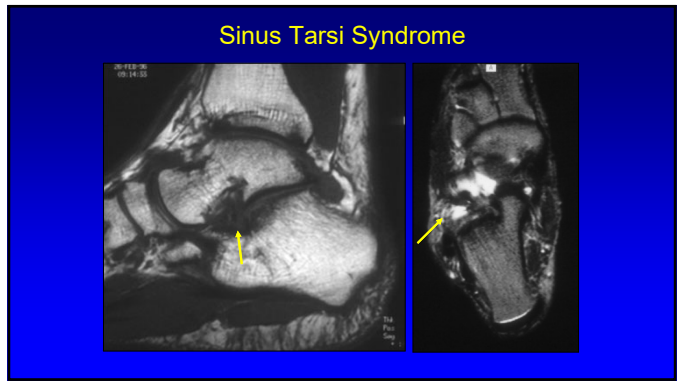
51



52

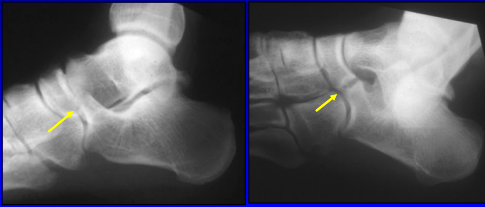


53



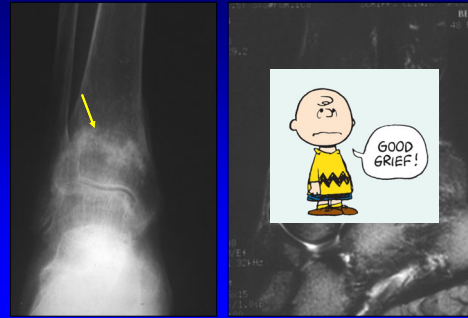
54

Coalition: calcaneonavicular



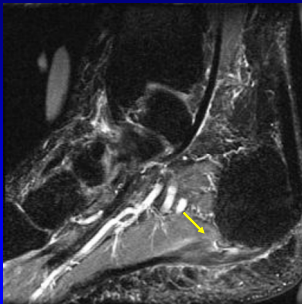
55

Insufficiency Fracture



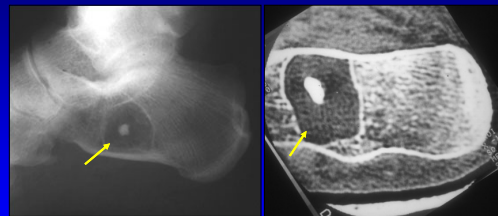
56

Plantar Fasciopathy



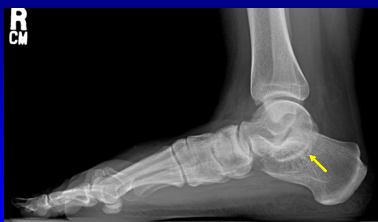57

Intra-osseous Lipoma



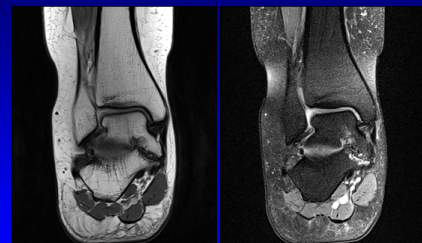58

Subtalar Coalition

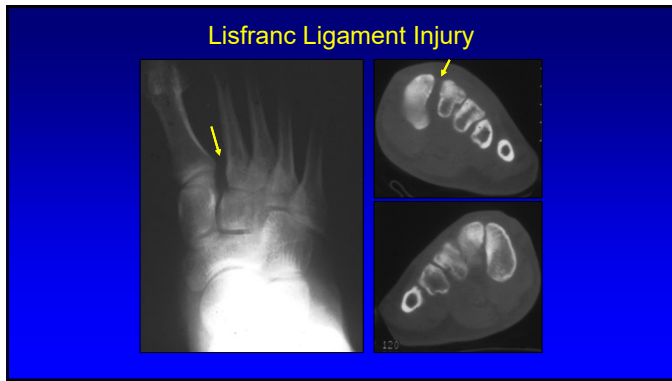


59

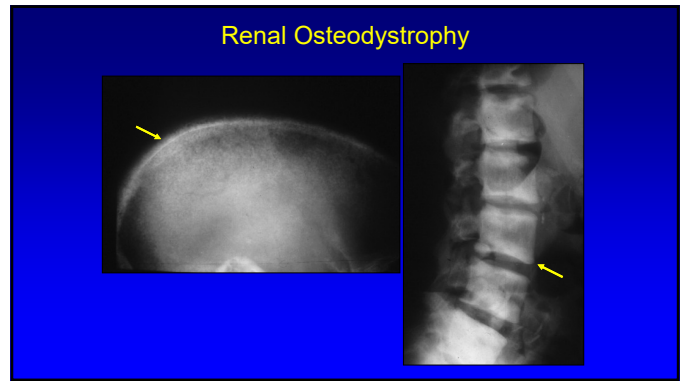
Subtalar Coalition



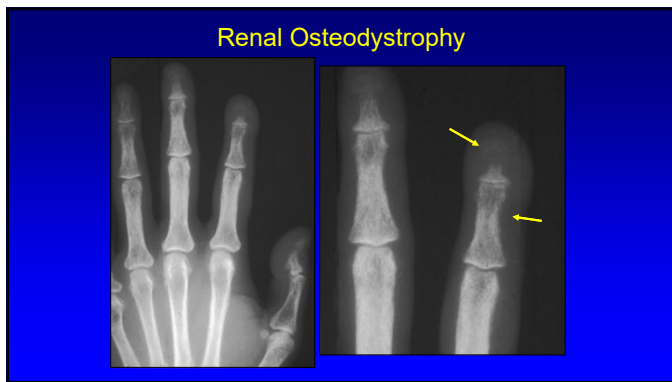
60



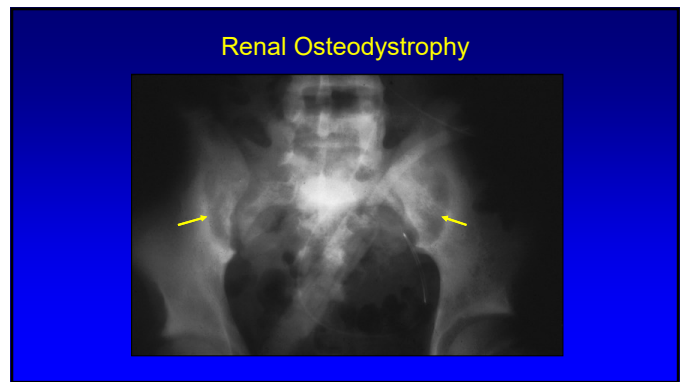
61



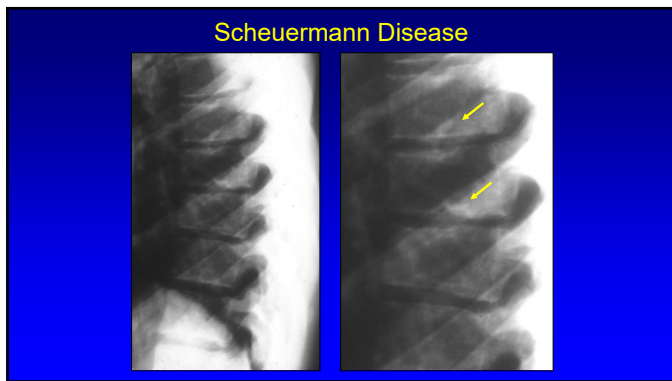
62



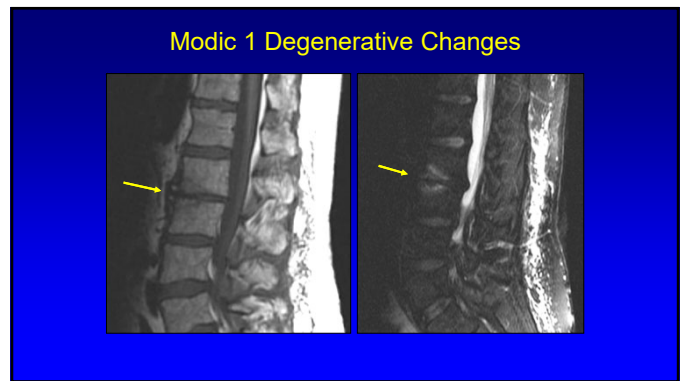
63



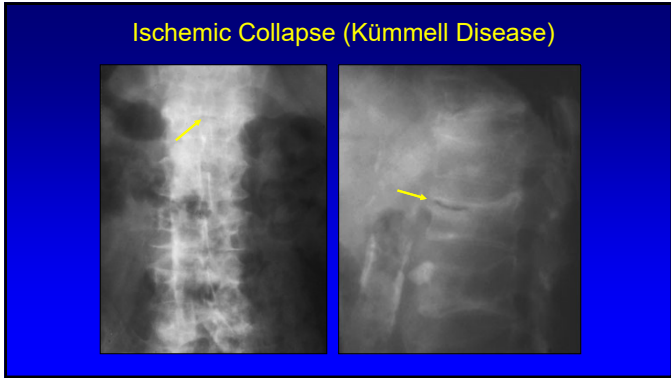
64



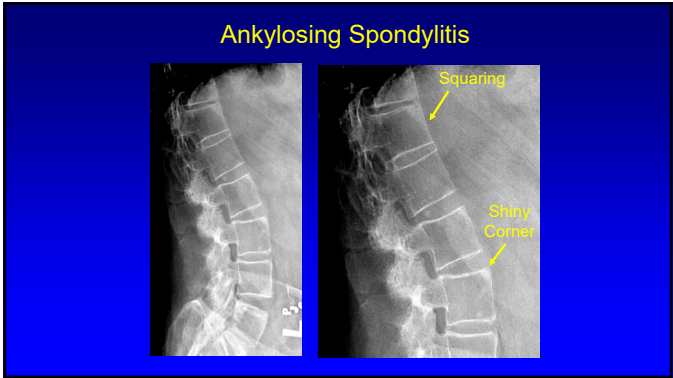
65



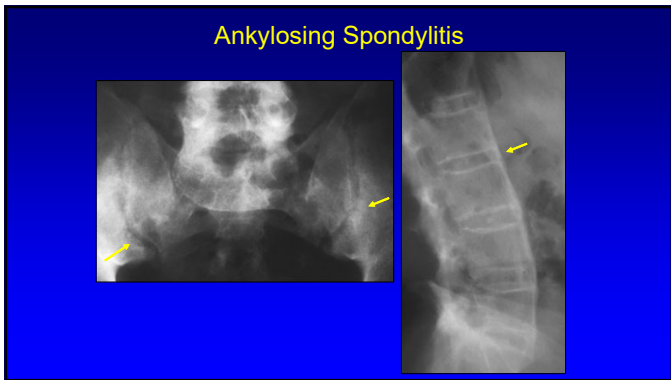
66



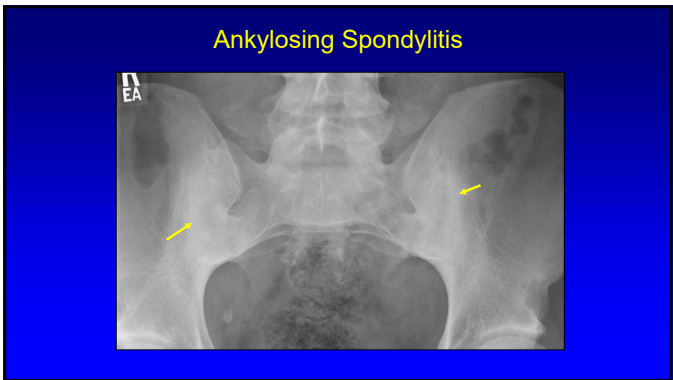
67



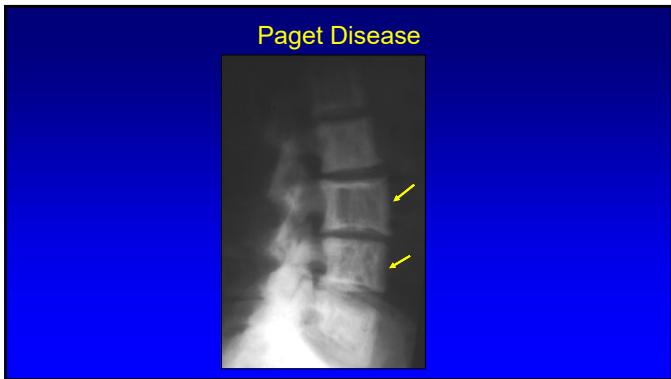
68



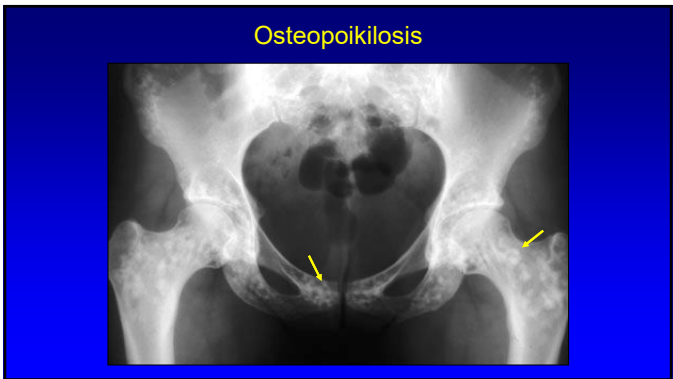
69



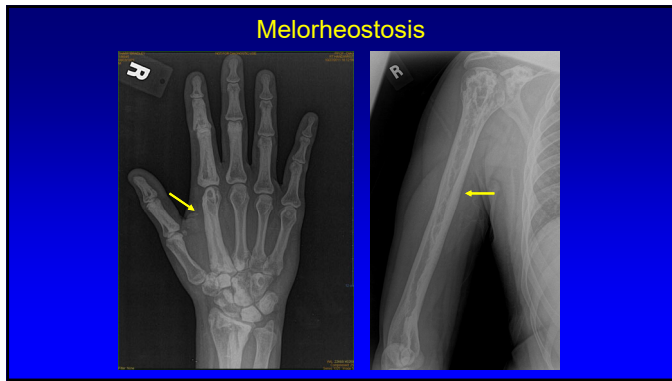
70



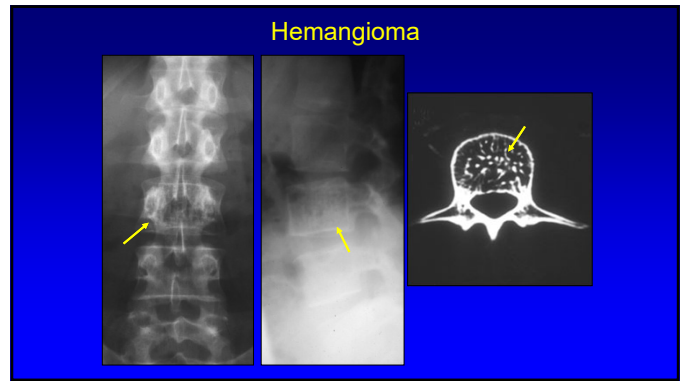
71



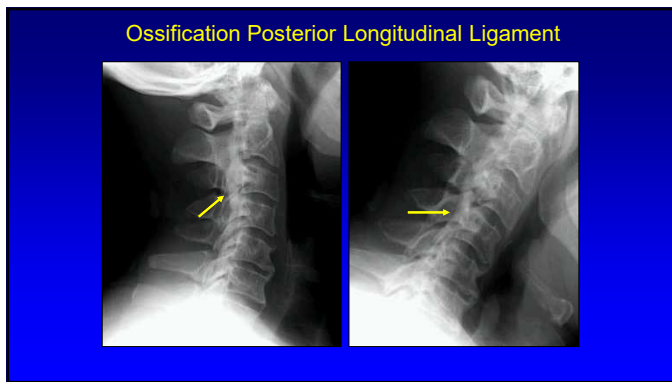
72



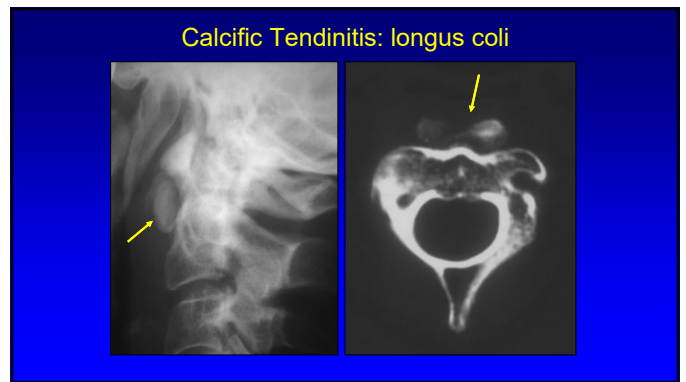
73



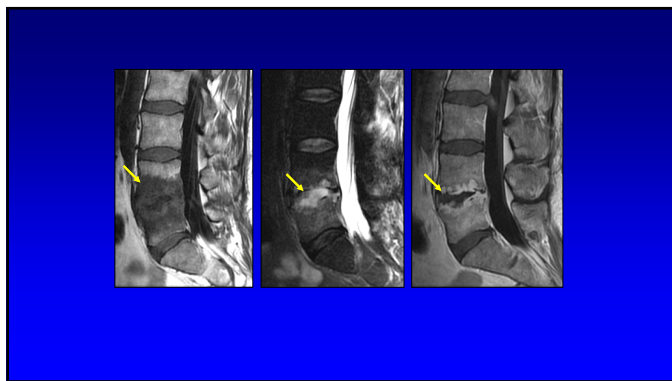
74



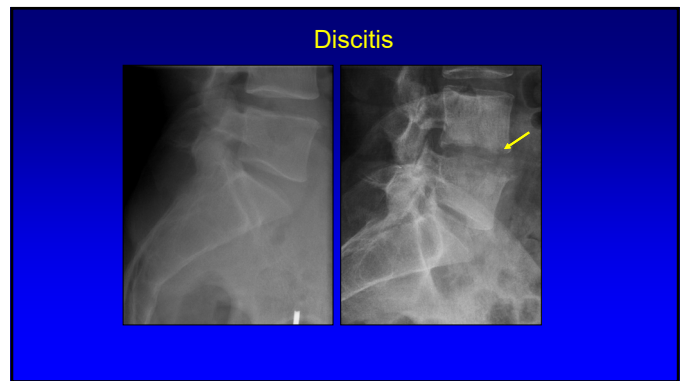
75



76

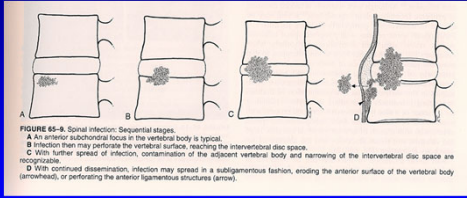


77



78

Spinal Infection: hematogenous



79

Thank you!

Syllabus on line and other educational material:
www.jacobsonmskus.com

Twitter handle: @jjacobsn

80