

Musculoskeletal Case Conference

Jon A. Jacobson, MD
FACR, FSRU, FAIUM, RMSK

*Professor of Radiology
Lenox Hill Radiology, NYC
University of California, San Diego*

1

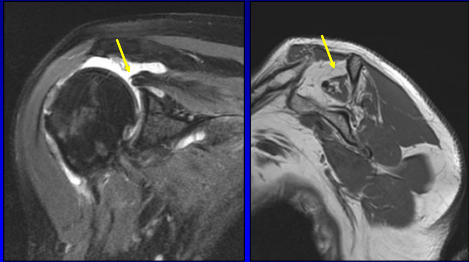
Disclosures

- Book Royalties: Elsevier
- Consultant: Bioclinica
- Advisory Board: Philips
- Contractor: POCUSPRO
- Not relevant to this talk

Syllabus on line and other educational material:
www.jacobsonmskus.com

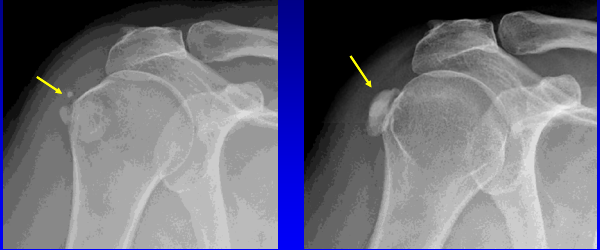
2

Full-thickness Tear: supraspinatus



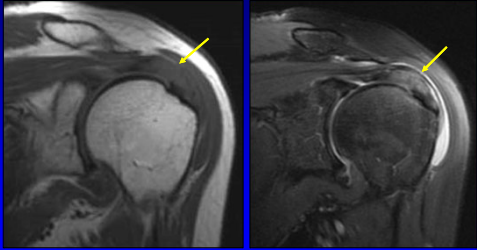
3

Calcium Hydroxyapatite Deposition




4

Tendinosis: supraspinatus



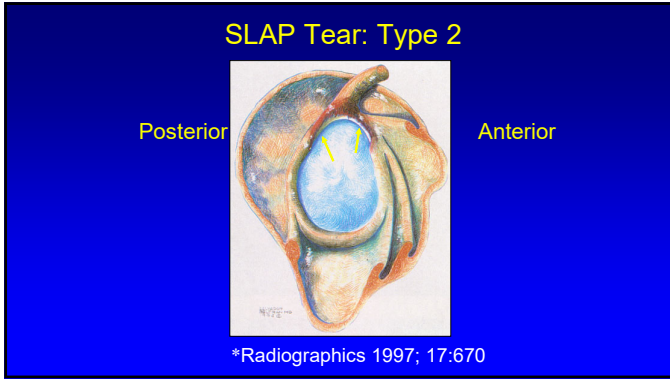
5

SLAP Tear: Type 2

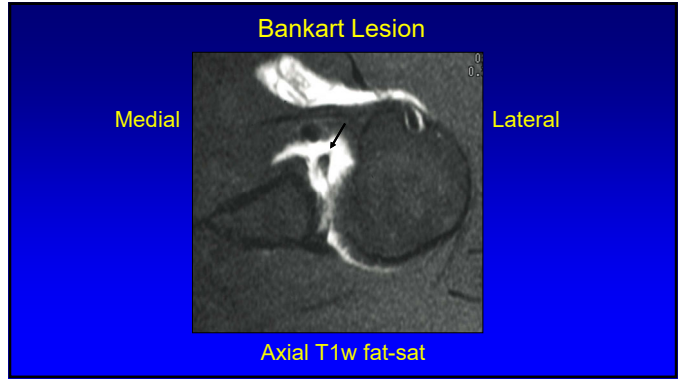


Coronal-oblique T1w fat-sat

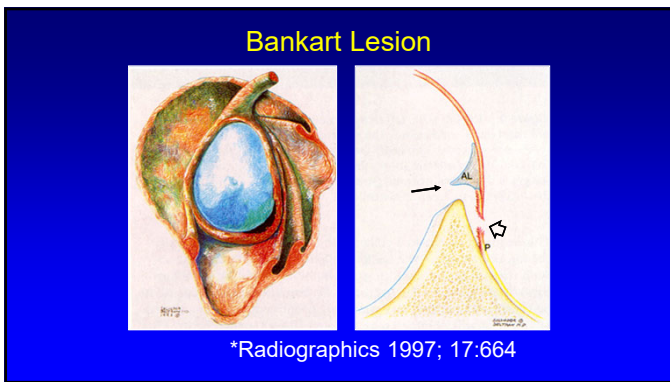
8



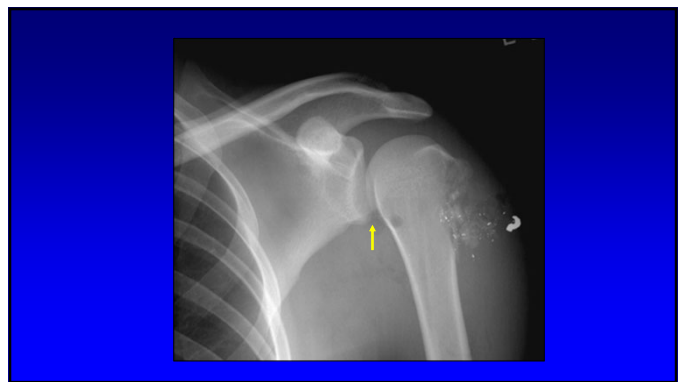
9



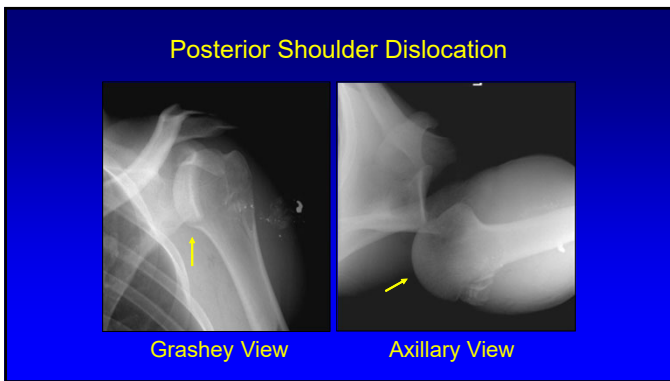
16



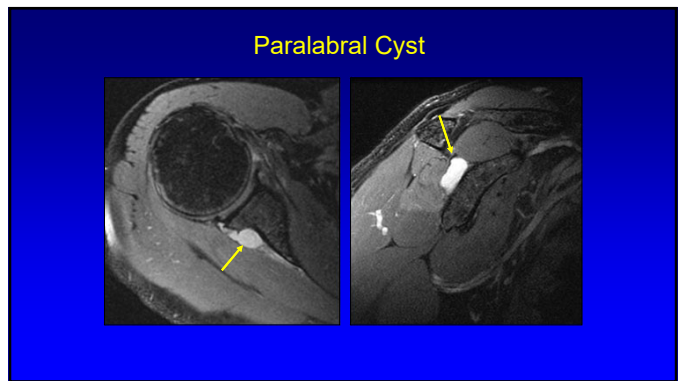
17



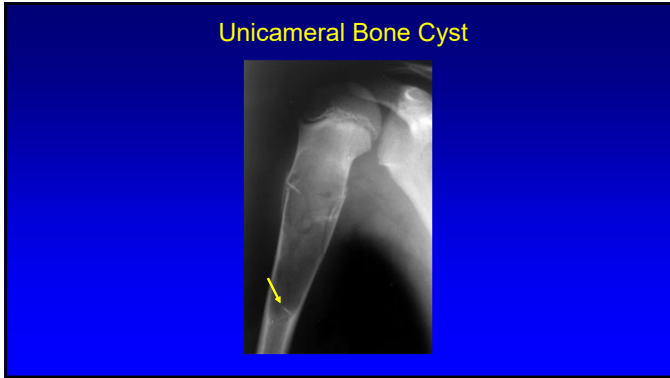
18



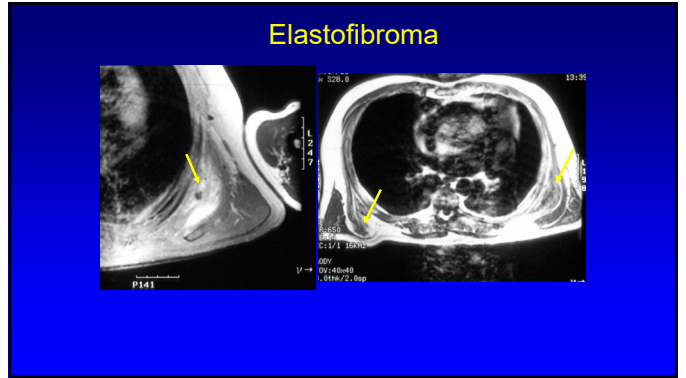
19



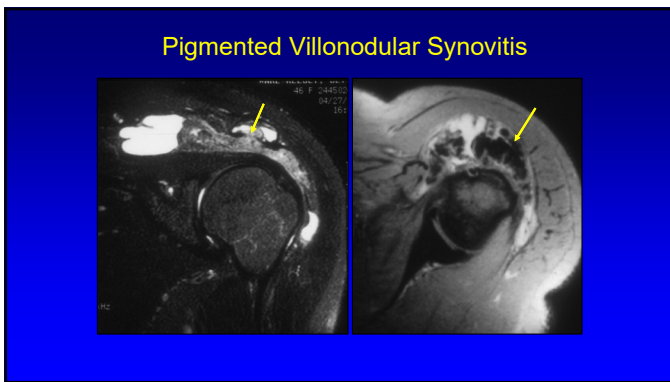
22



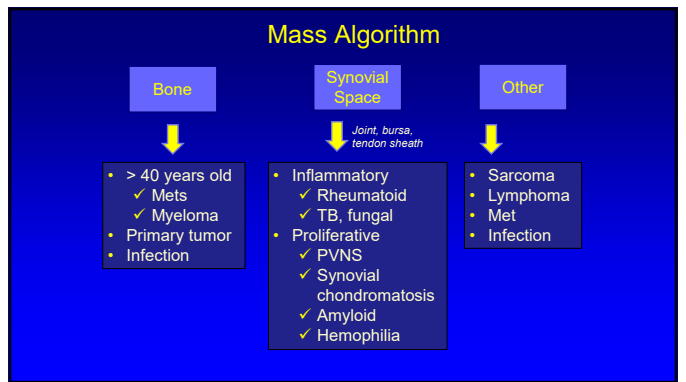
25



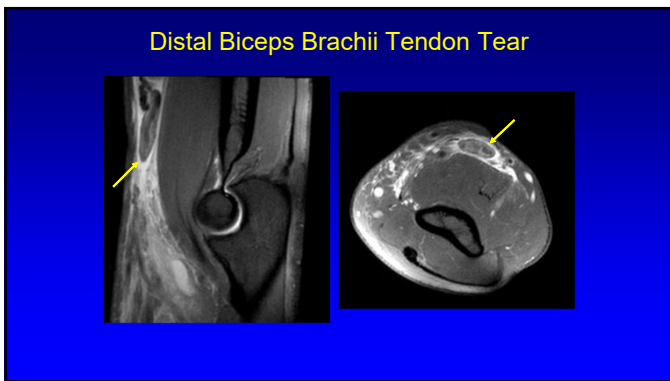
26



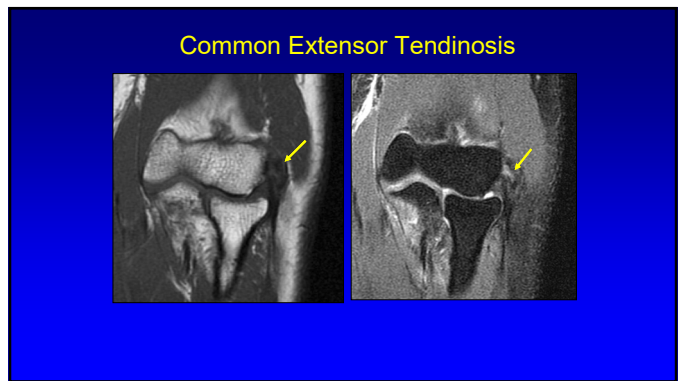
28



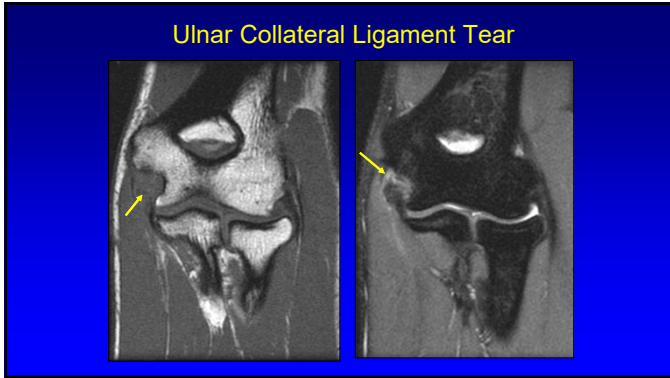
29



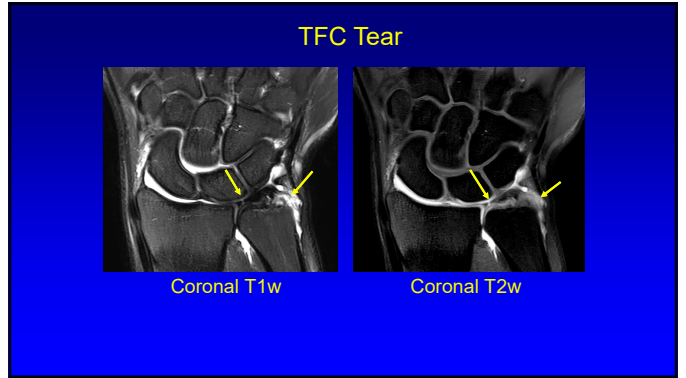
31



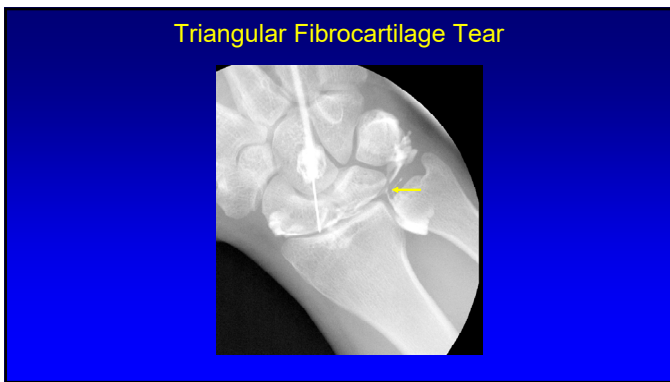
33



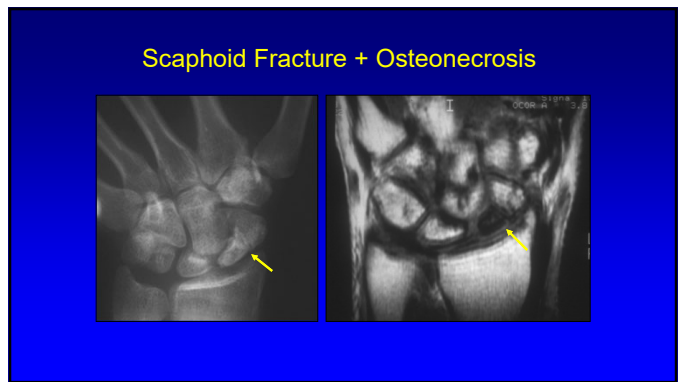
36



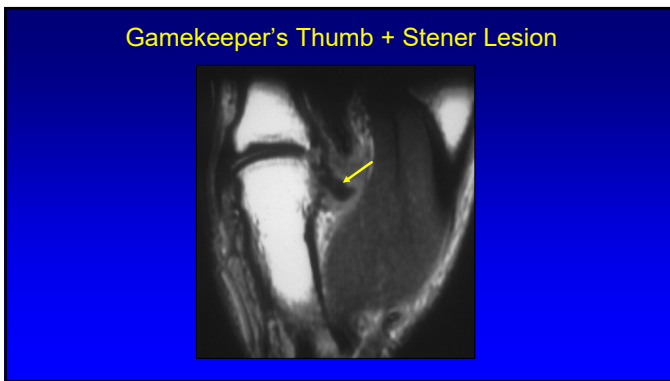37



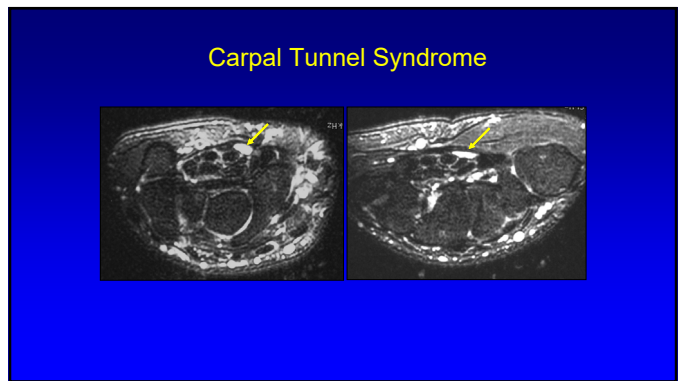
38



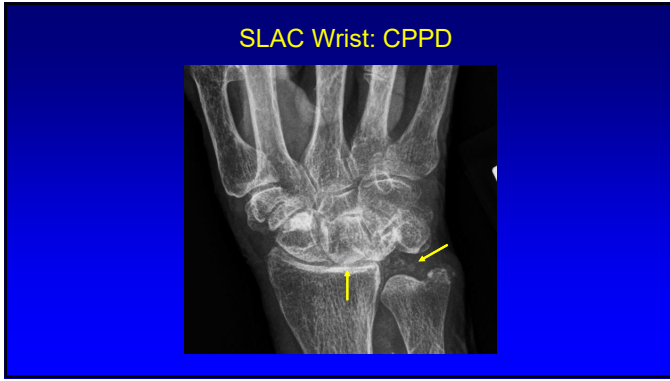45



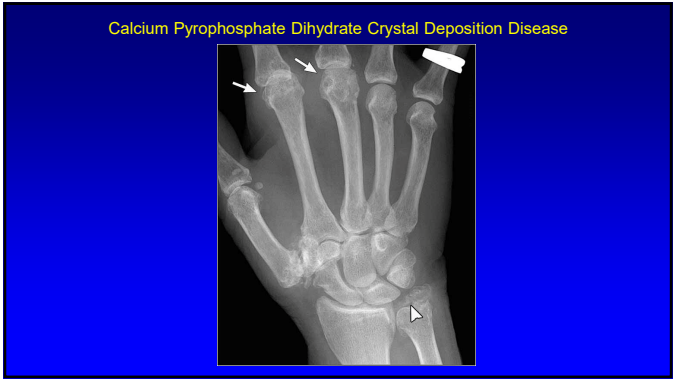46



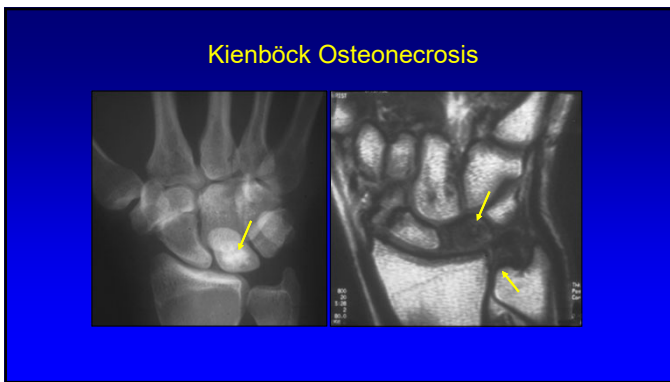
47



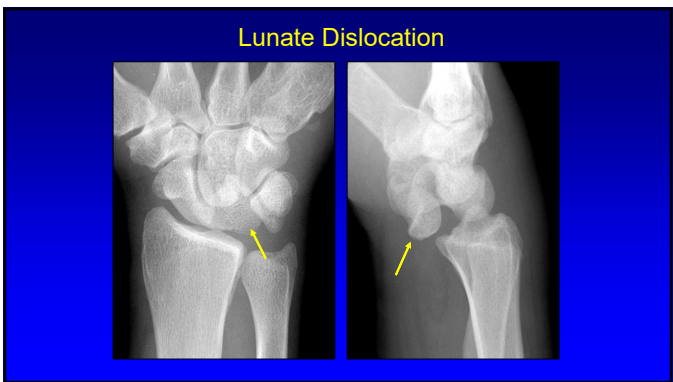
48



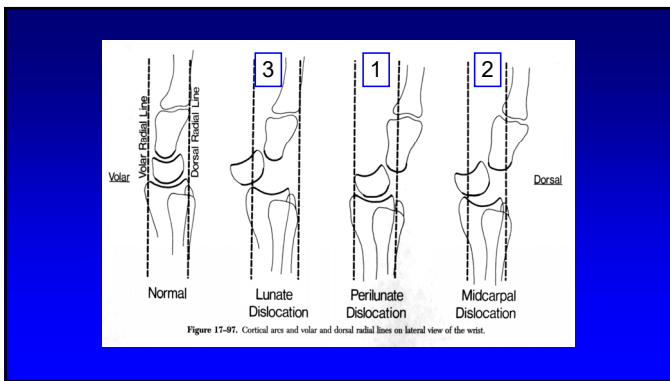
49



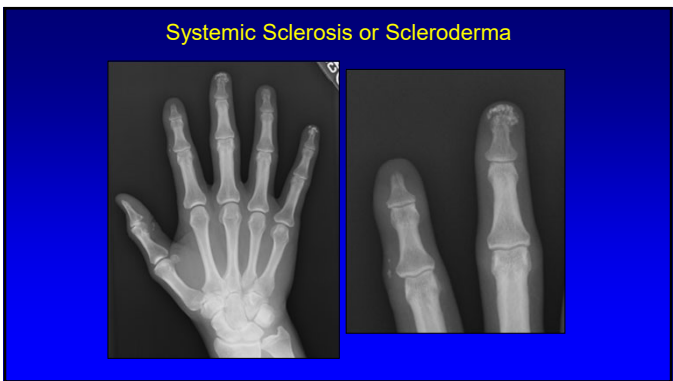55



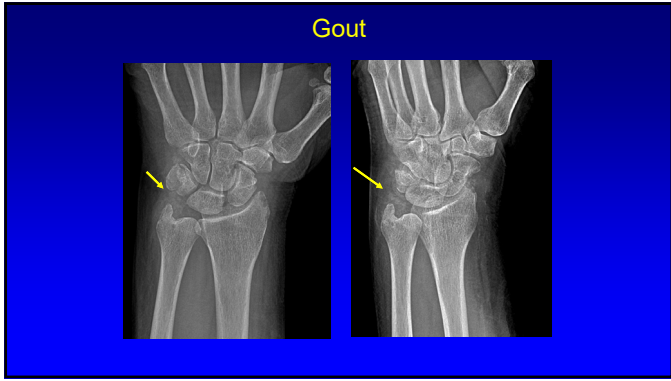
57



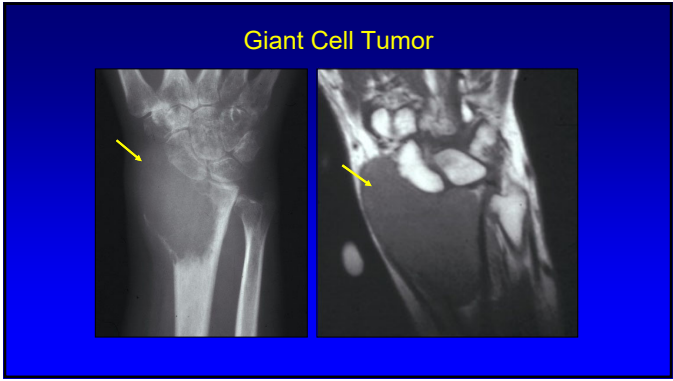
58



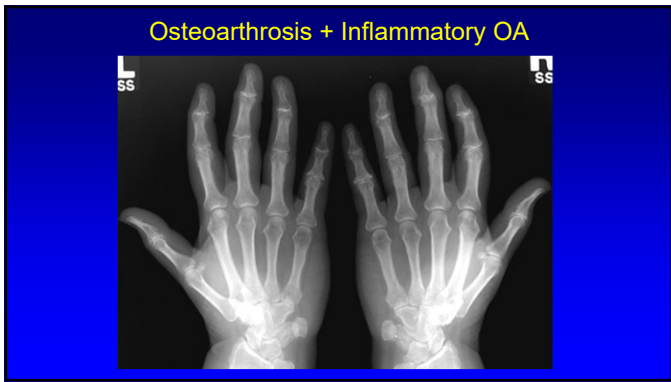59



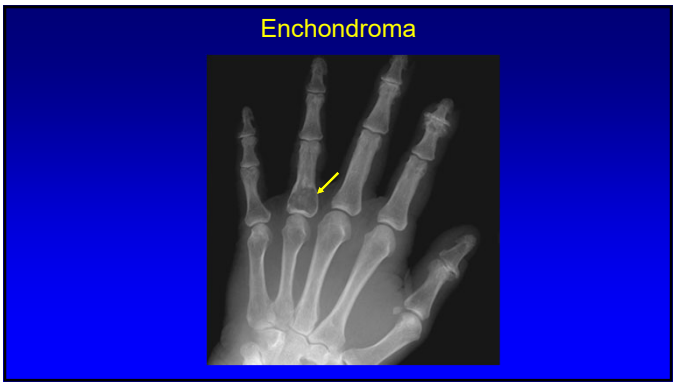62



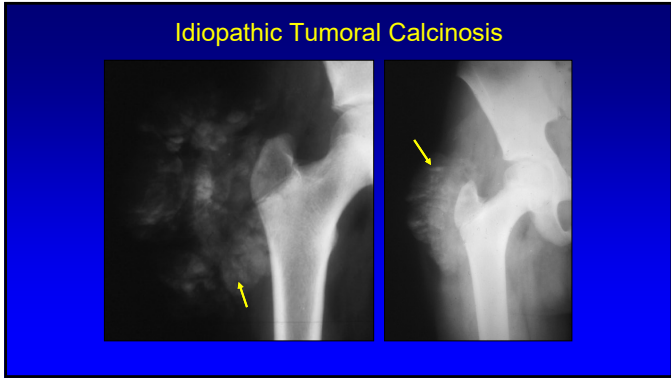
63



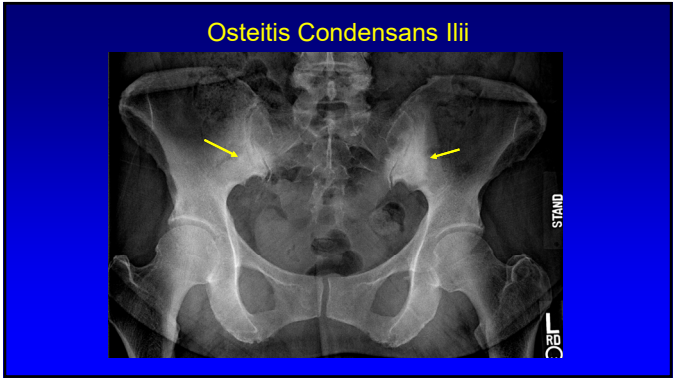
65



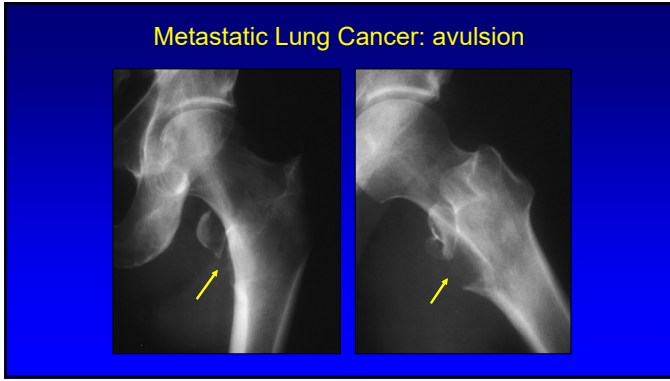
67



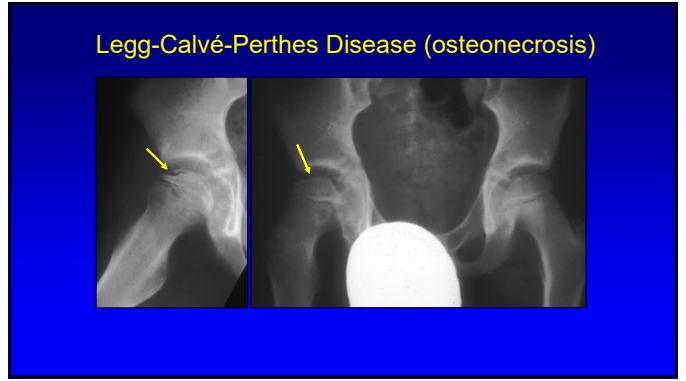
76



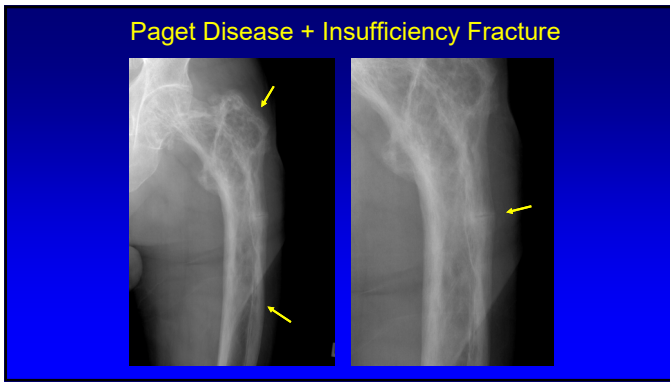
78



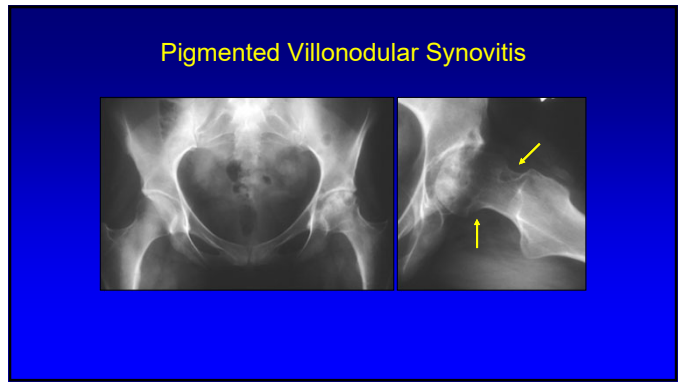
79



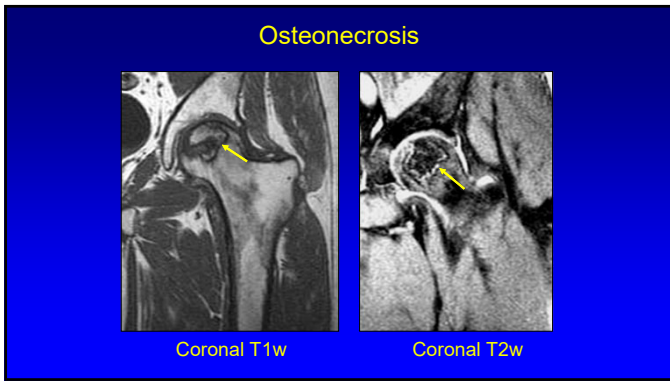
80



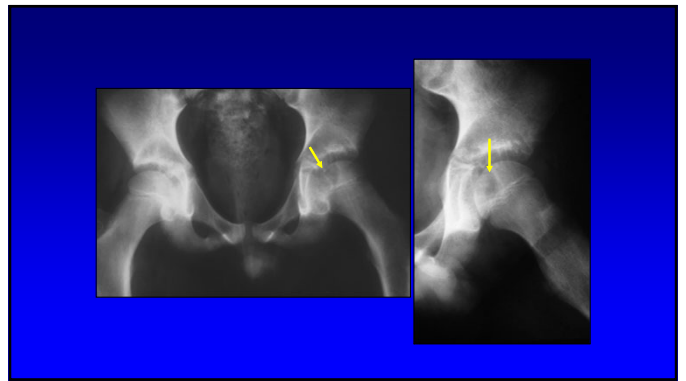
82



84

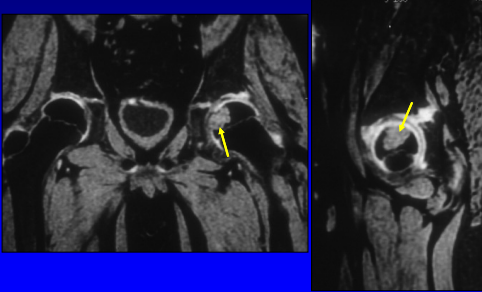


88



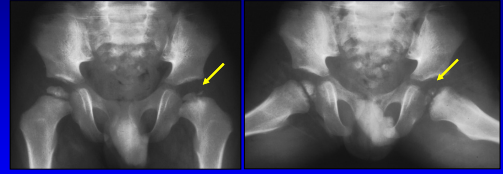
89

Chondroblastoma



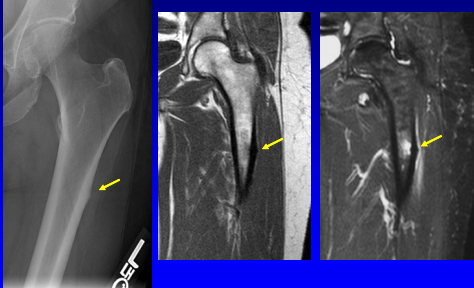
90

Meyer Dysplasia

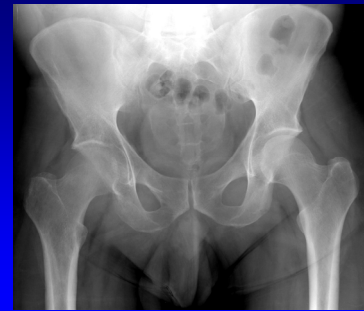

91

Insufficiency Fracture: bisphosphonate

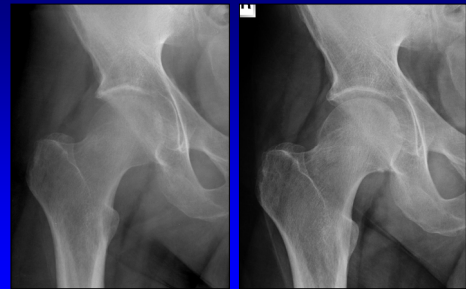


92



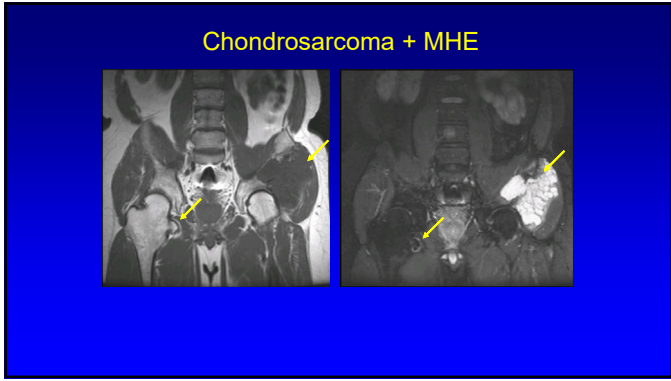
93

Transient Osteoporosis of the Hip

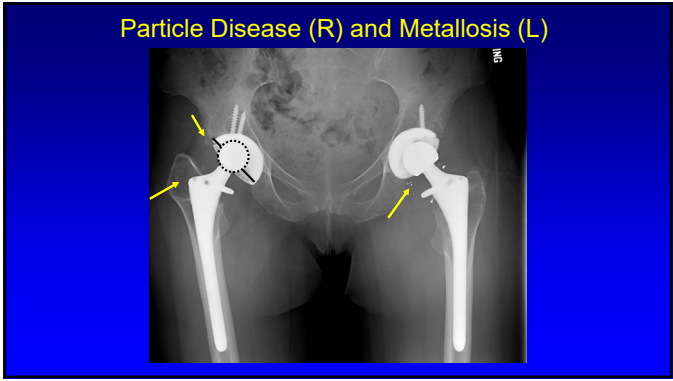


94

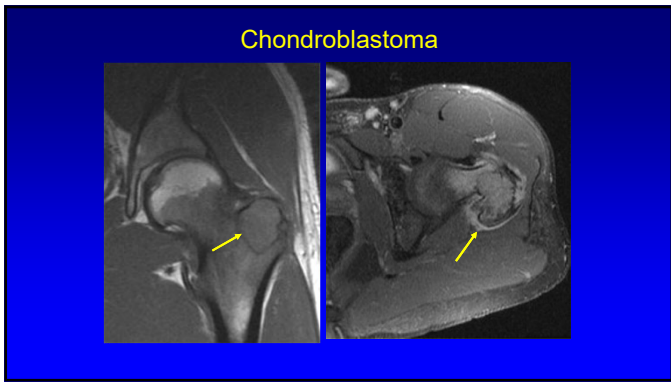
95



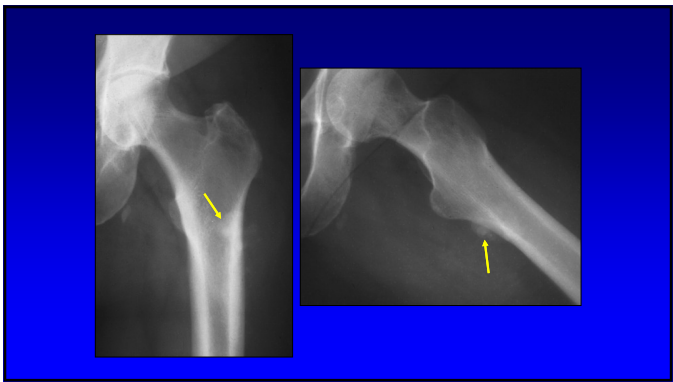
96



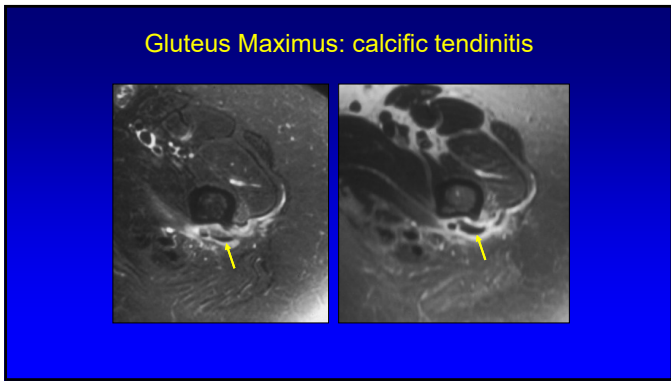
97



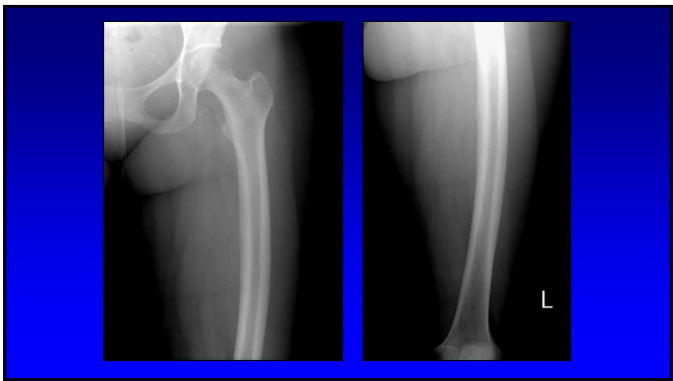
101



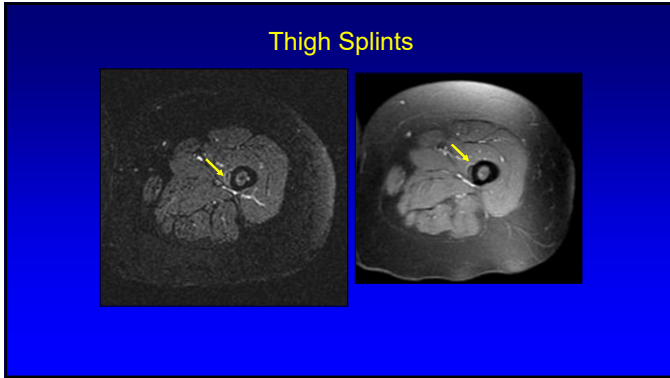
102



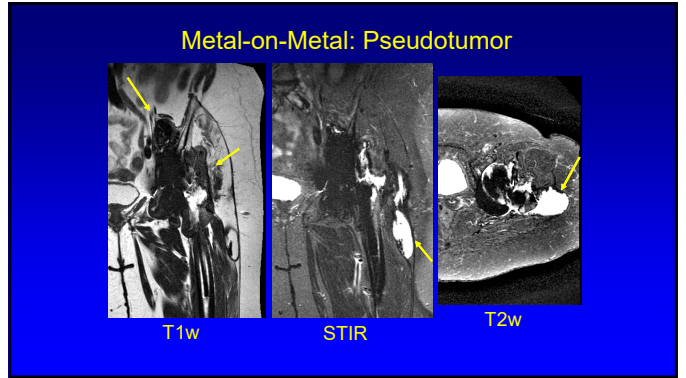
103



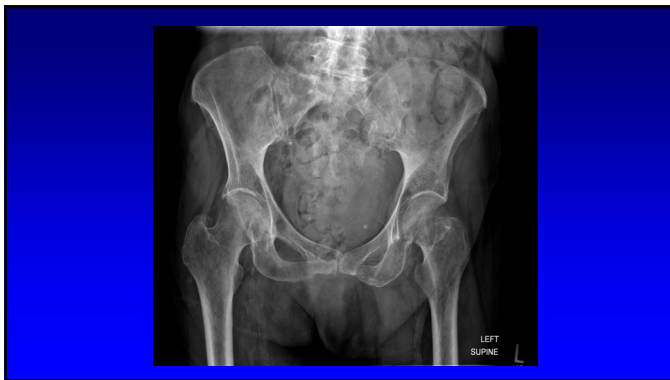105



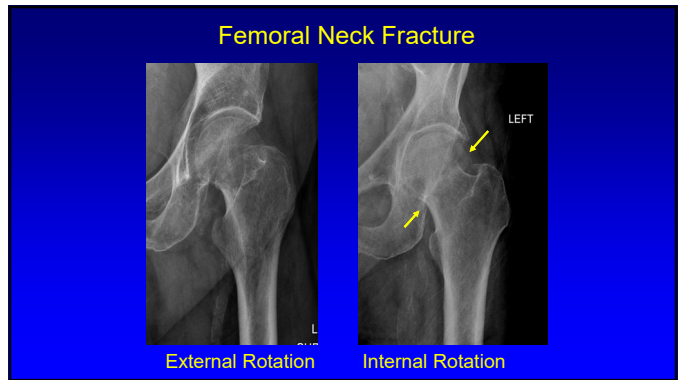
106



107



108

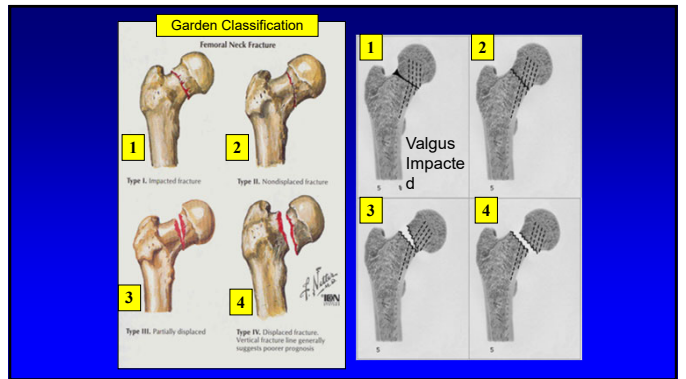


109

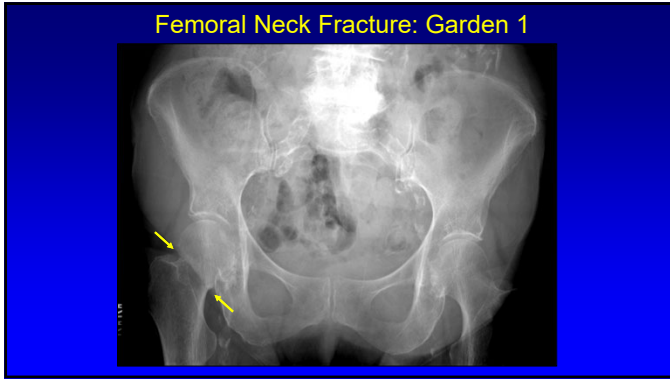
Femoral Neck Fracture:

- Internal rotation radiograph essential
- Goal: diagnose non-displaced femoral neck fracture
- Garden Classification: 1 – 4
 - 1 & 2: non-displaced → percutaneous pins
 - 3 & 4: displaced → arthroplasty (risk of AVN)
- With osteopenia, MRI necessary
 - CT not effective

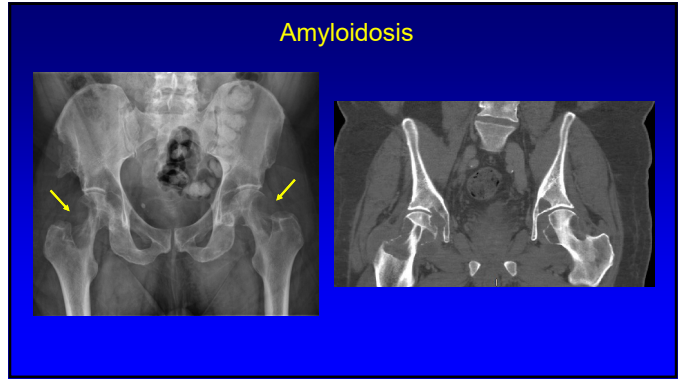
112



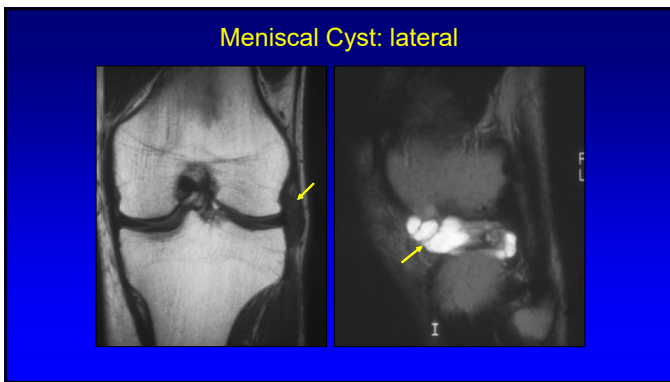
113



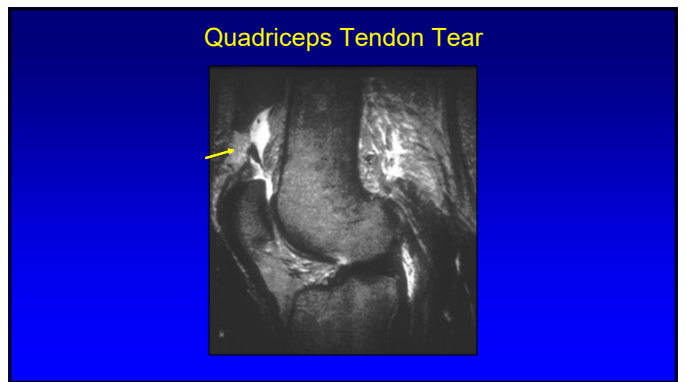
114



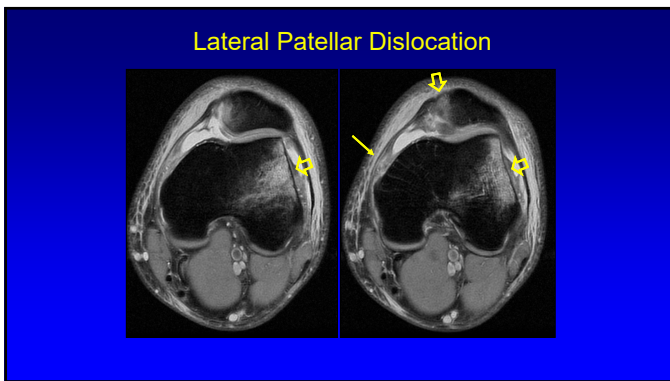
120



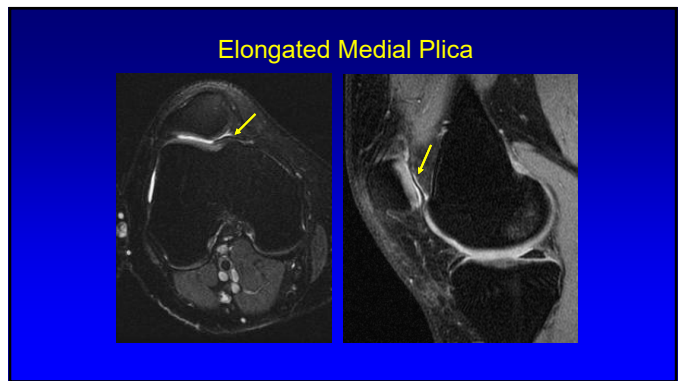
122



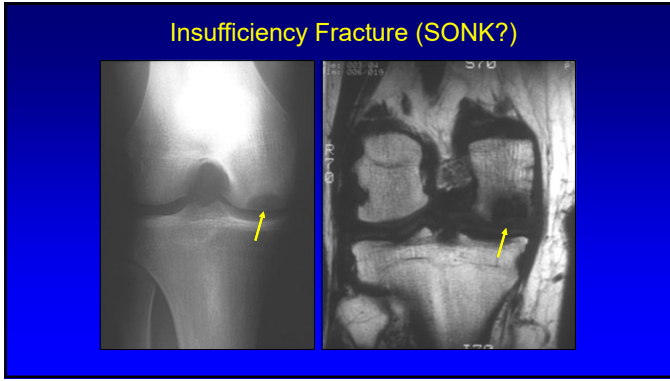
123



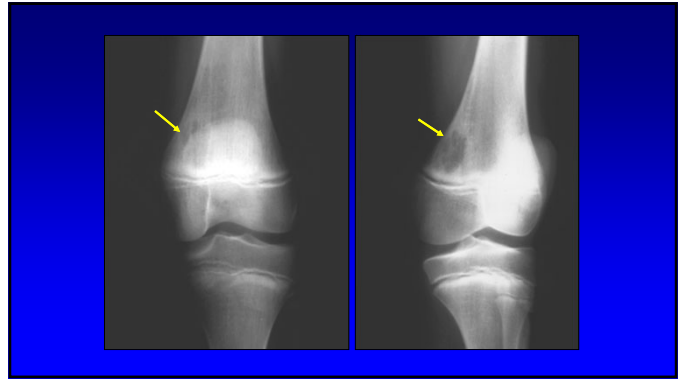
124



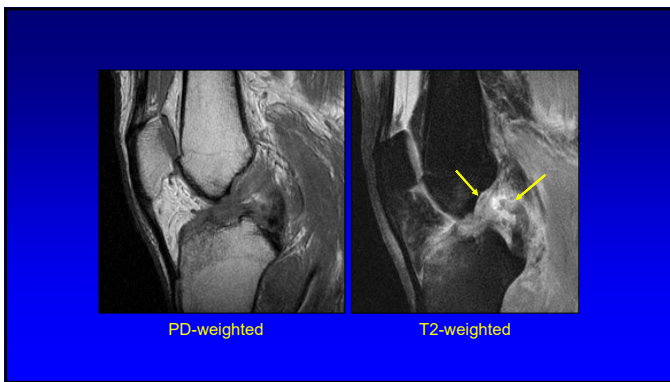
125



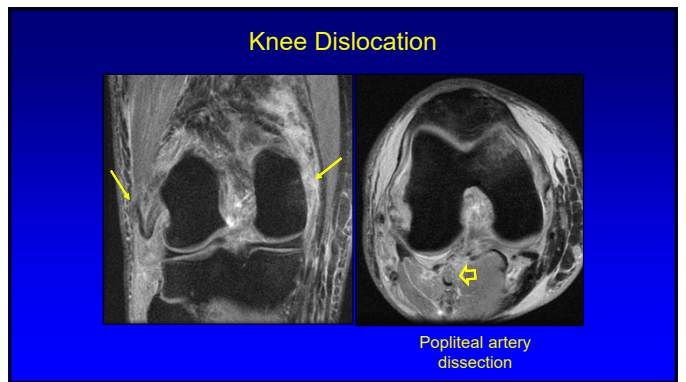
127



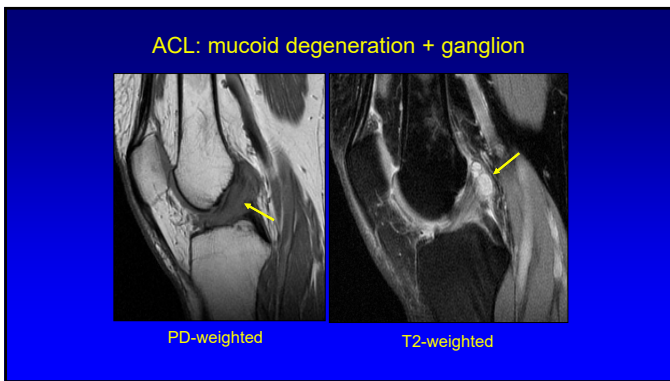
128



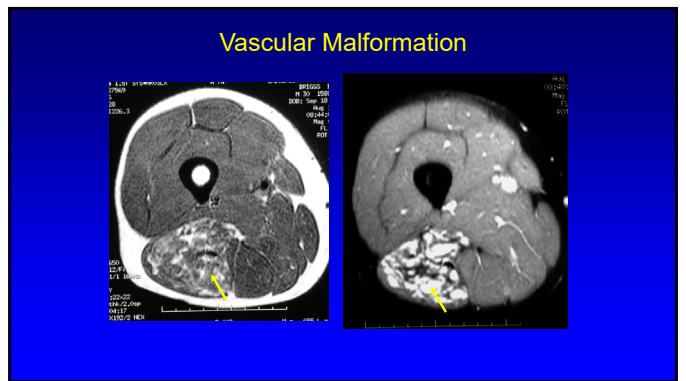
130



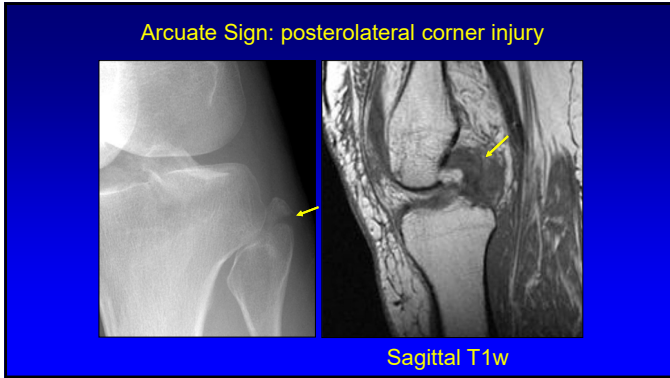
131



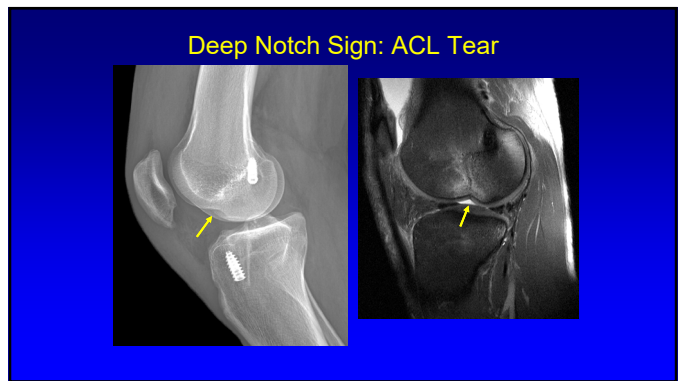
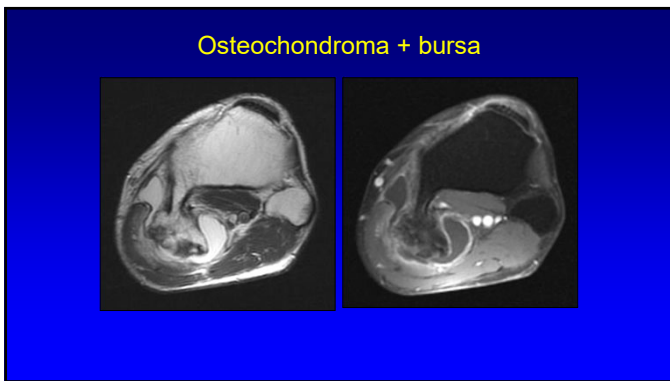
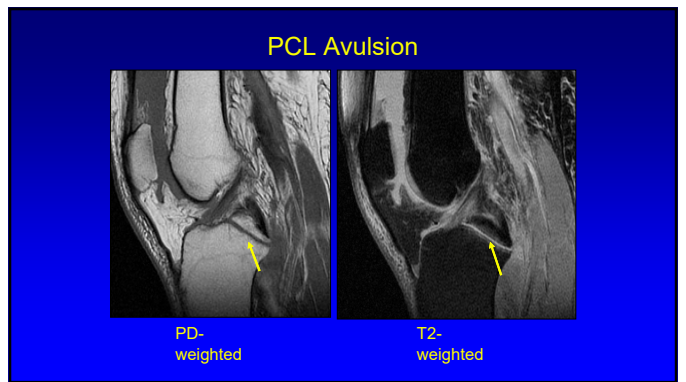
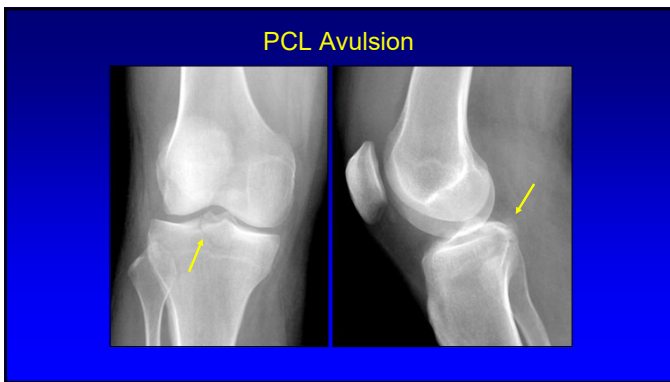
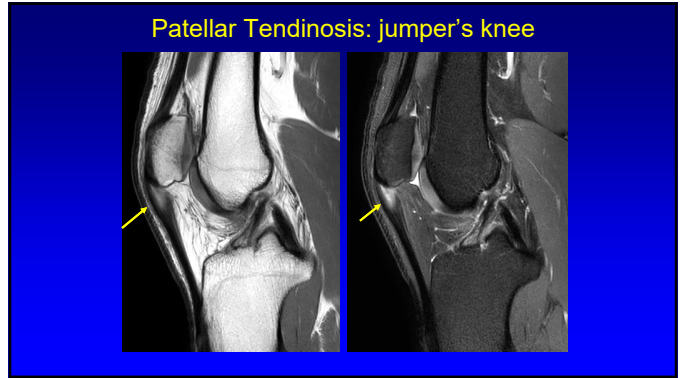
132

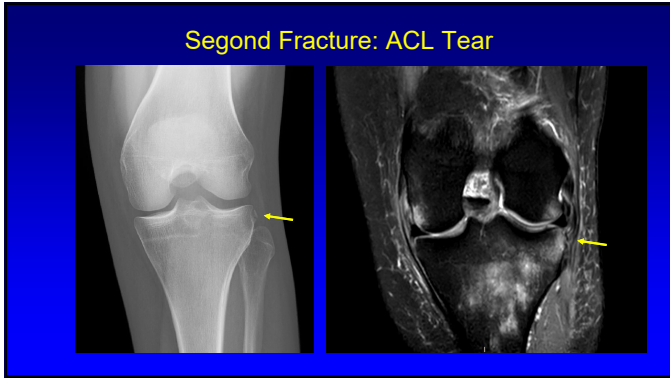


133

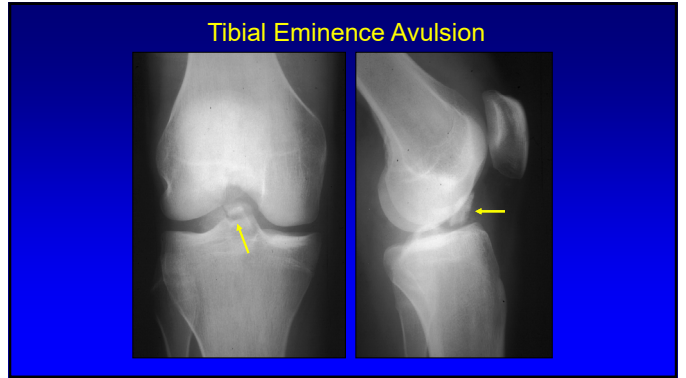


137

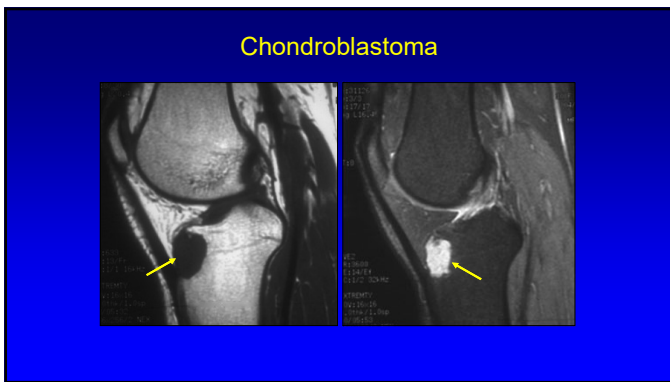




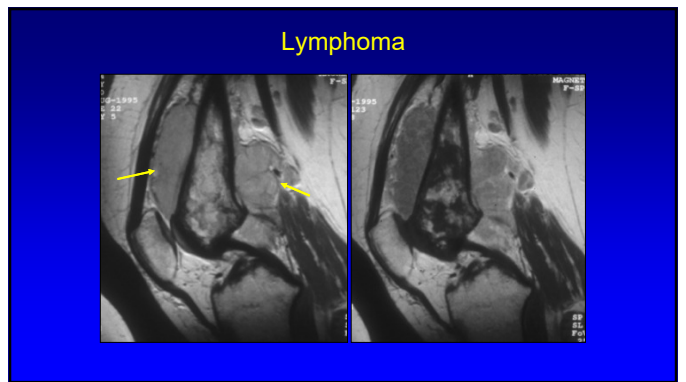
147



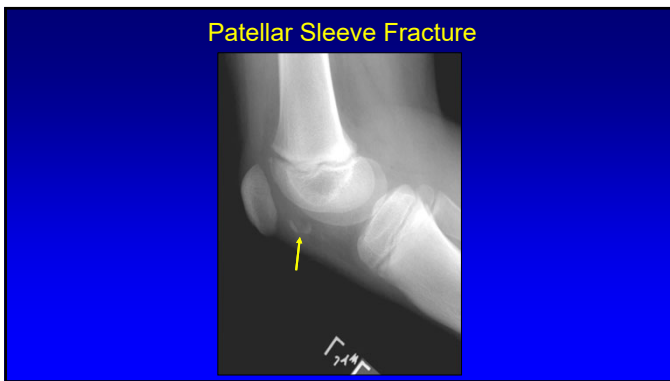
148



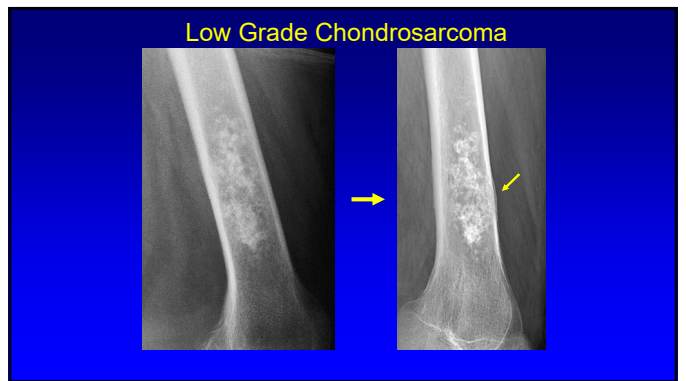
149



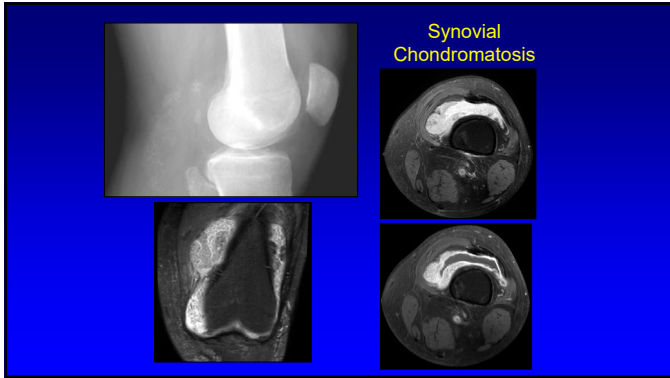
150



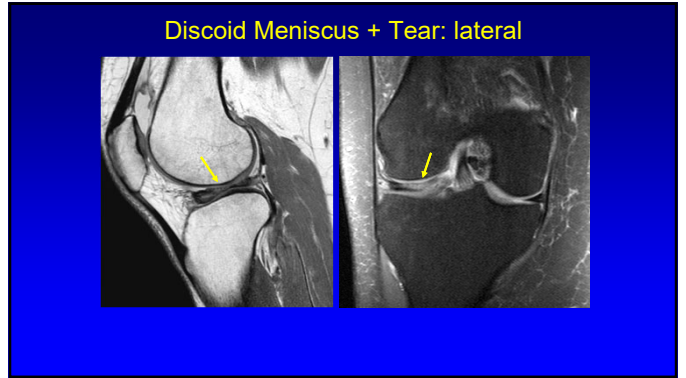
151



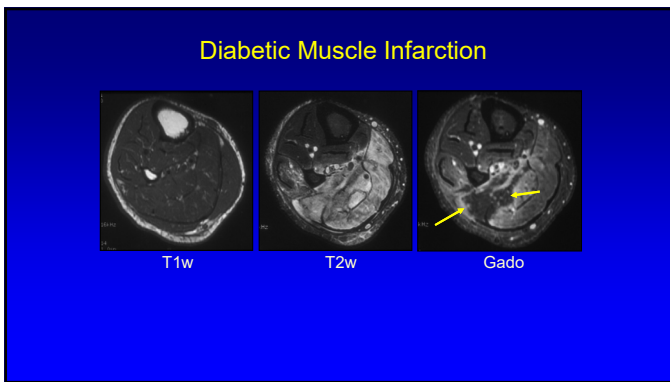
152



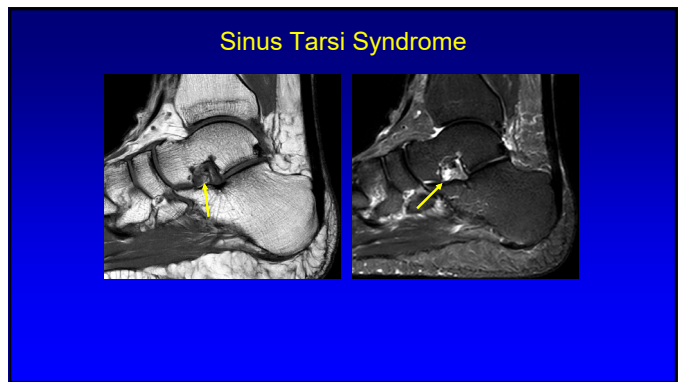
157



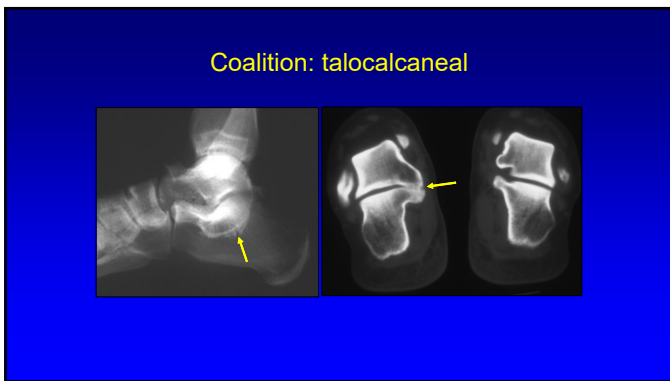
158



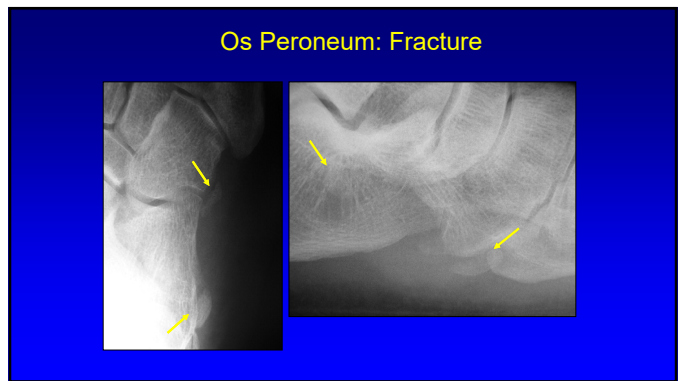
160



164

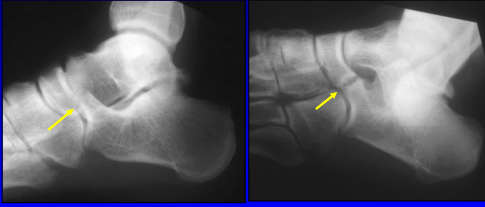

165



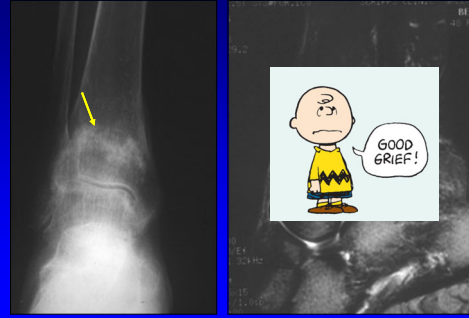
170

Coalition: calcaneonavicular



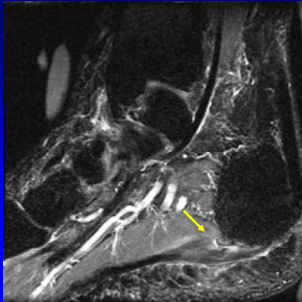
171

Insufficiency Fracture



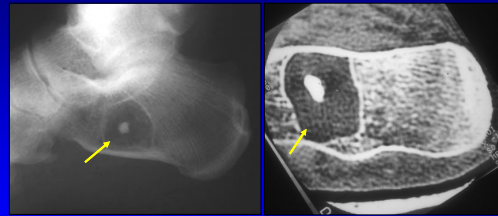
172

Plantar Fasciopathy



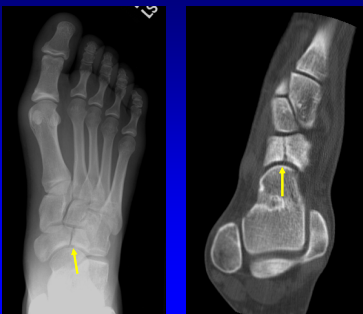173

Intra-osseous Lipoma



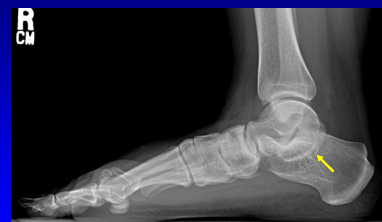174

Fatigue Fracture: Navicular



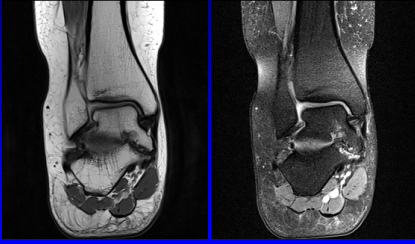
176

Subtalar Coalition



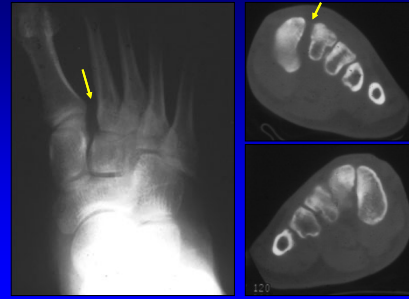178

Subtalar Coalition



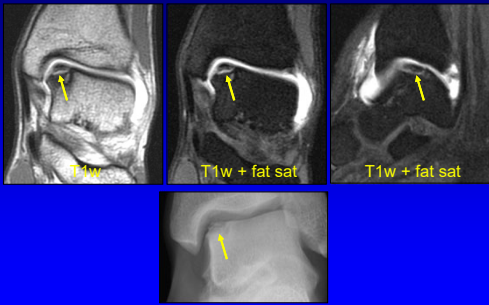
179

Lisfranc Ligament Injury

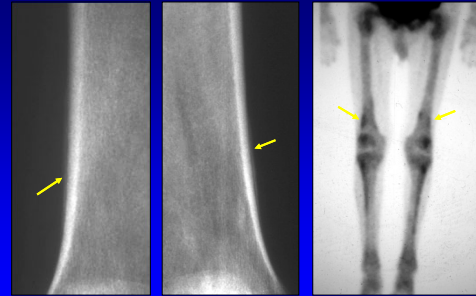


180

Osteochondral Abnormality: unstable

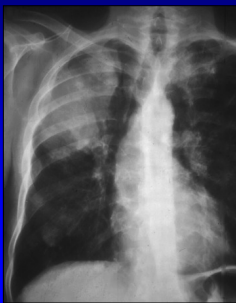

182



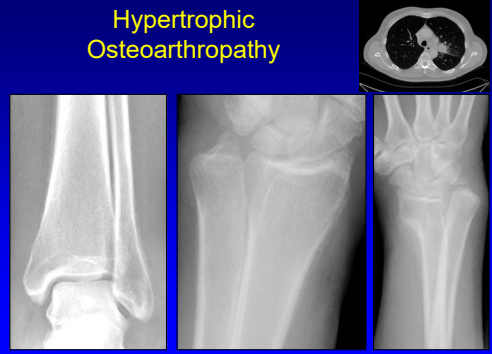
186

Hypertrophic Osteoarthropathy

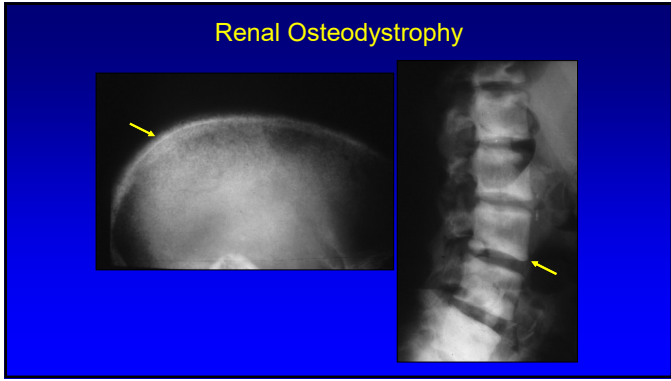


187

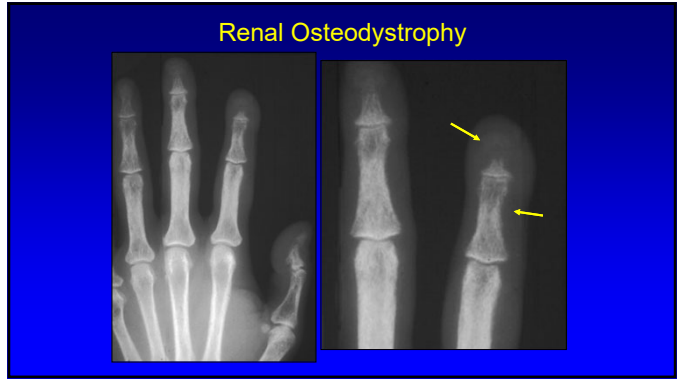
Hypertrophic Osteoarthropathy



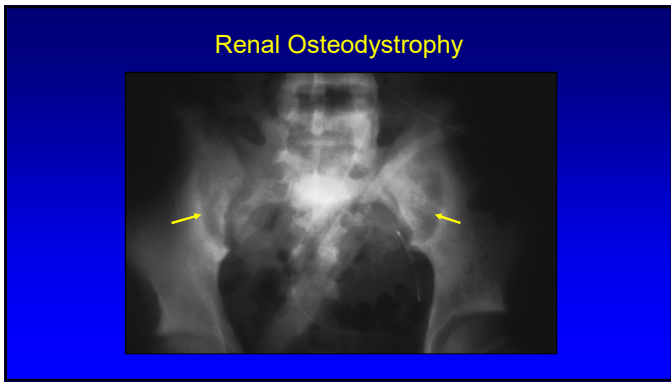
188



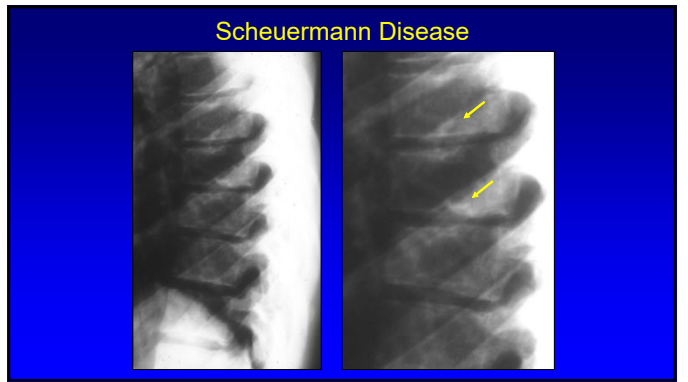
203



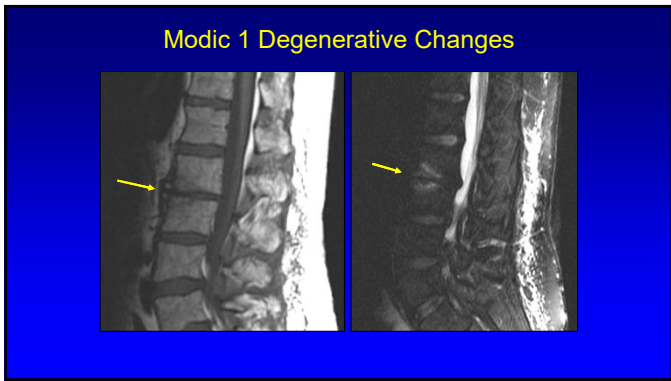
204



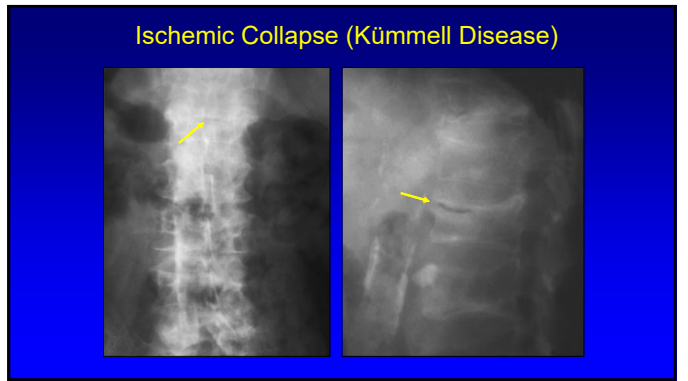
205



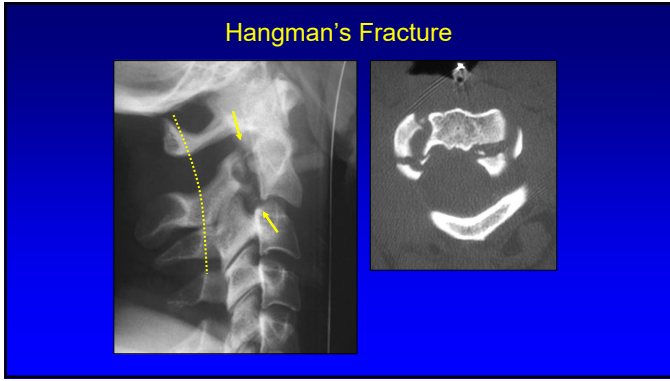
206



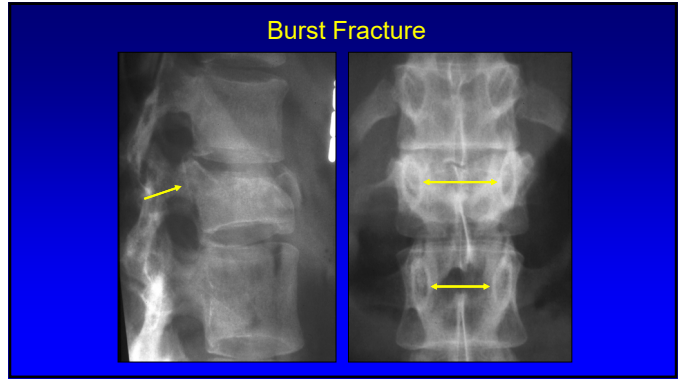
207



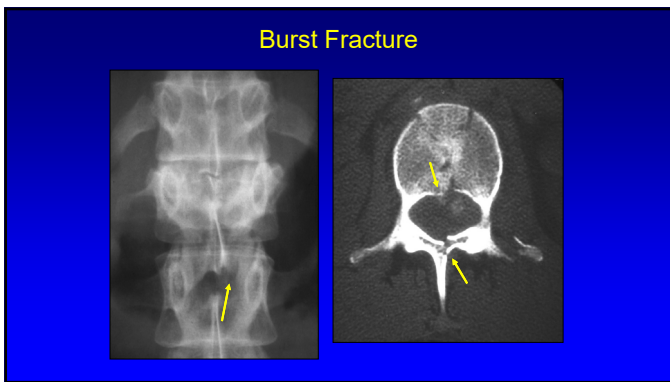
208



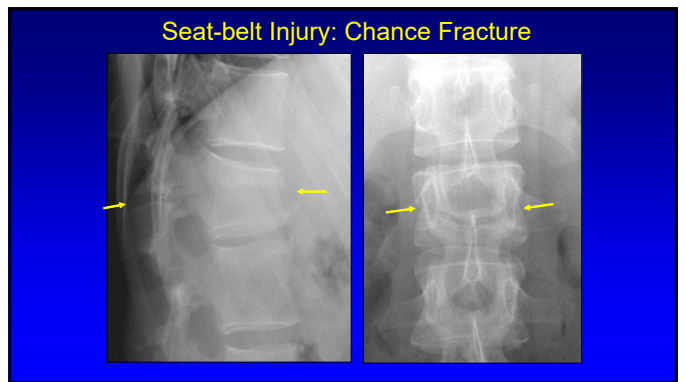
209



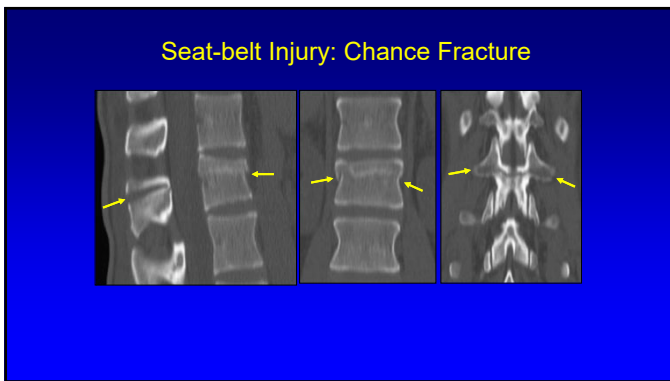
212



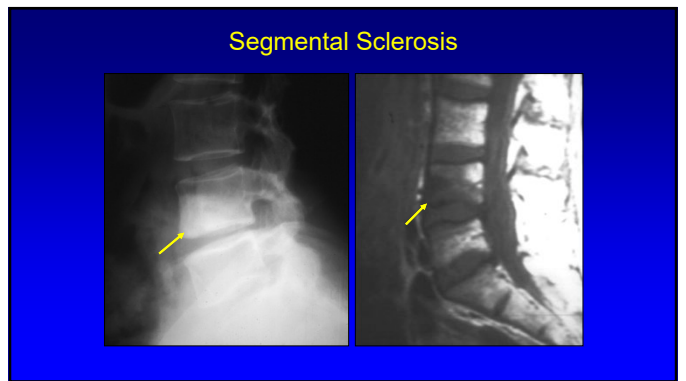
213



214

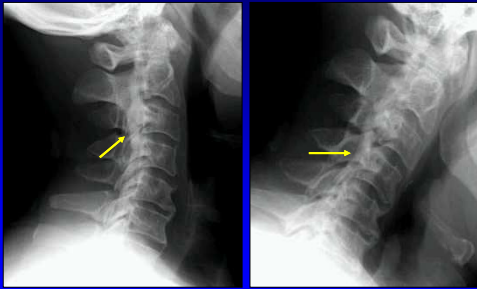


215



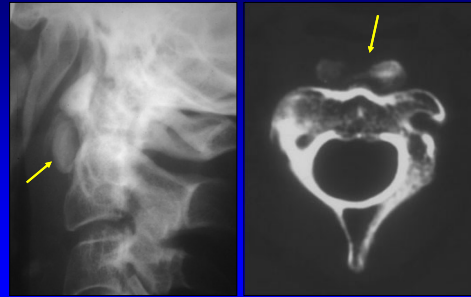
216

Ossification Posterior Longitudinal Ligament



244

Calcific Tendinitis: longus coli



247

Thank you!

Syllabus on line and other educational material:
www.jacobsonmuskus.com

Twitter handle: @jjacobsn

265