

**Musculoskeletal Imaging  
Case Conference**

---

**Jon A. Jacobson, MD FACR**  
FSRU, FAIUM, RMSK

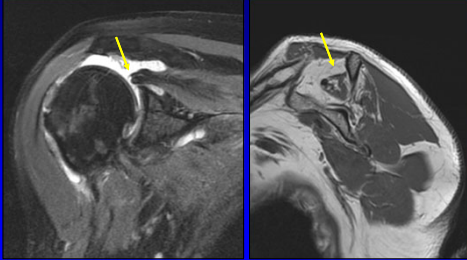
*Professor of Radiology  
Lenox Hill Radiology, NYC  
University of California, San Diego*



 Syllabus

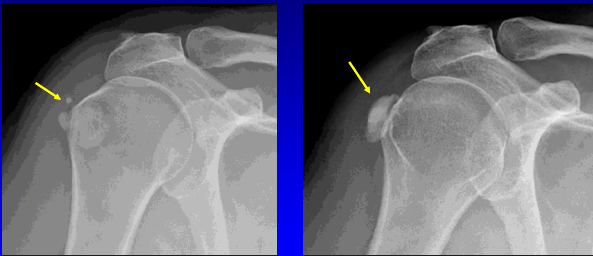
1

**Full-thickness Tear: supraspinatus**



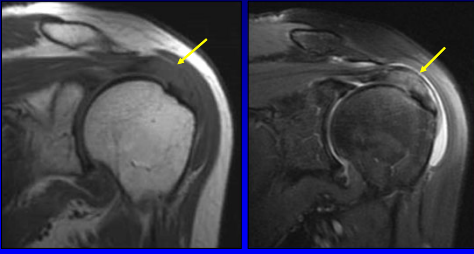
2

**Calcium Hydroxyapatite Deposition**



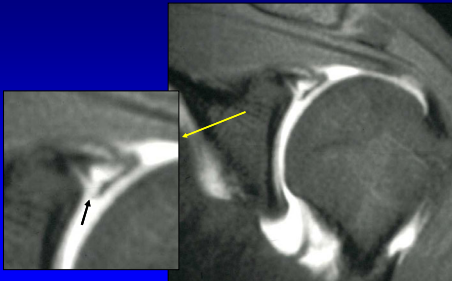
3

**Tendinosis: supraspinatus**



4


**SLAP Tear: Type 2**



Coronal-oblique T1w fat-sat

5

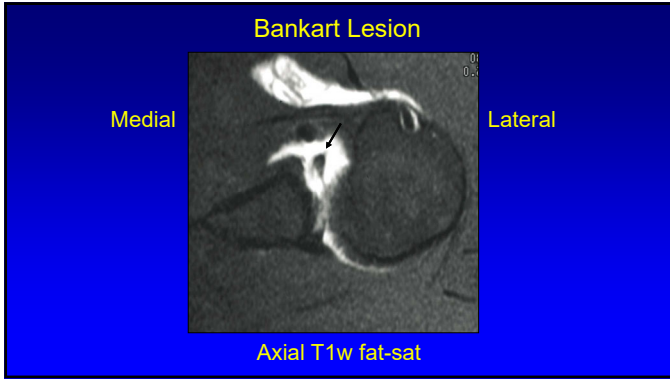
**SLAP Tear: Type 2**



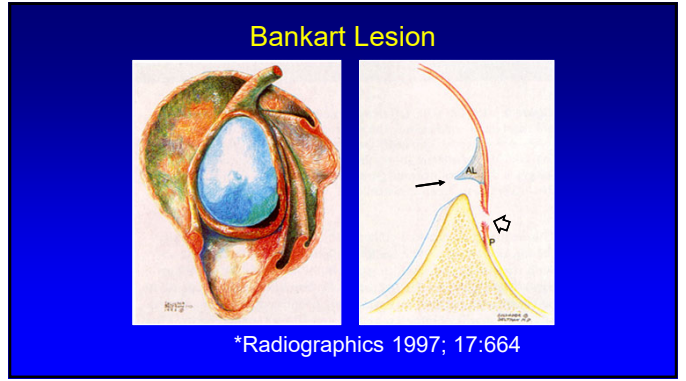
Posterior Anterior

\*Radiographics 1997; 17:670

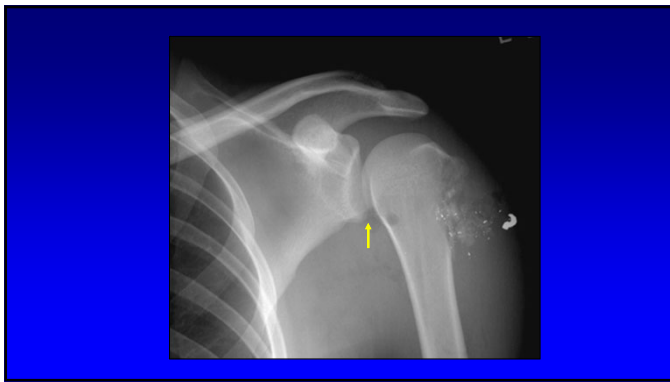
6



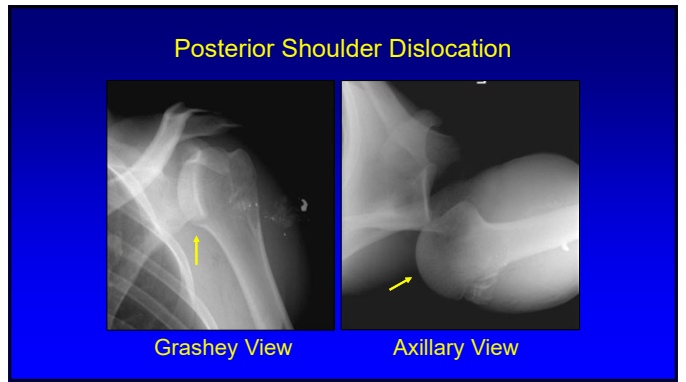
7



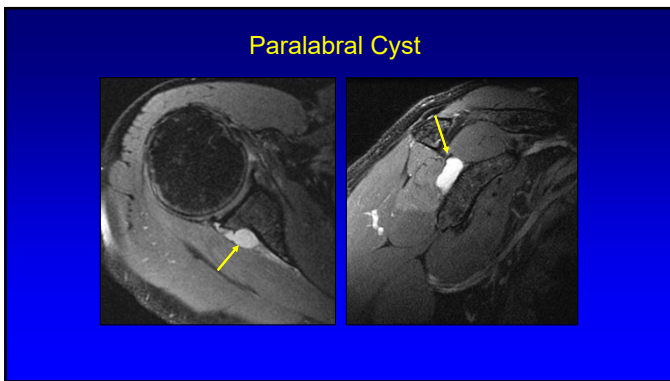
8



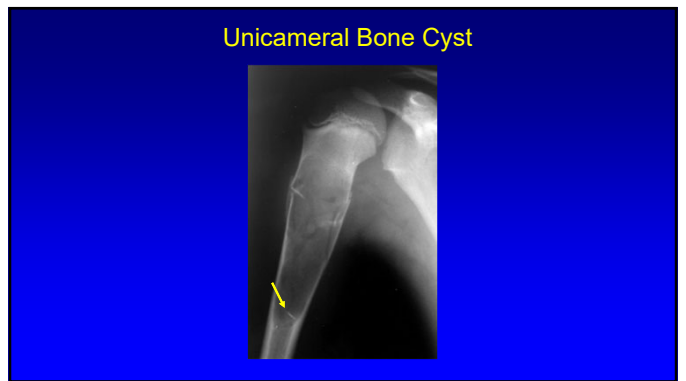
9



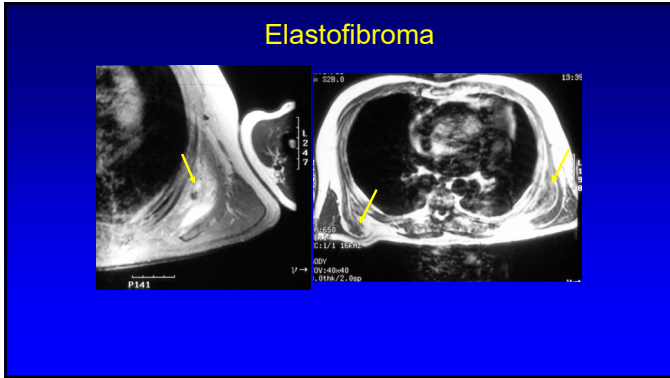
10



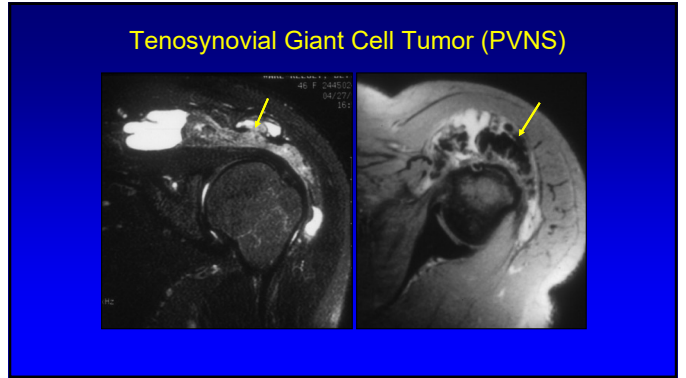
11



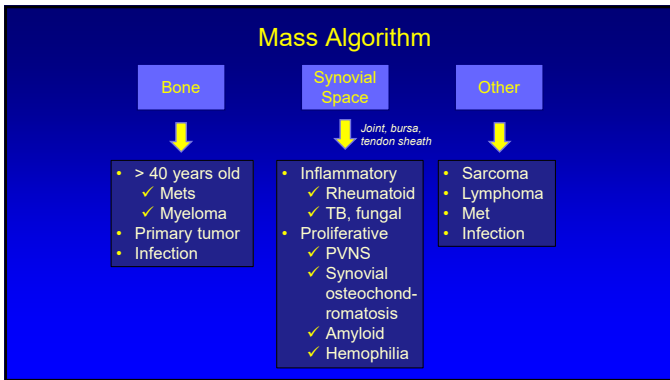
12



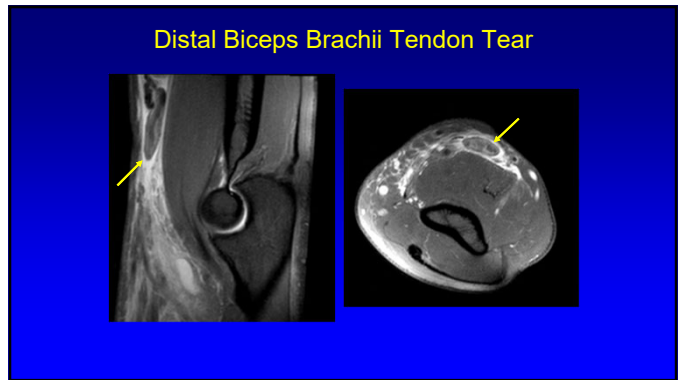
13



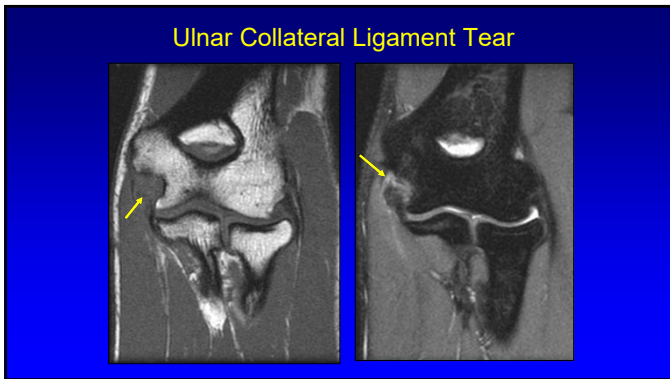
14



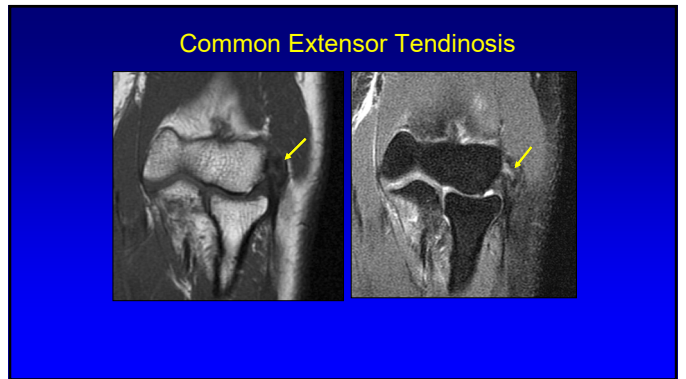
15



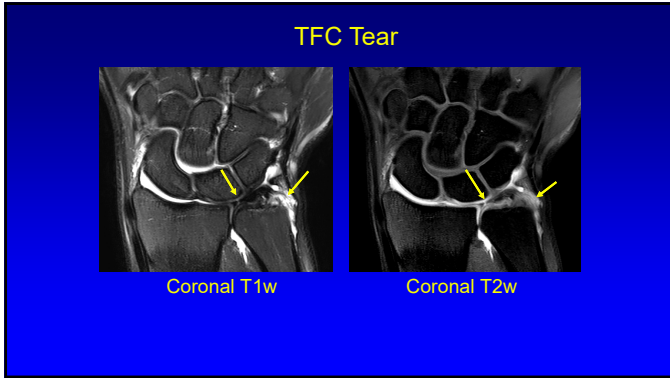
16



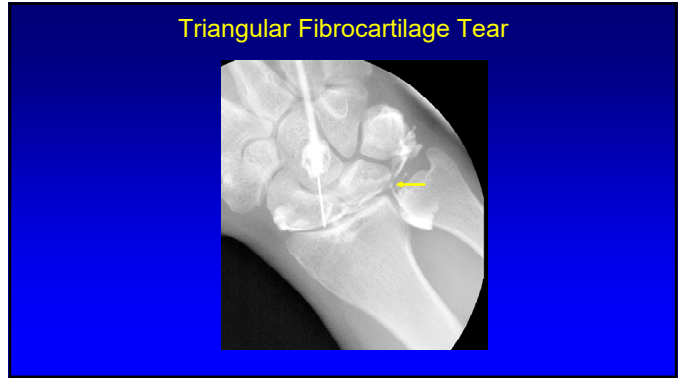
17



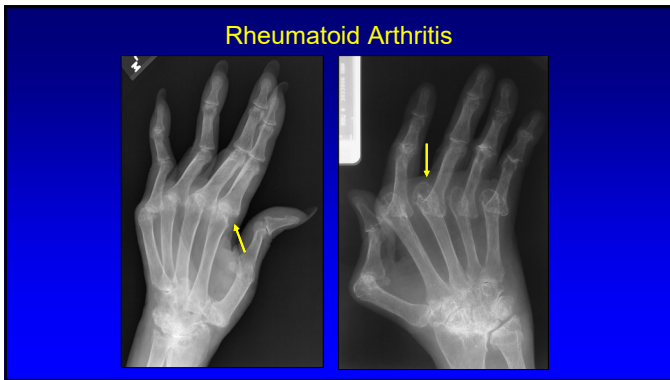
18



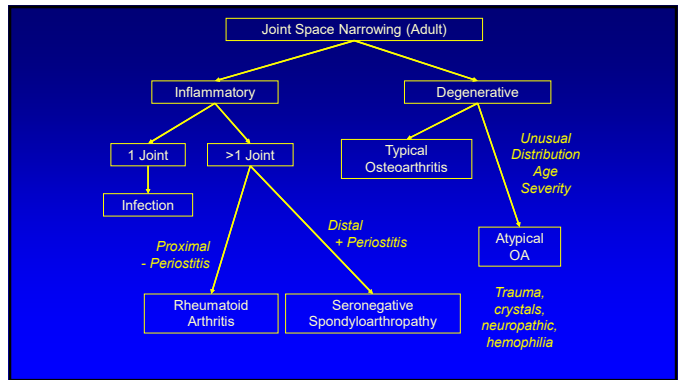
19



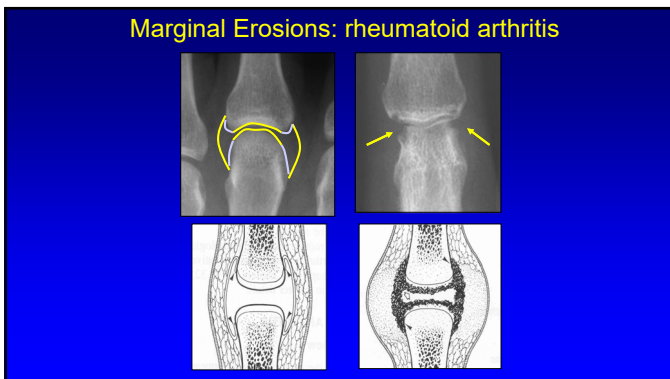
20



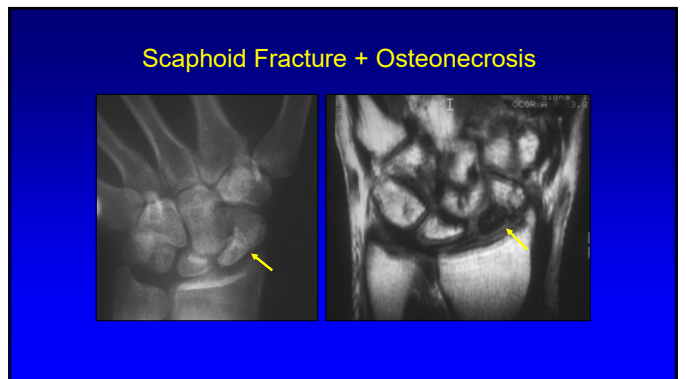
21



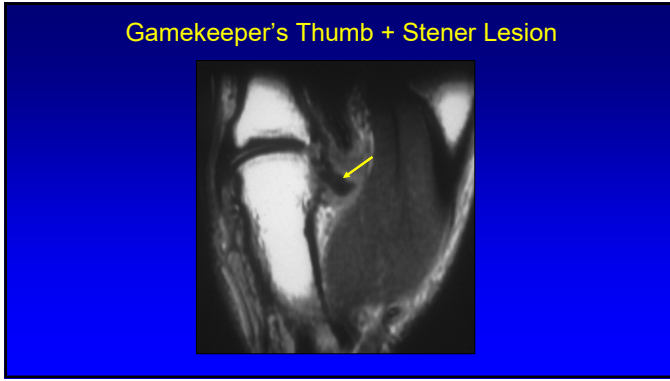22



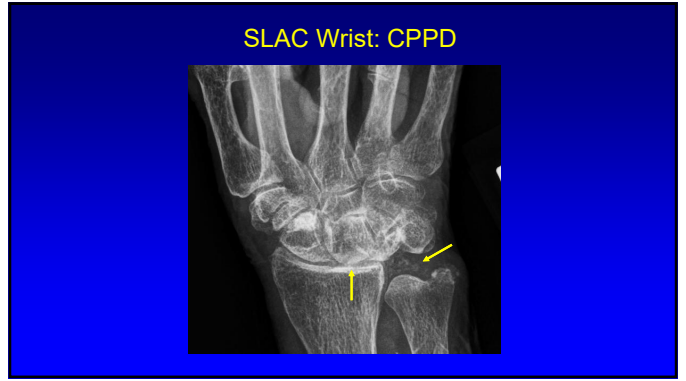23



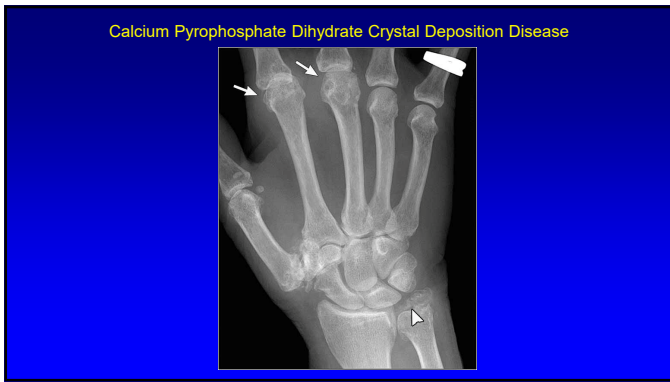24



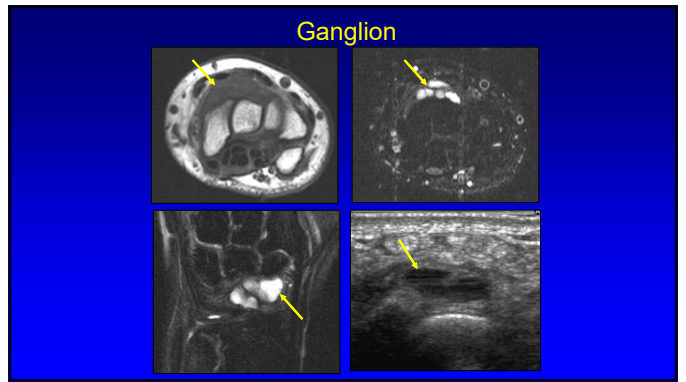
25



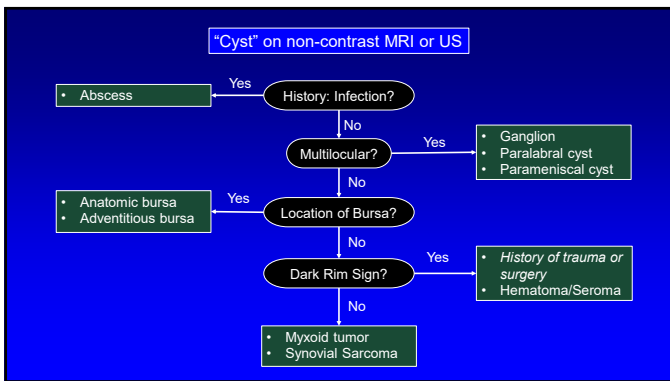
26



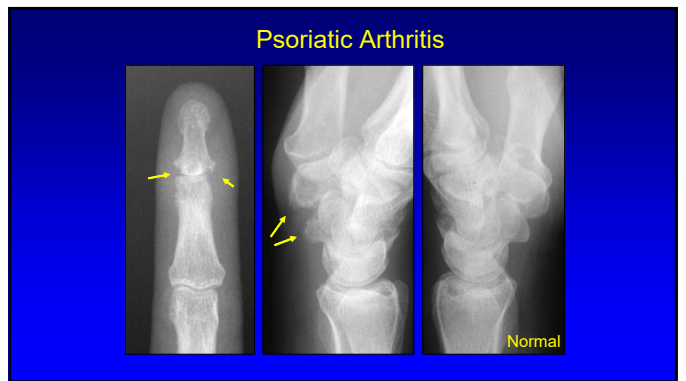
27



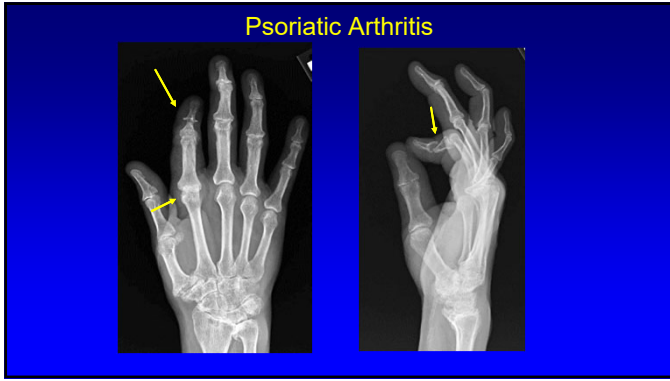28



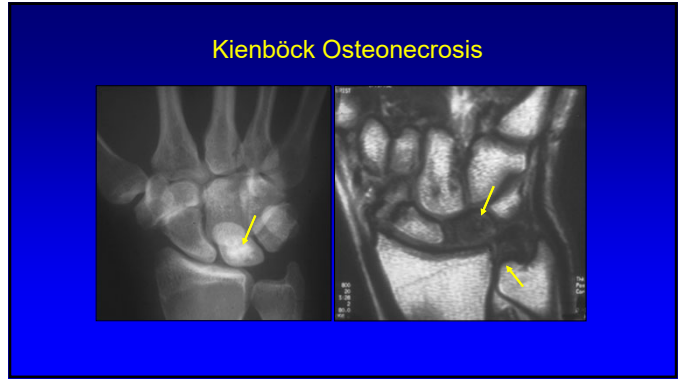
29



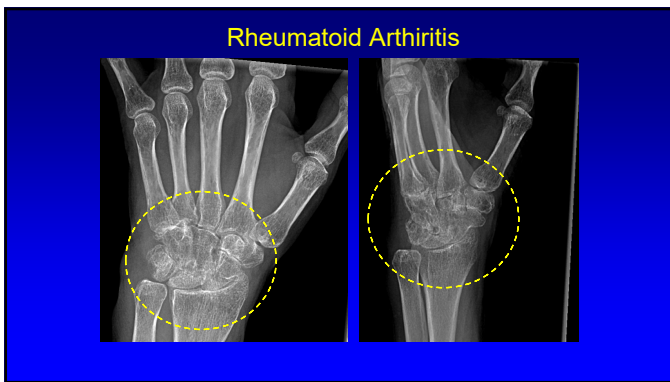
30



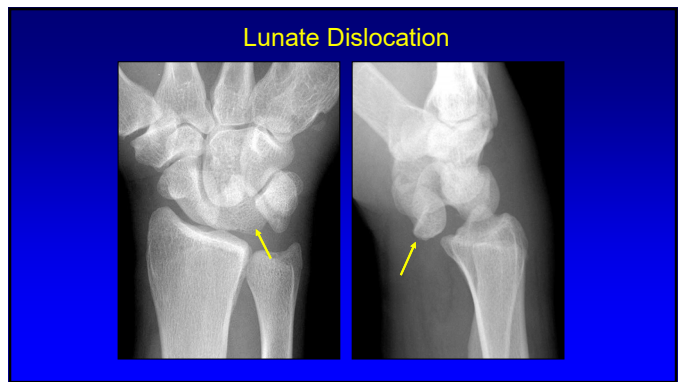
31



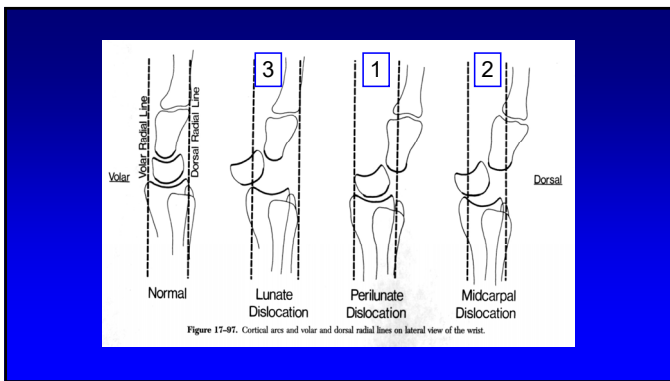
32



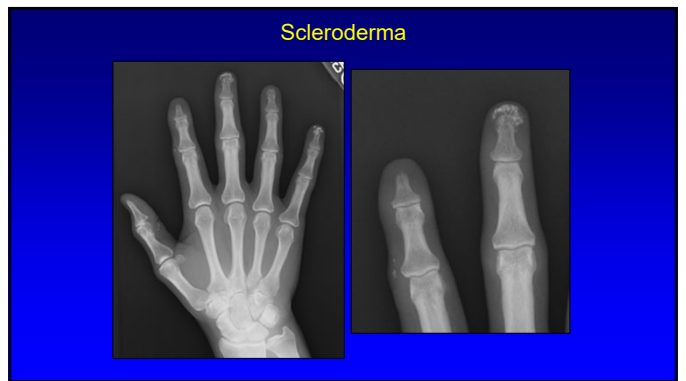
33



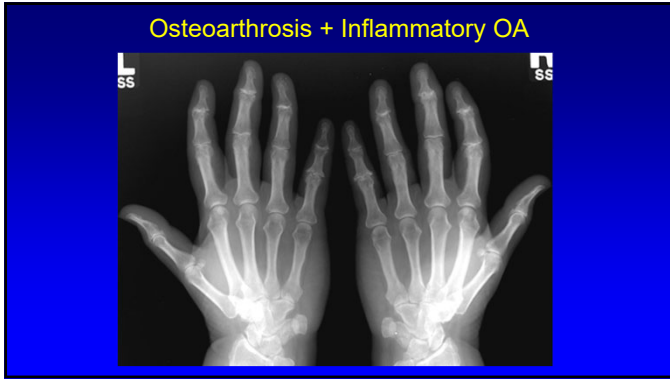34



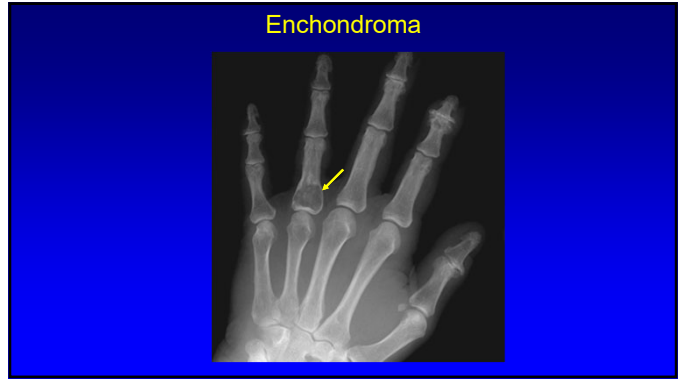35



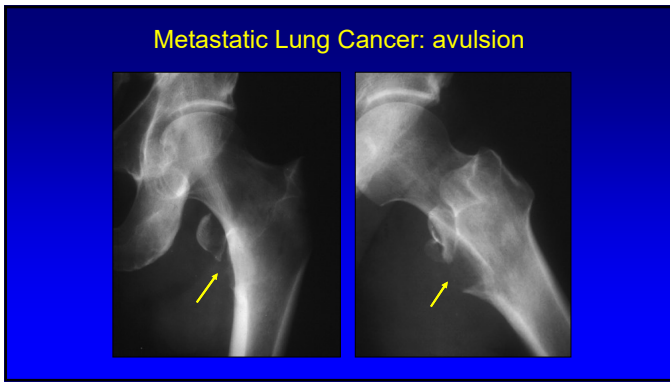
36



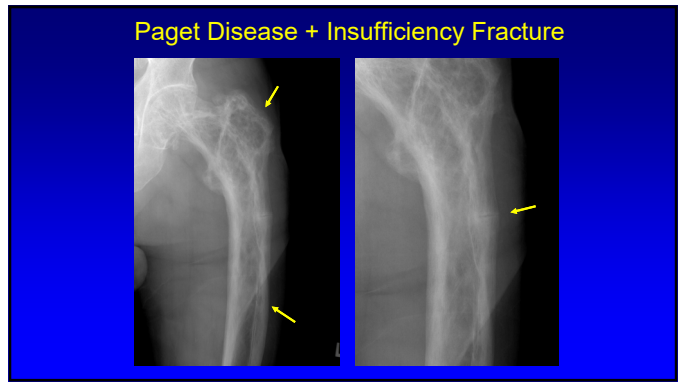
37



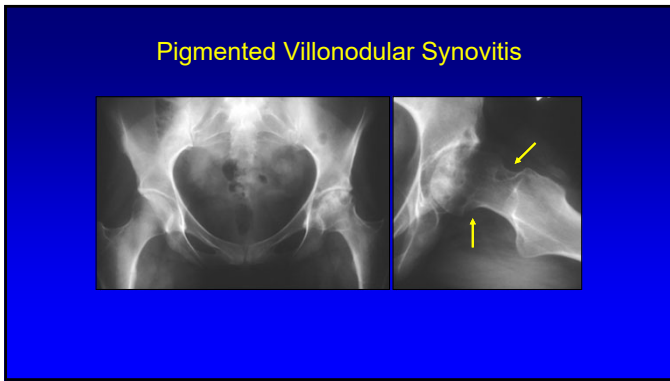
38



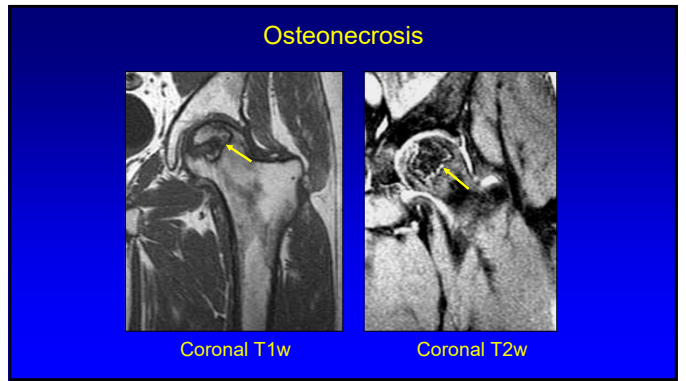
39



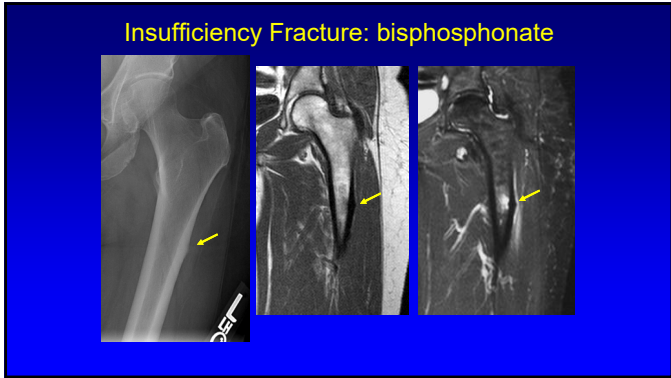
40



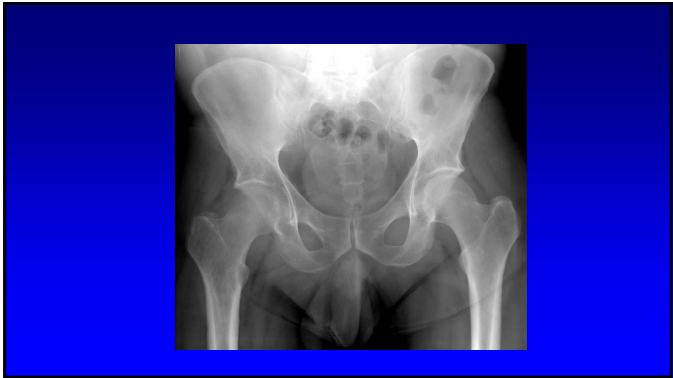41



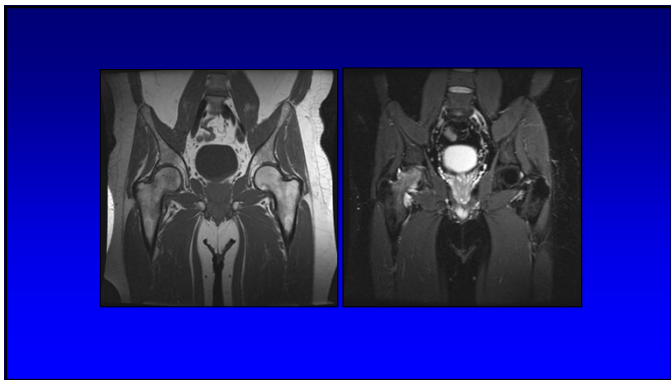
43



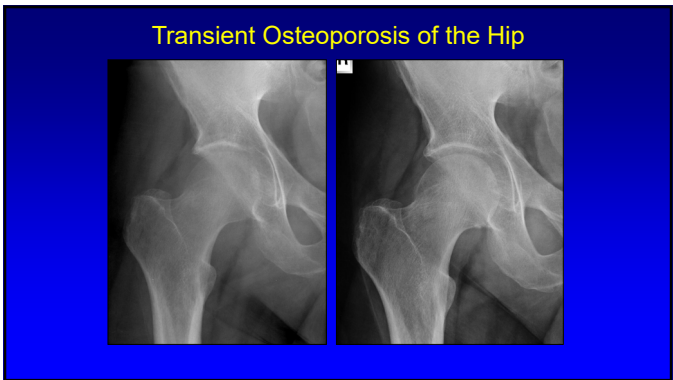
44



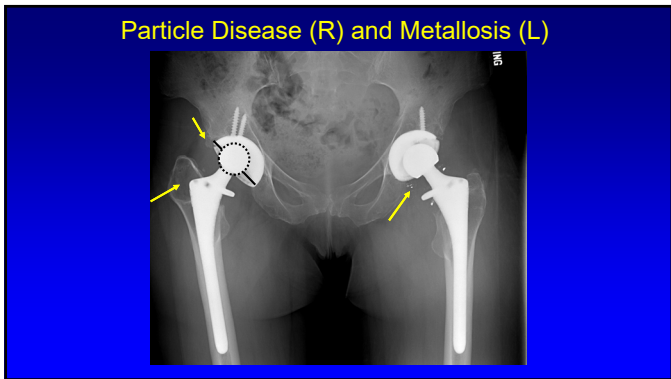
45



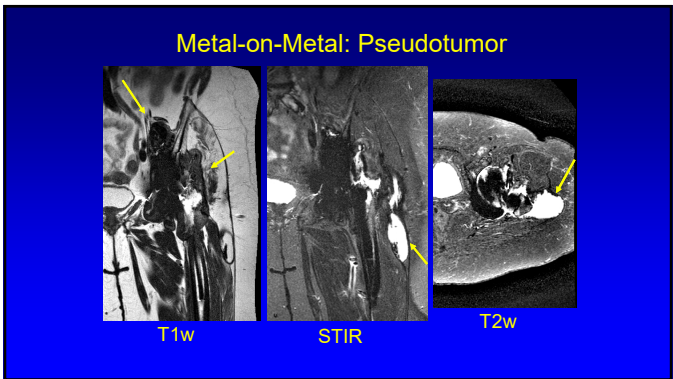
46



47

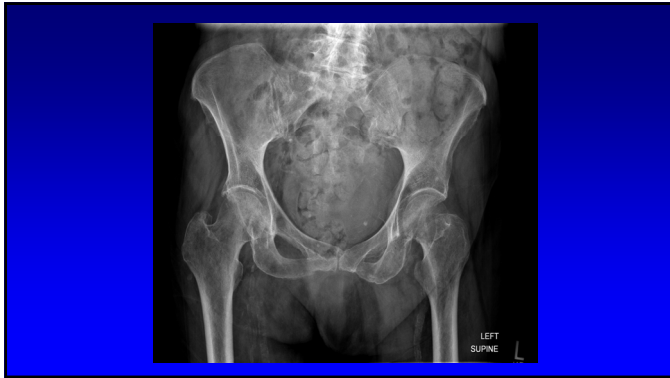

48

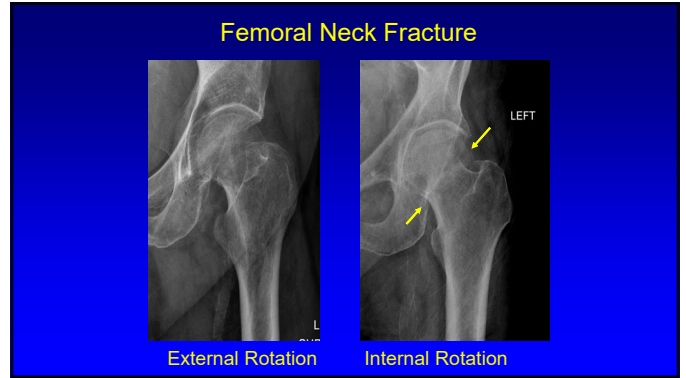


49

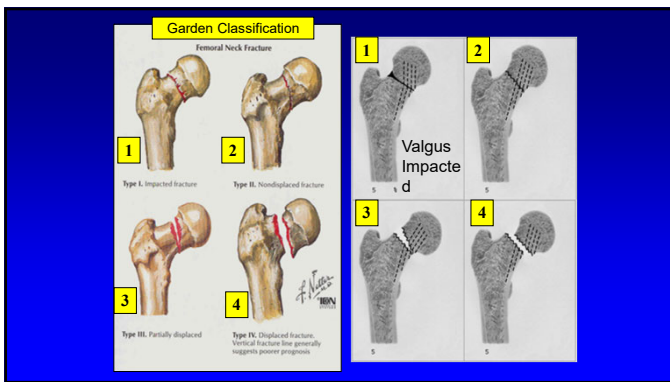




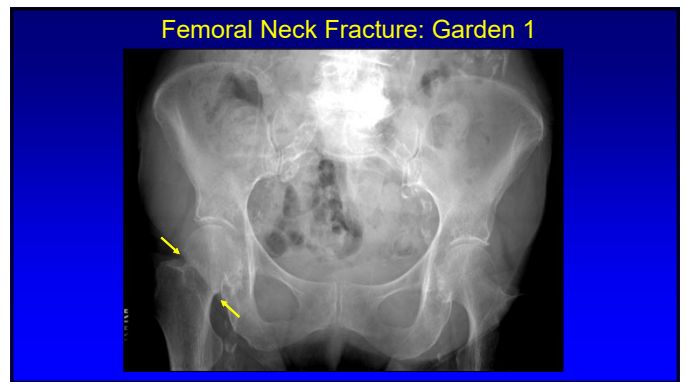
50



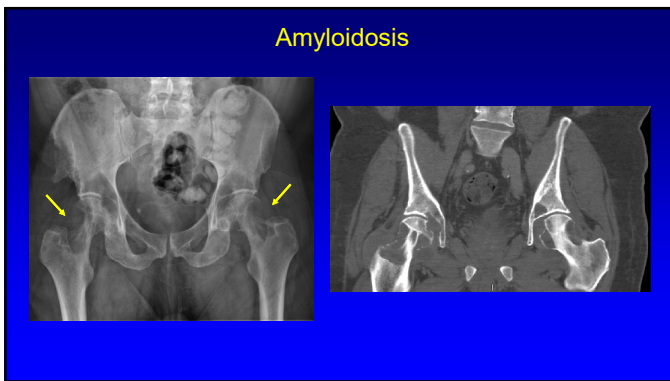
51



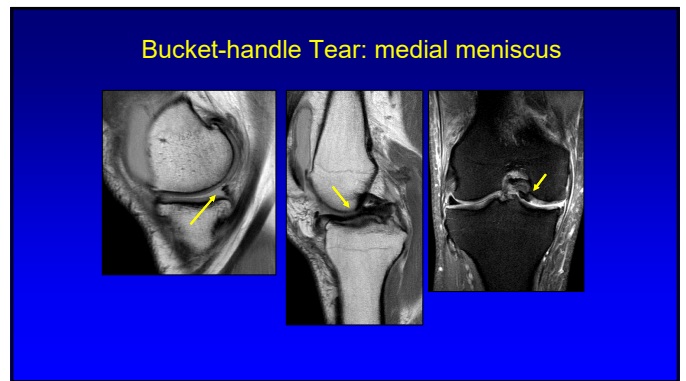
52



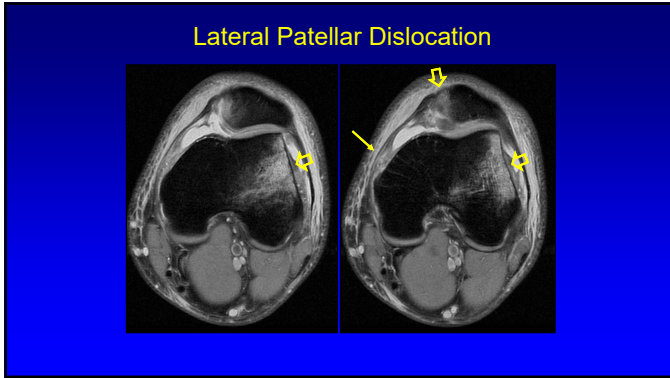
53



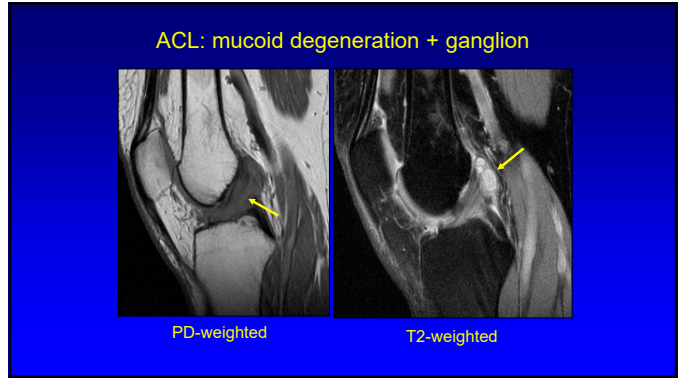
54



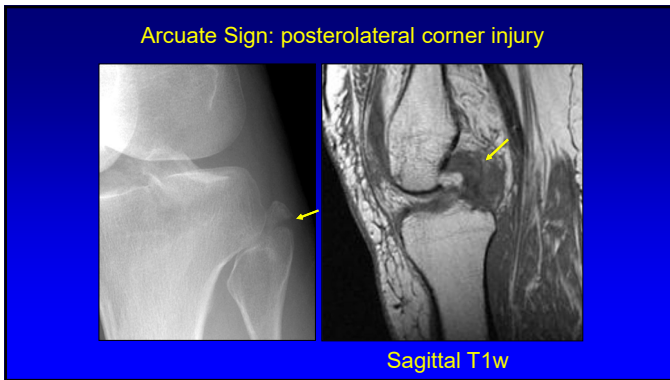
55



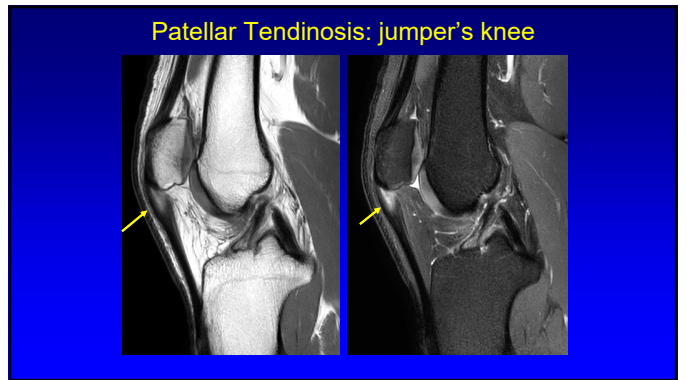
56



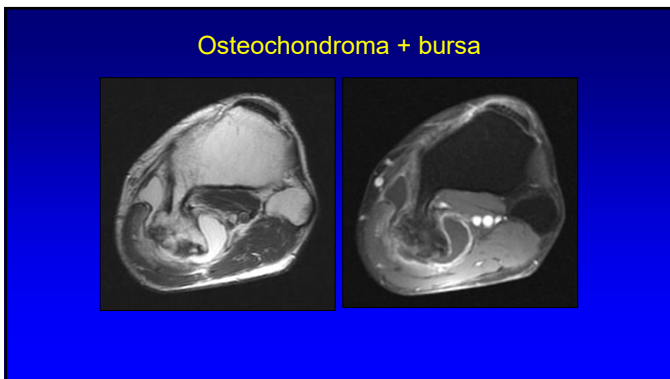
57



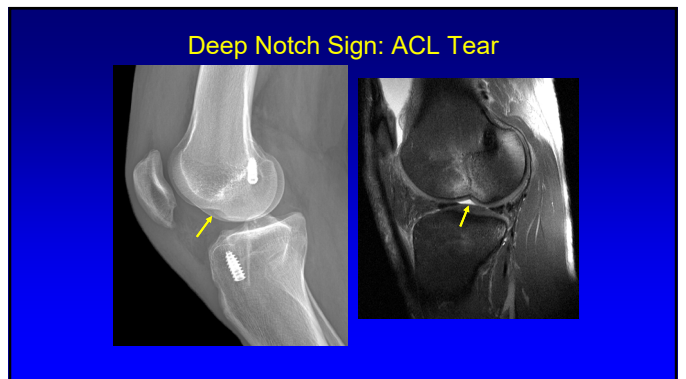
58



59

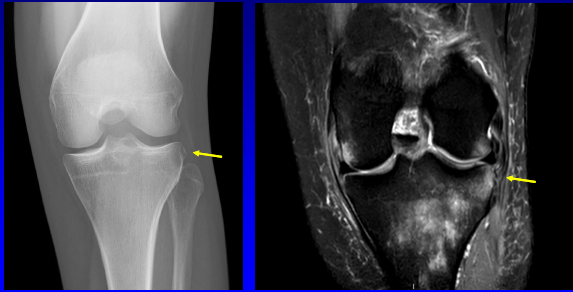


60



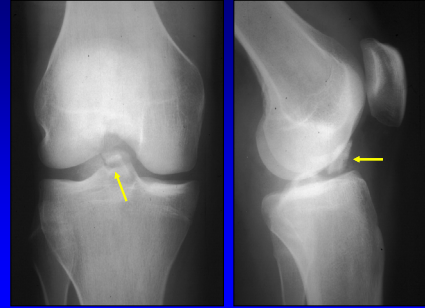
61

Second Fracture: ACL Tear



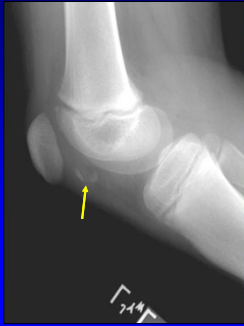
62

Tibial Eminence Avulsion



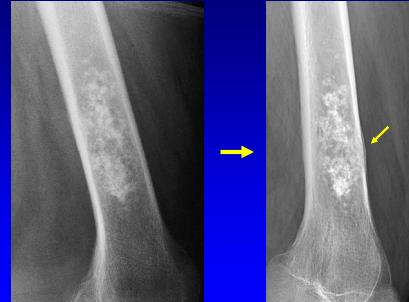
63

Patellar Sleeve Fracture



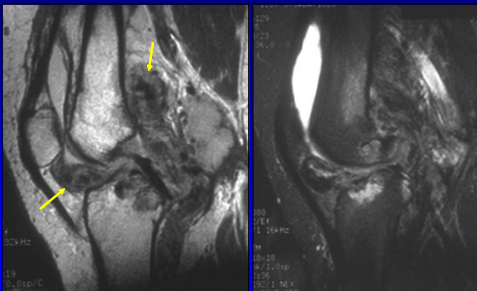
64

Low Grade Chondrosarcoma



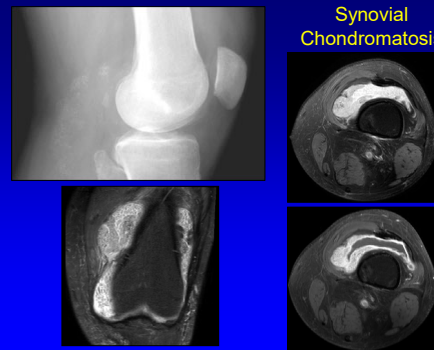
65

Tenosynovial Giant Cell Tumor (PVNS)

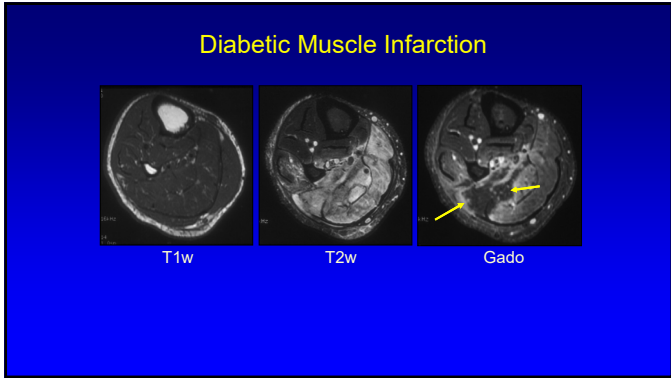


66

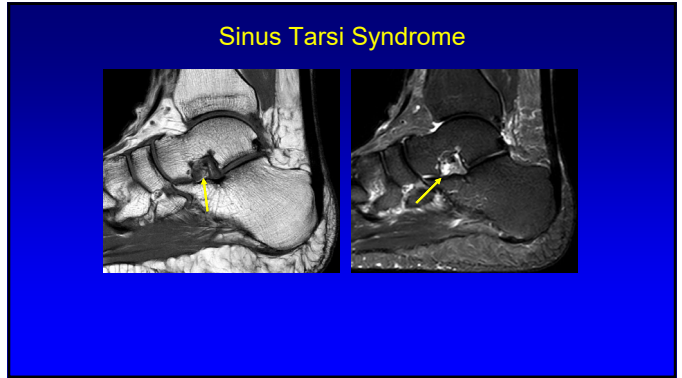
Synovial Chondromatosis



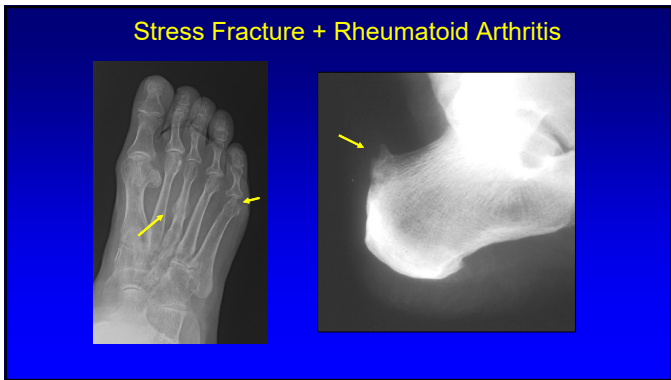
67



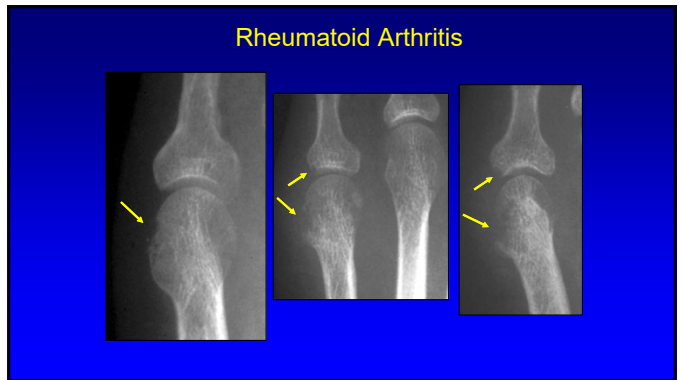
68



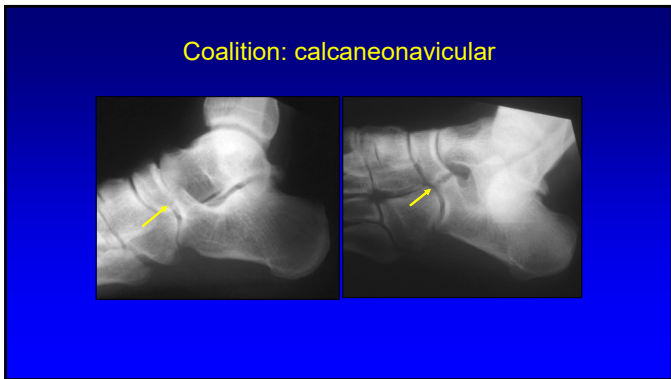
69



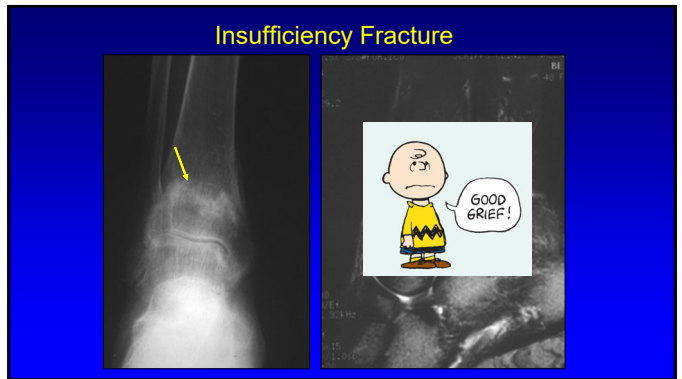
70



71

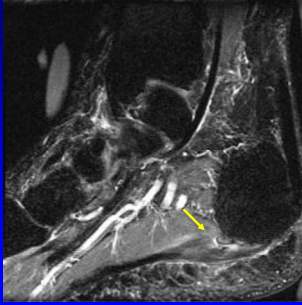


72



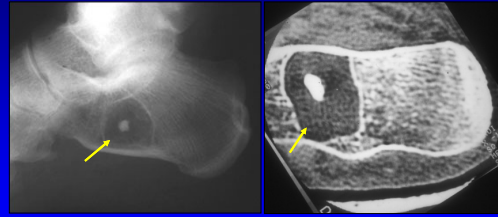
73

### Plantar Fasciopathy



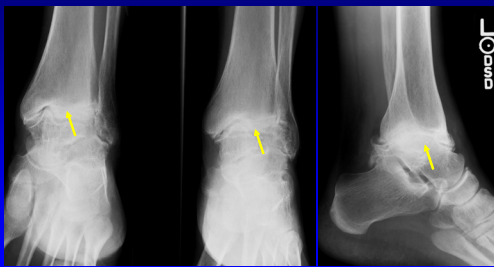74

### Intra-osseous Lipoma



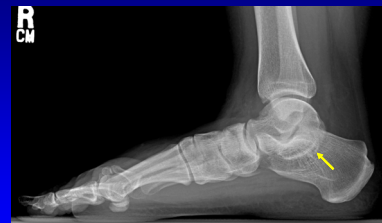75

### Hemophilia



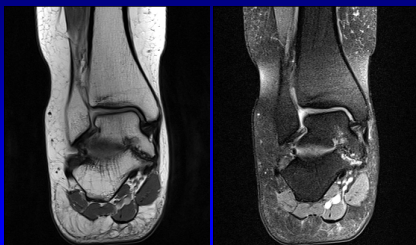
76

### Subtalar Coalition



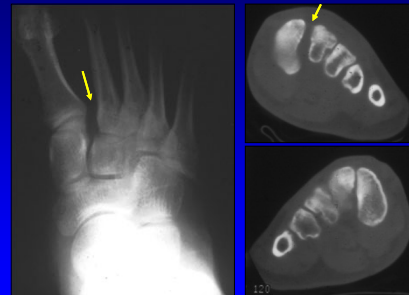77

### Subtalar Coalition

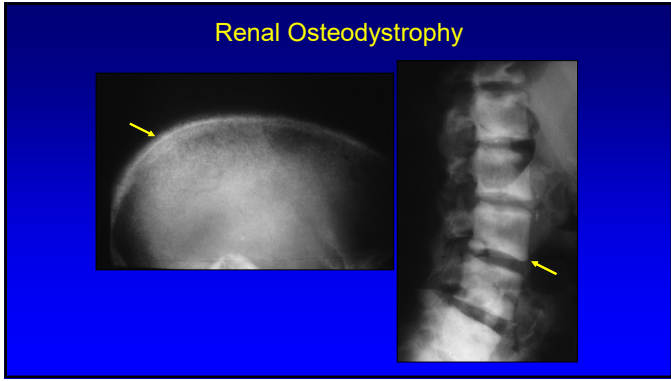


78

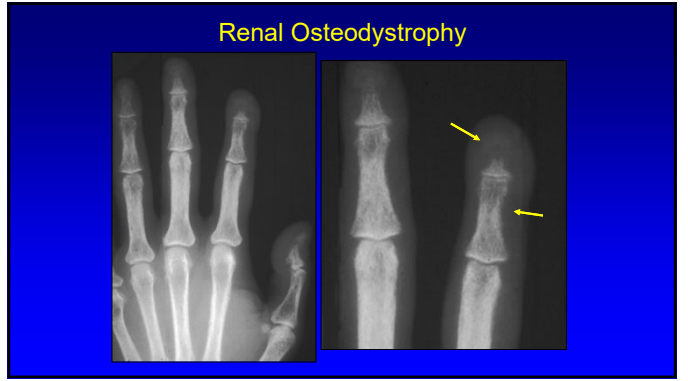
### Lisfranc Ligament Injury



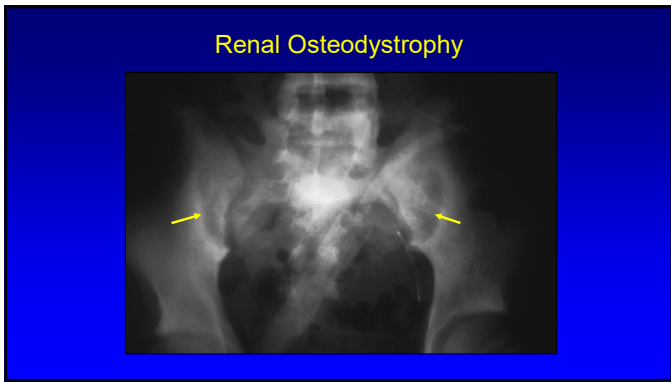
79



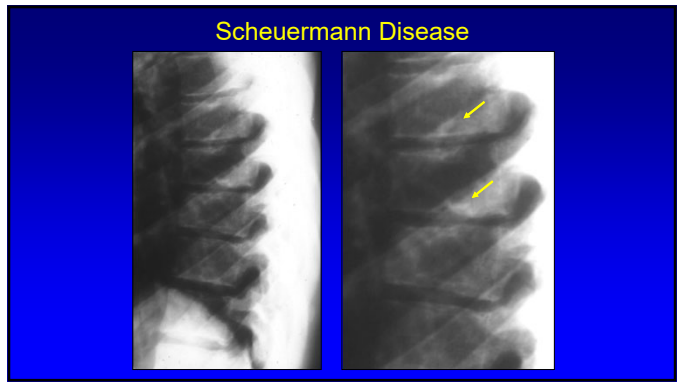
80



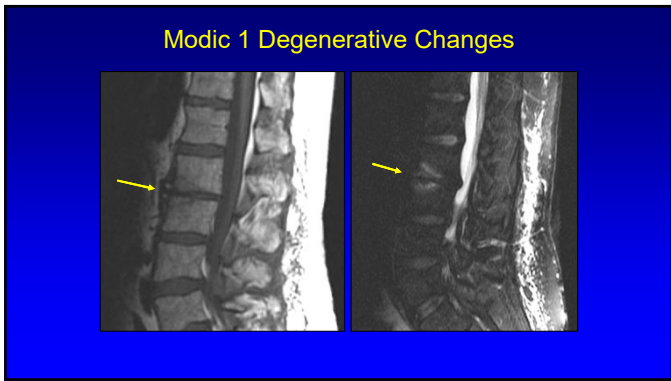
81



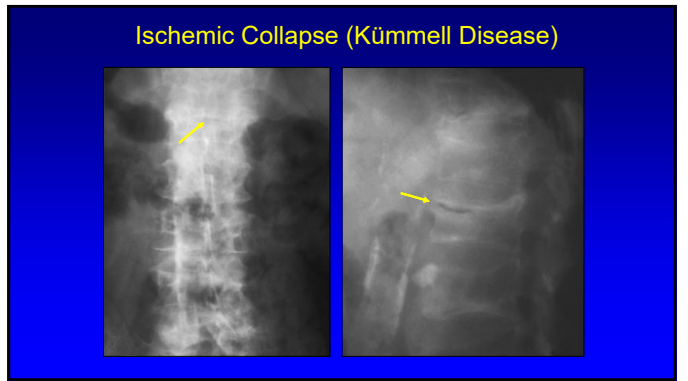
82



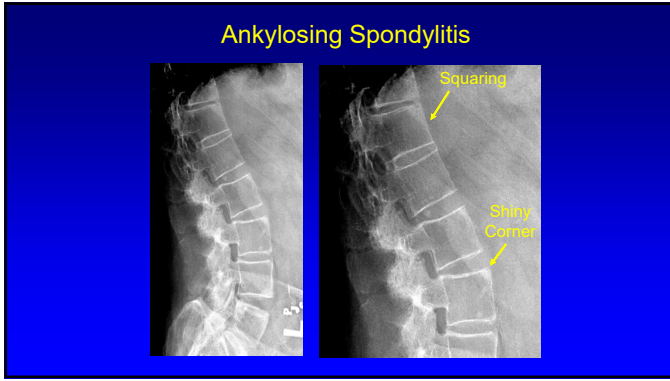
83



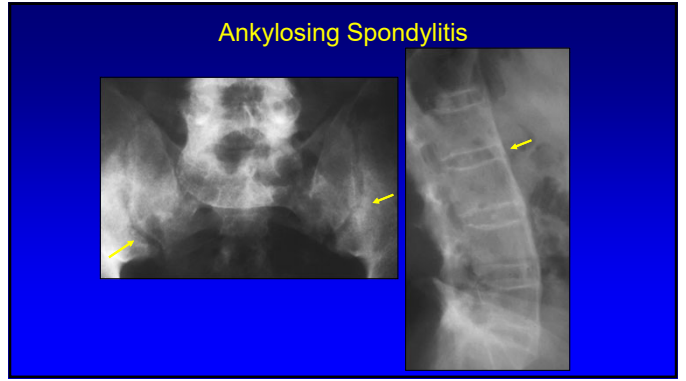
84



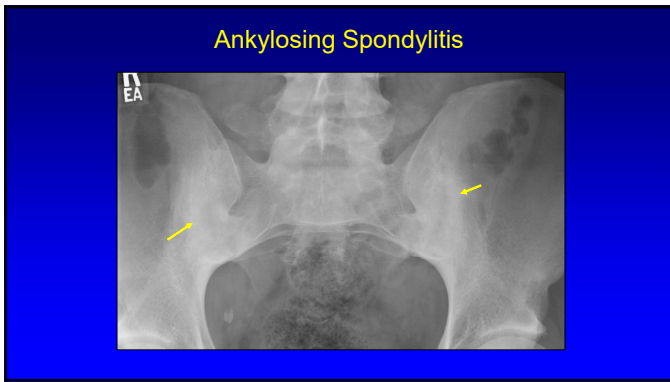
85



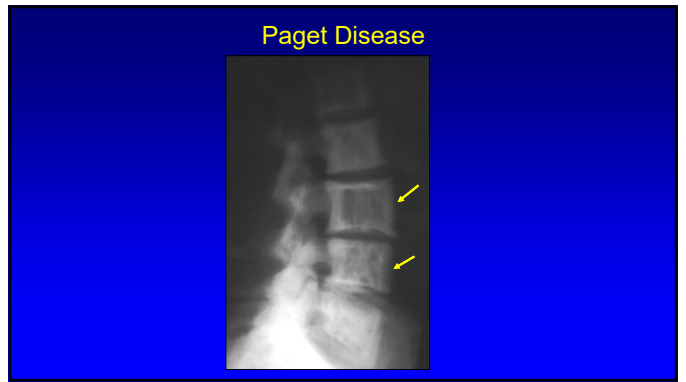
86



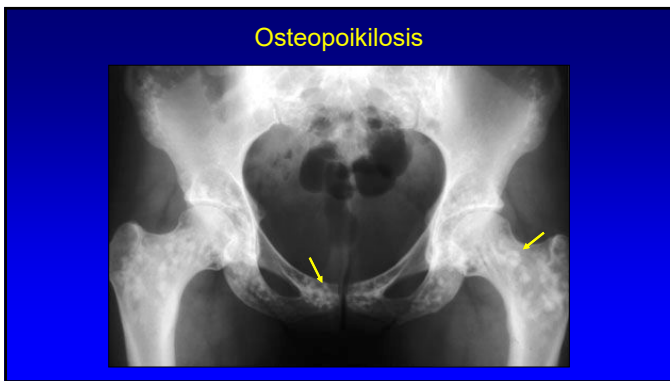
87



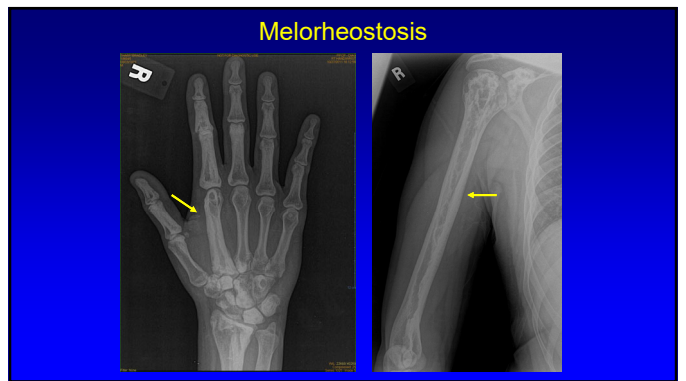
88



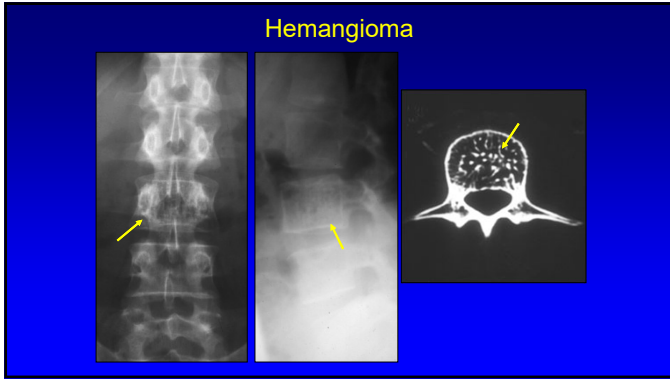
89



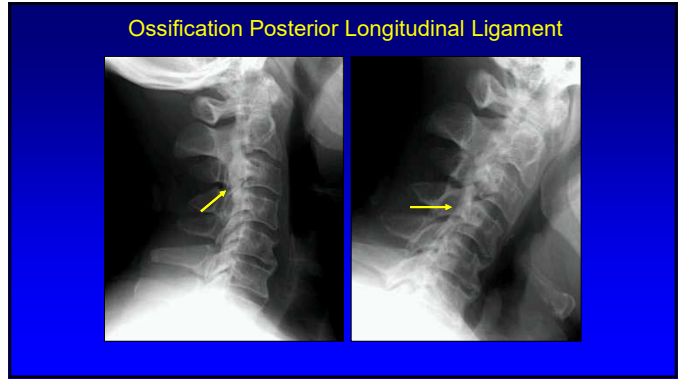
90



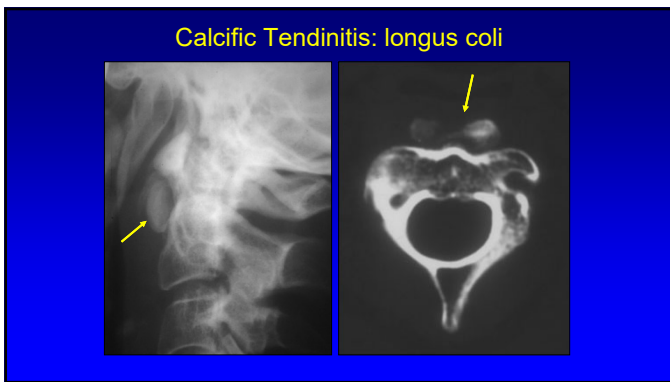
91



92



93



94

### Thank you!



NYC      Ann Arbor      San Diego

Syllabus on line and other educational material:  
[www.jacobsonmskus.com](http://www.jacobsonmskus.com)



The slide features three landscape photographs: New York City, Ann Arbor, and San Diego. Below the photos is a text box with the website URL and a QR code.

103