

Musculoskeletal Case Conference

Jon A. Jacobson, MD
FACR, FSRU, FAIUM, RMSK

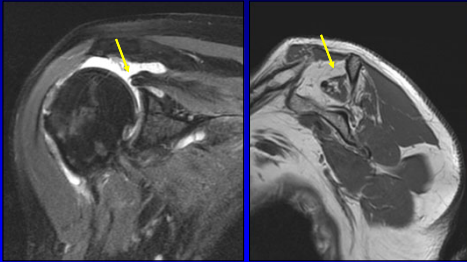
Professor of Radiology
Lenox Hill Radiology, NYC
University of California, San Diego

Scan for lecture syllabus



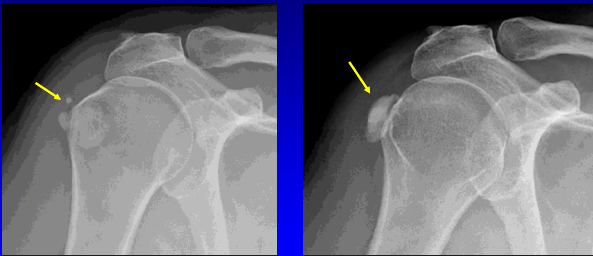
1

Full-thickness Tear: supraspinatus



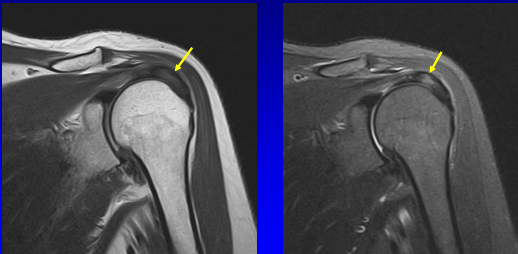
2

Calcium Hydroxyapatite Deposition



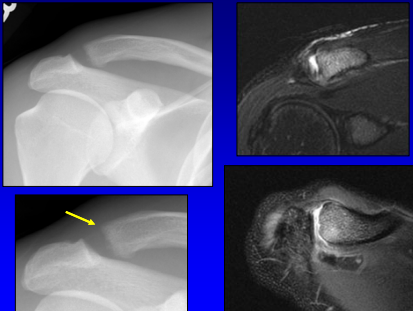
3

Tendinosis: supraspinatus



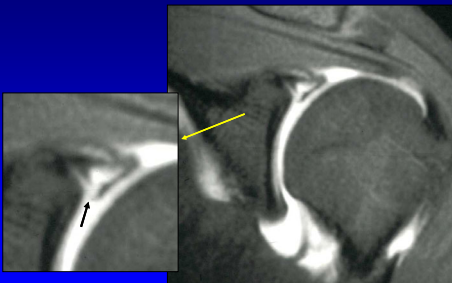
4

Post-traumatic Osteolysis



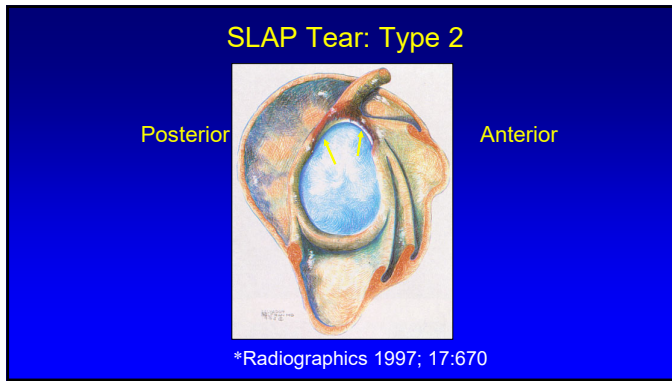
5

SLAP Tear: Type 2

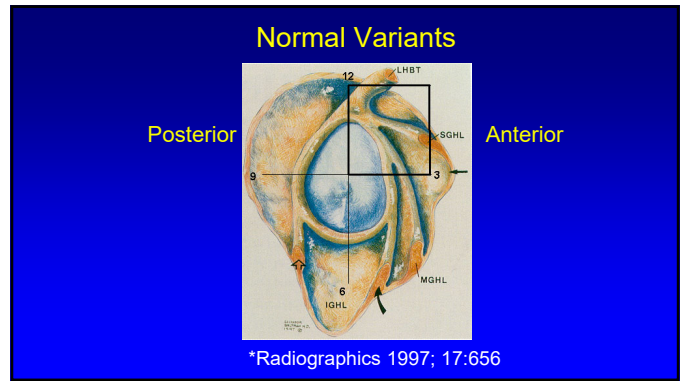


Coronal-oblique T1w fat-sat

6



7



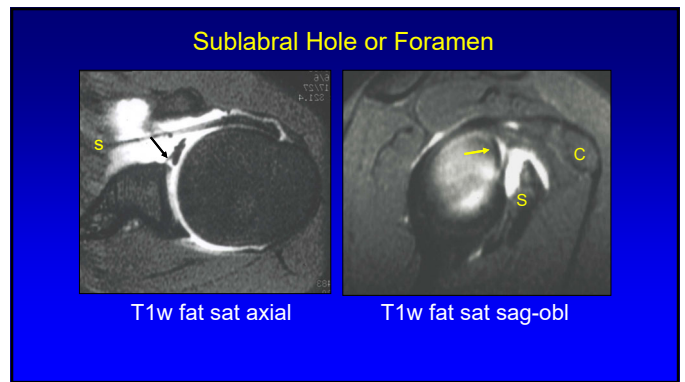
8

Sublabral Hole or Foramen:

- Normal variant:
 - Anterosuperior labrum: 1 - 3 o'clock
- Labrum not attached to glenoid*
- Contrast between labrum and glenoid

*Radiology 1996; 199:537

9



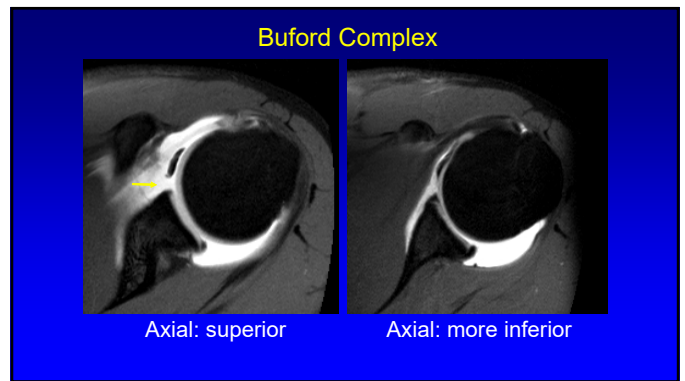
10

Buford Complex:

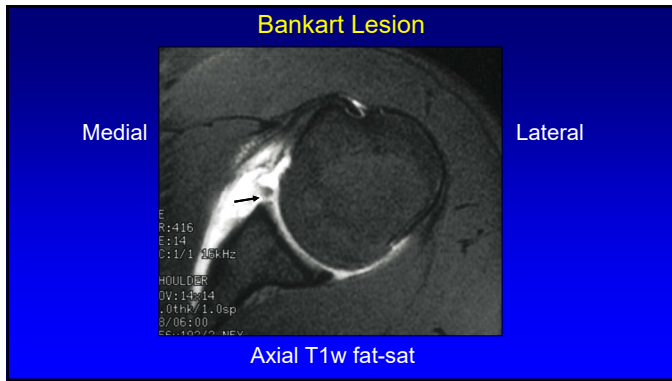
- Normal variant
- Absence of anterosuperior labrum
- Thickened, cord-like middle glenohumeral ligament

AJR 1996; 166:869

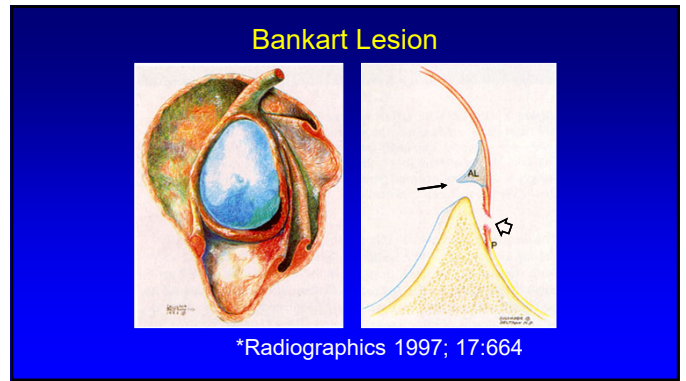
11



12



13



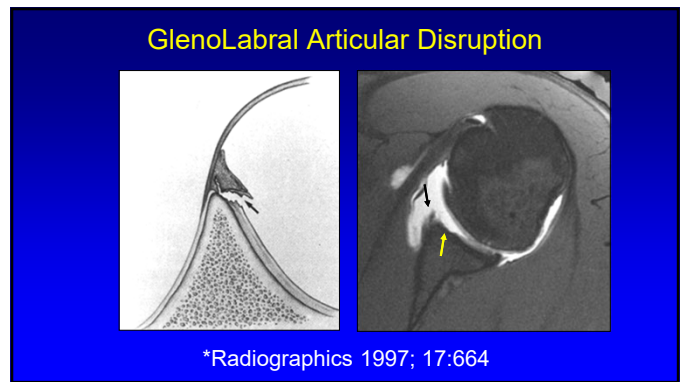
14

GLAD Lesion:

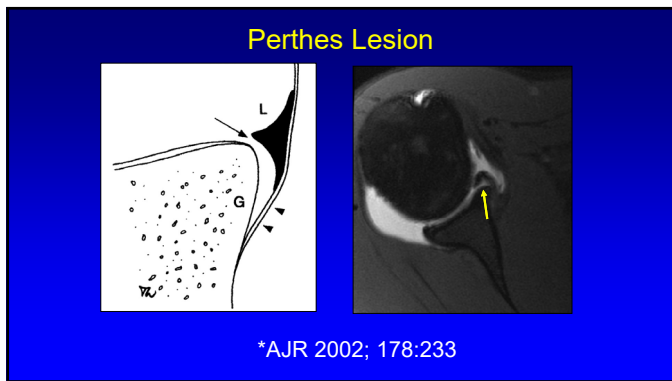
- GlenoLabral Articular Disruption
- Superficial anteroinferior labral tear
- Articular cartilage damage
- Anterior bundle of IGHL intact (partial)
- Intact periosteum: little displacement

*Radiographics 1997; 17:657

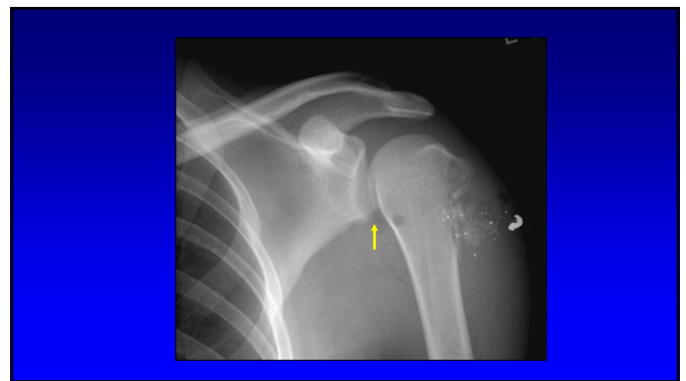
15

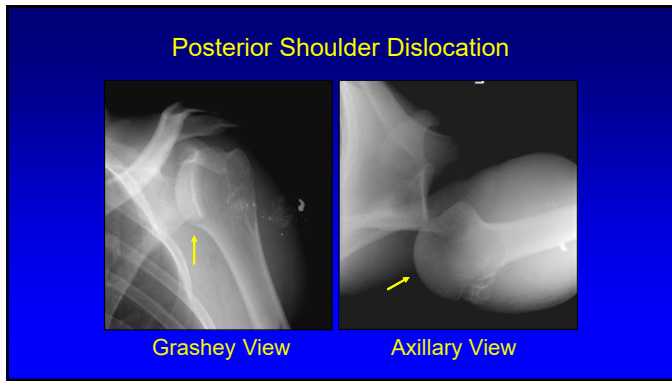


16

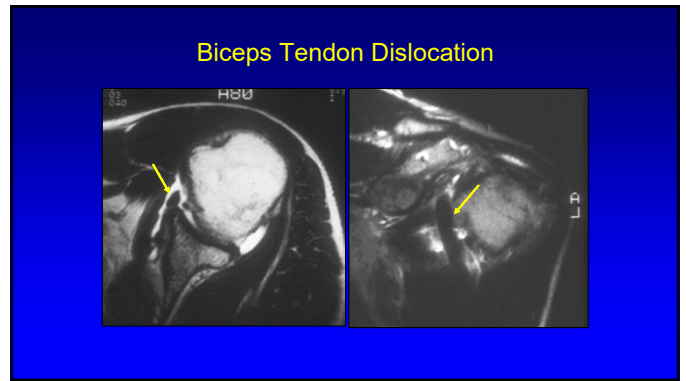


17

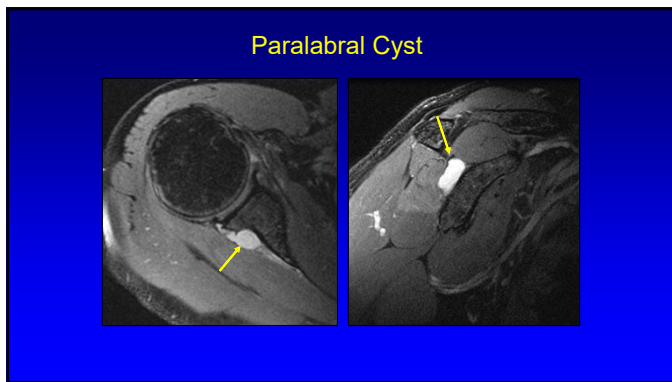




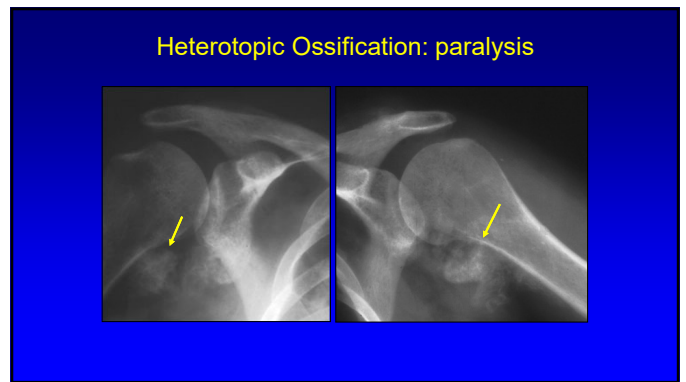
19



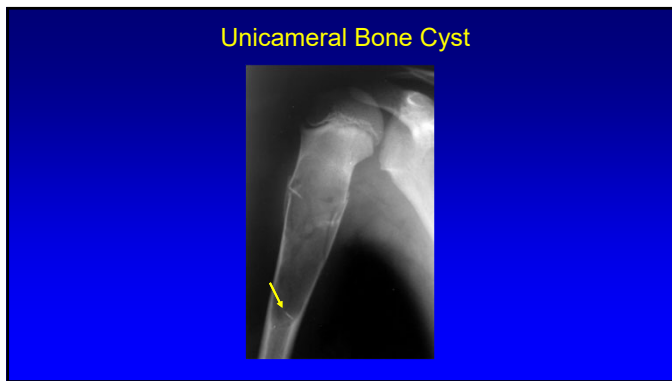
20



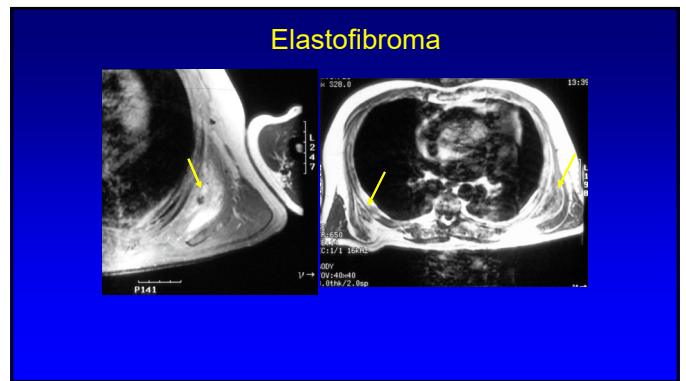
21



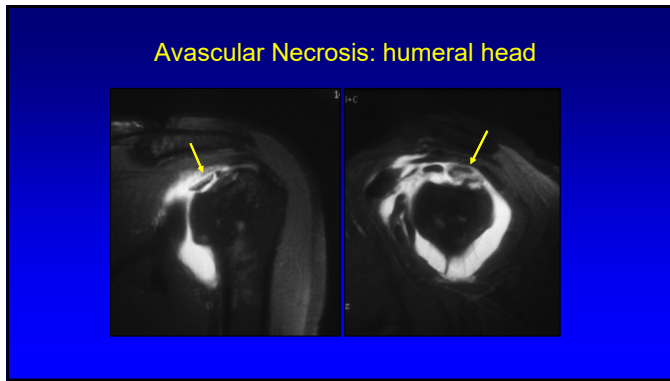
22



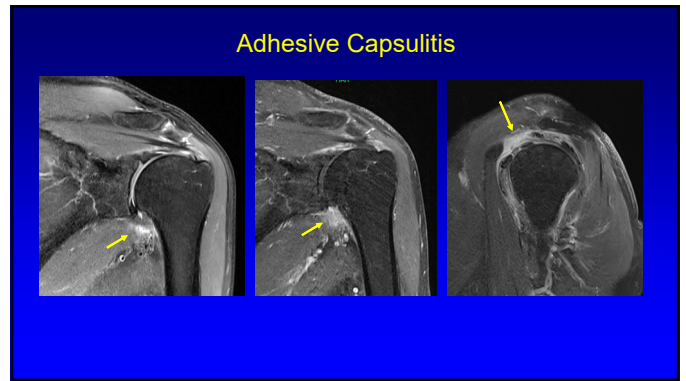
23



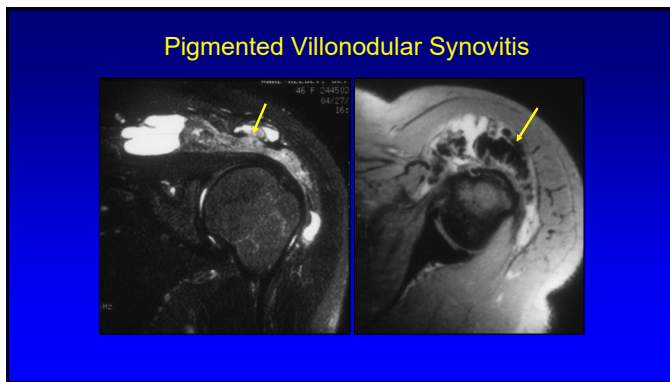
24



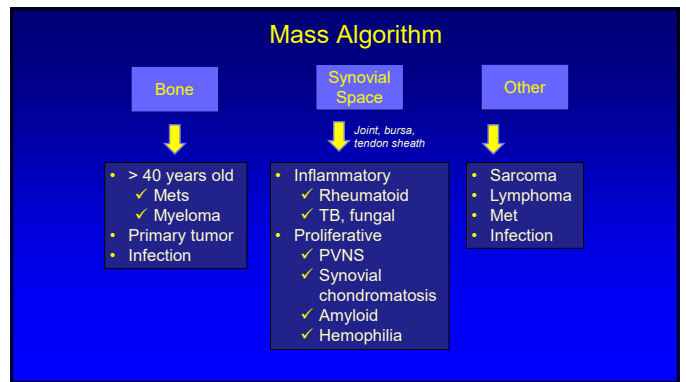
25



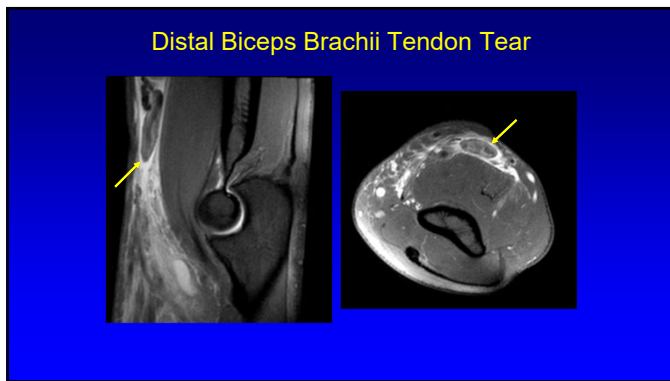
26



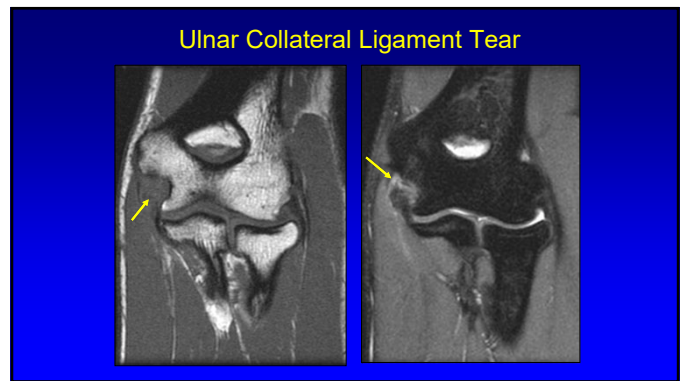
27



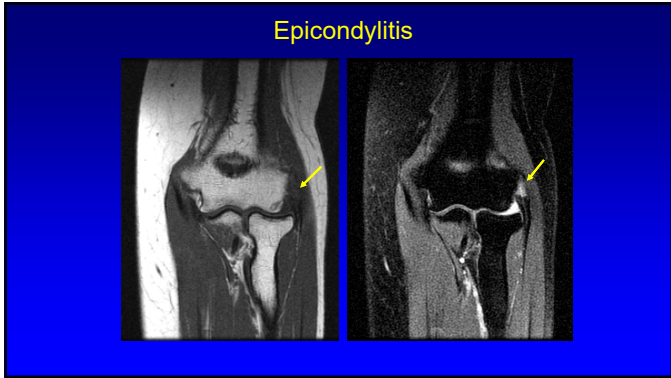
28



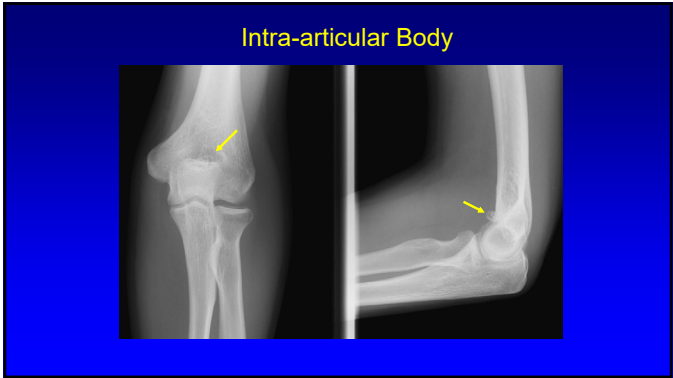
29



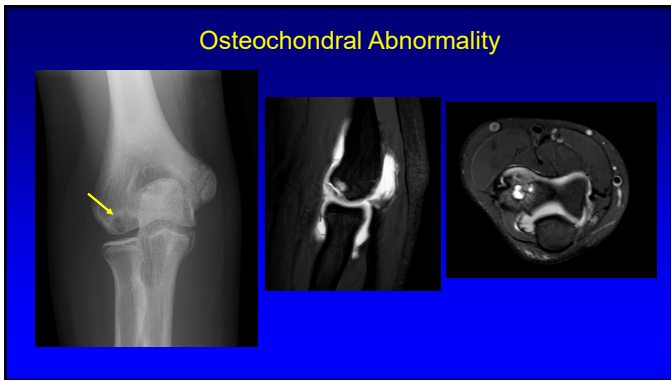30



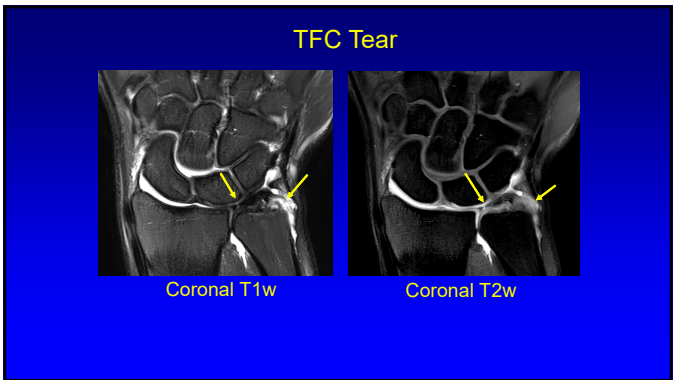
31



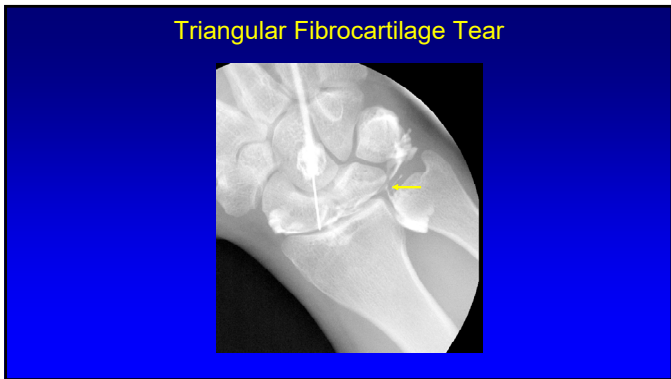
32



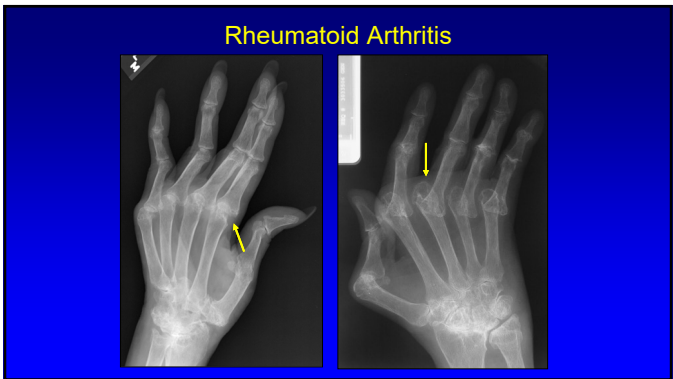
33



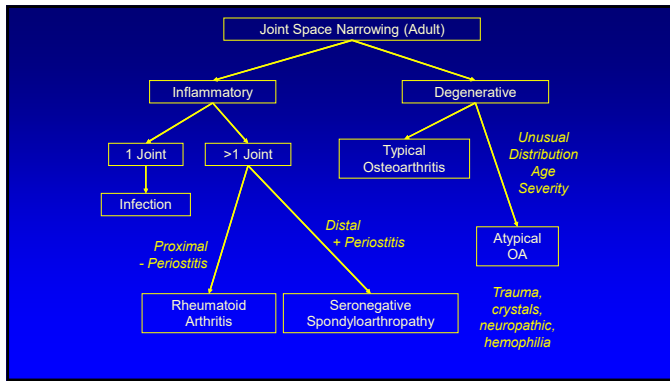
34



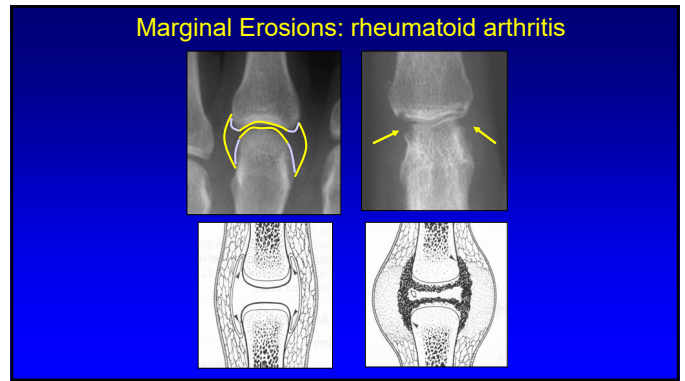
35



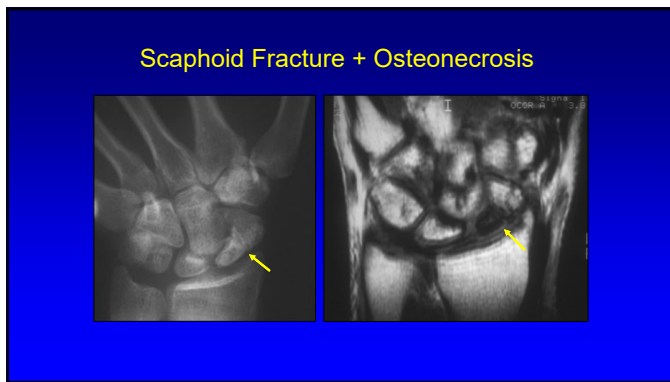
36



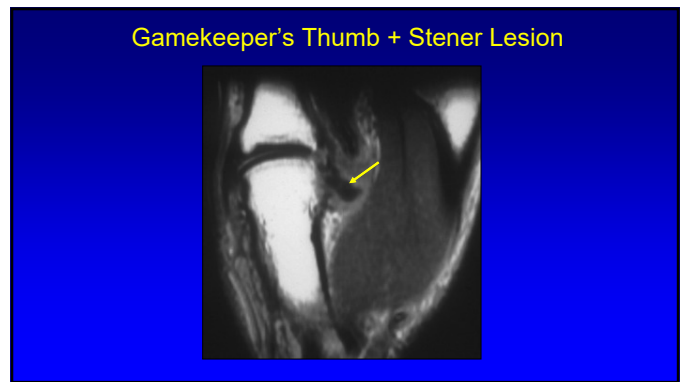37



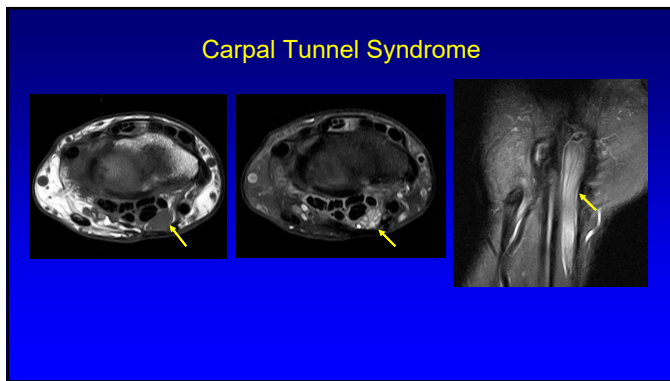
38



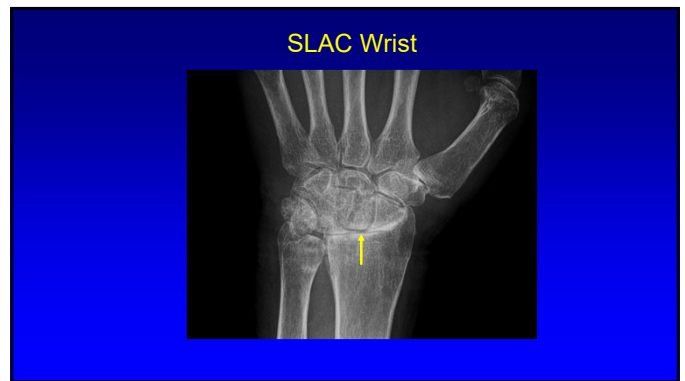39



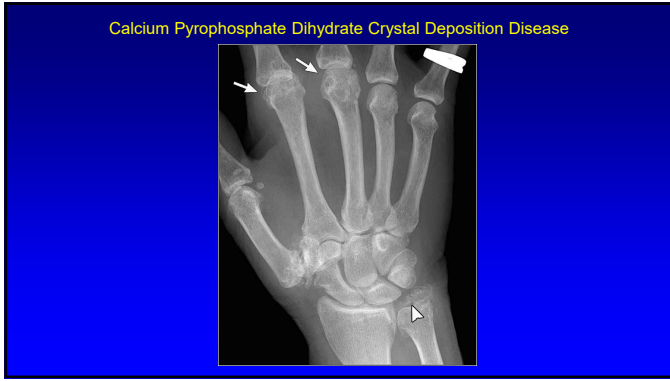40



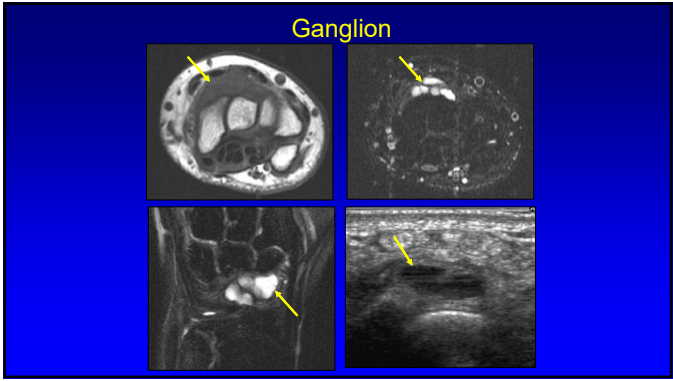
41



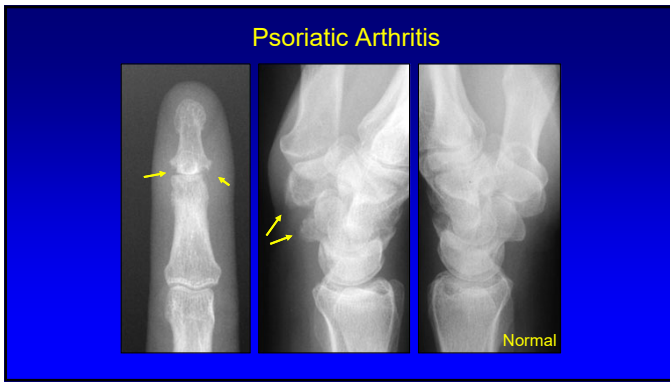
42



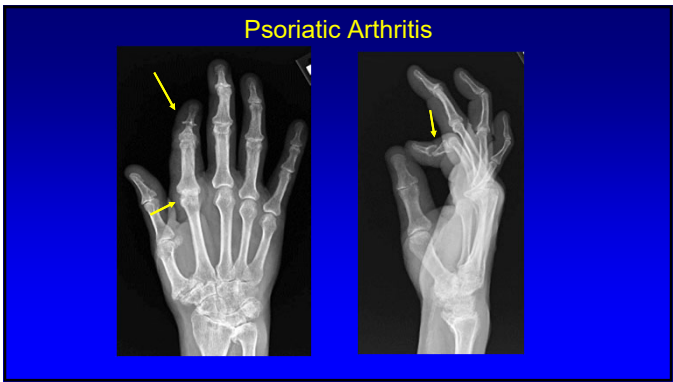
43



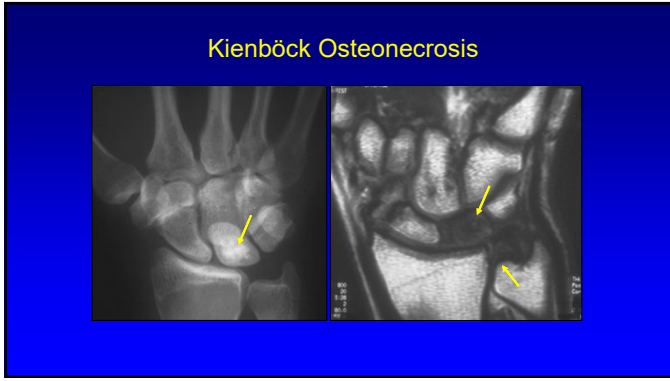
44



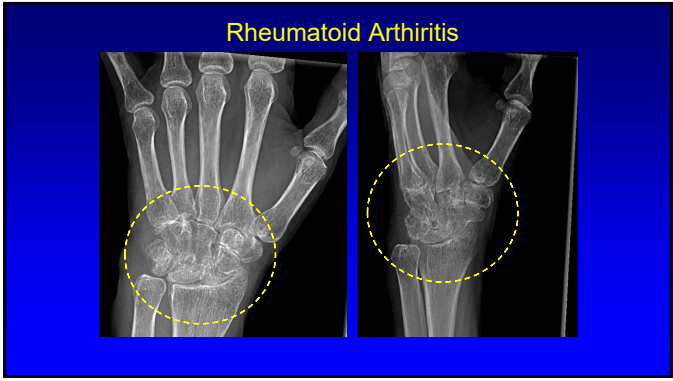
45



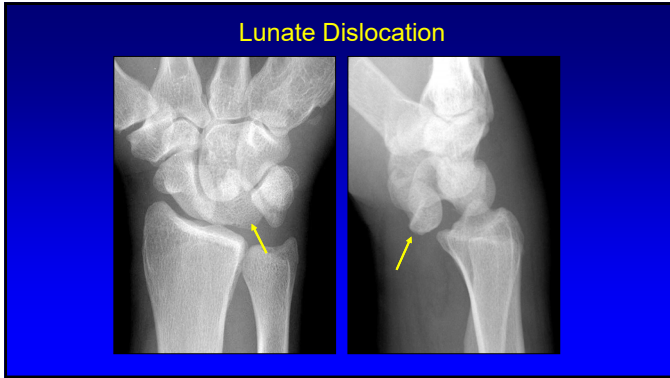
46



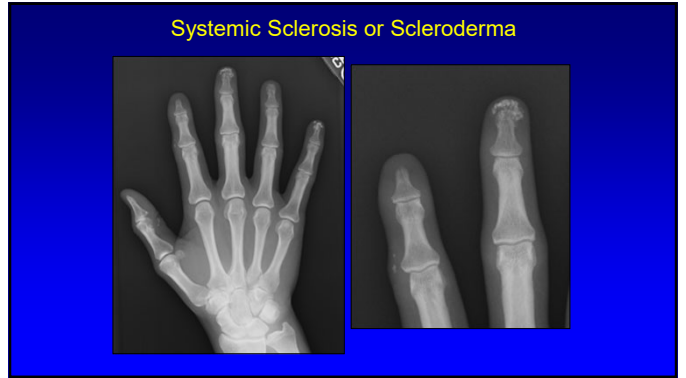47



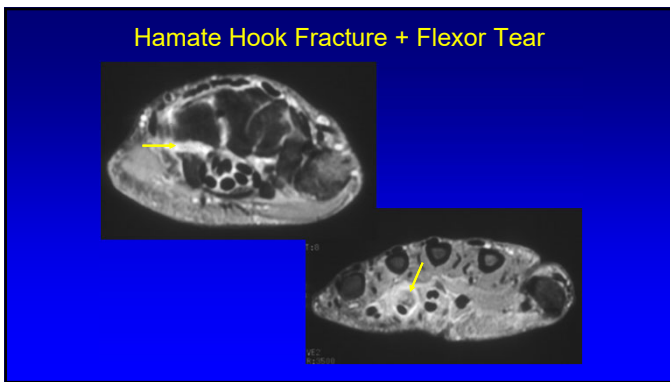
48



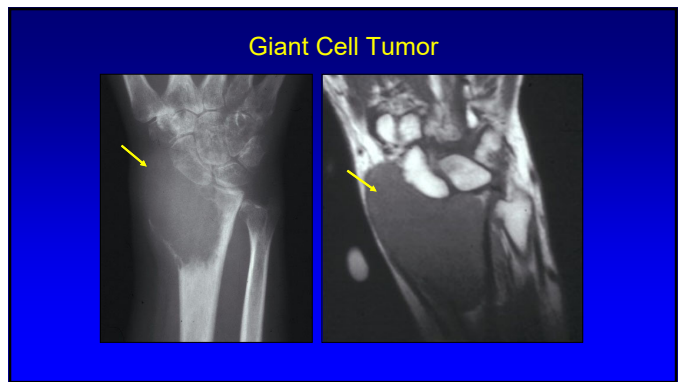
49



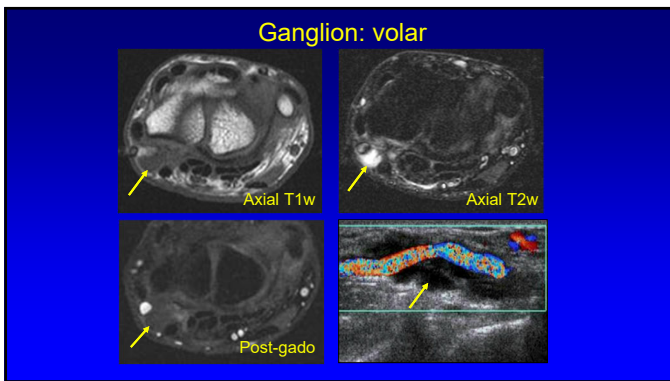
50



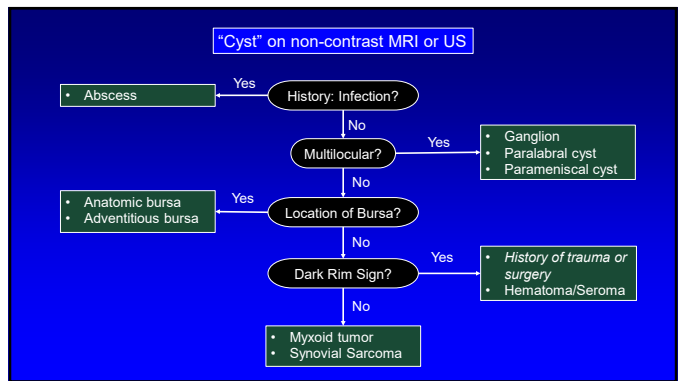
51



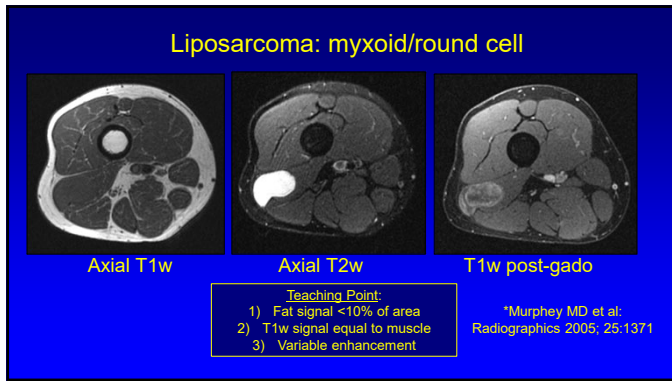
52



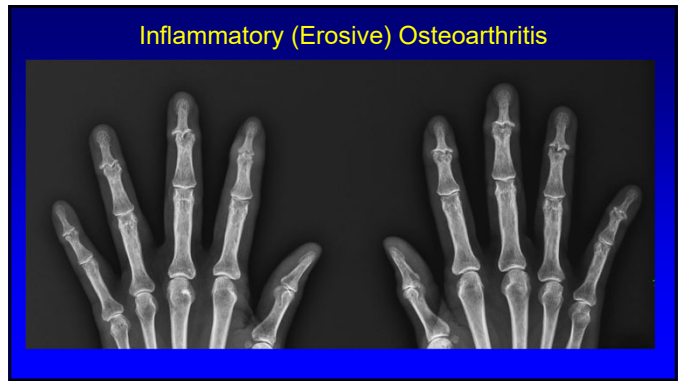53



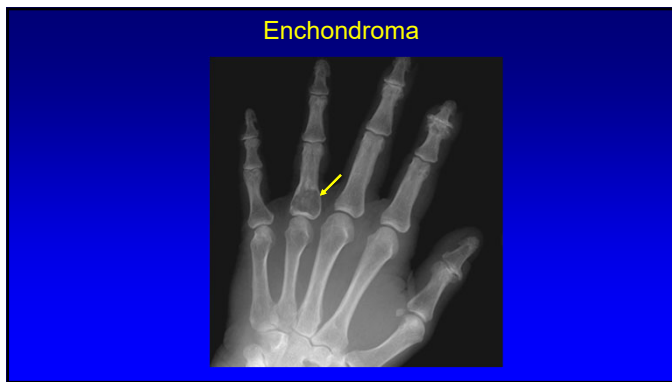54



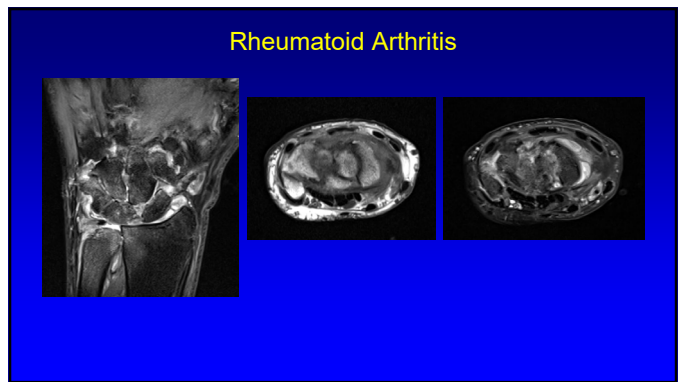
55



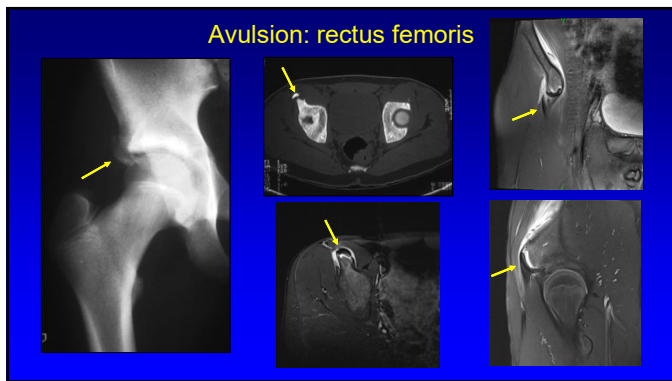
56



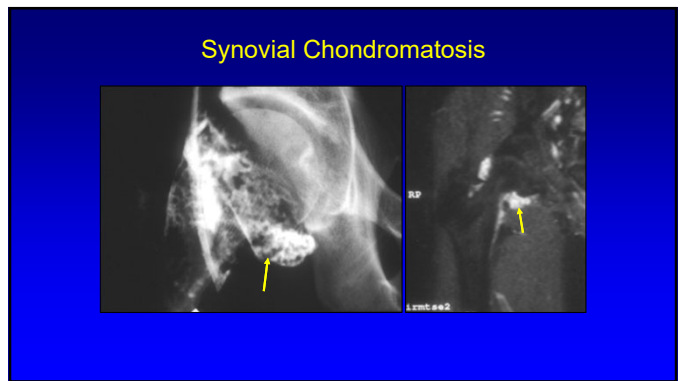
57



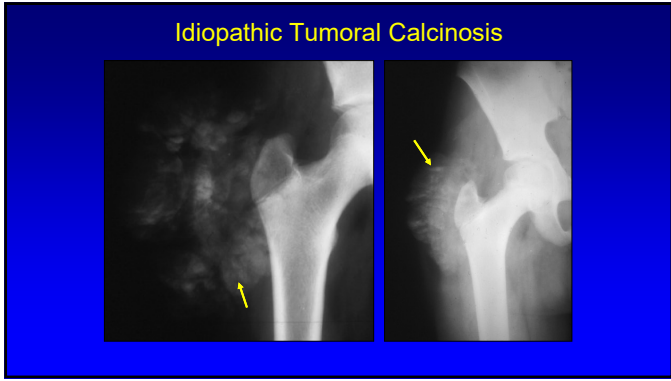
58



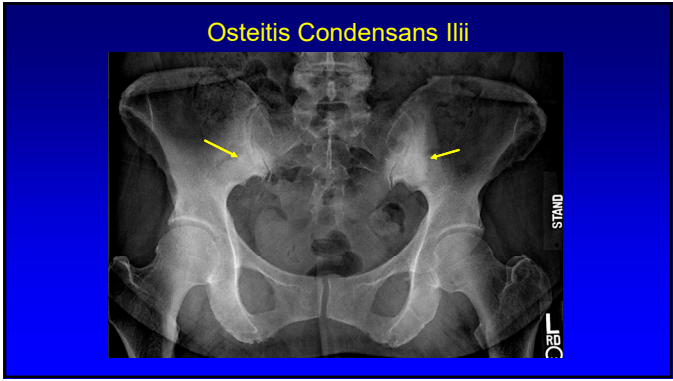
59



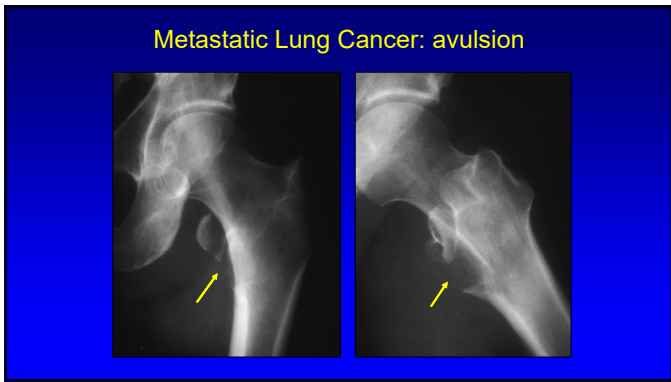
60



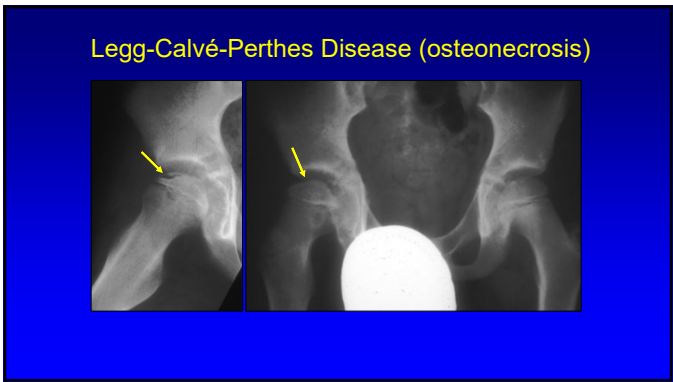
61



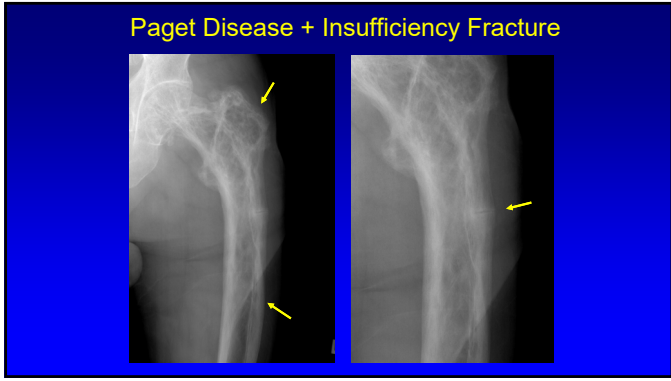
62



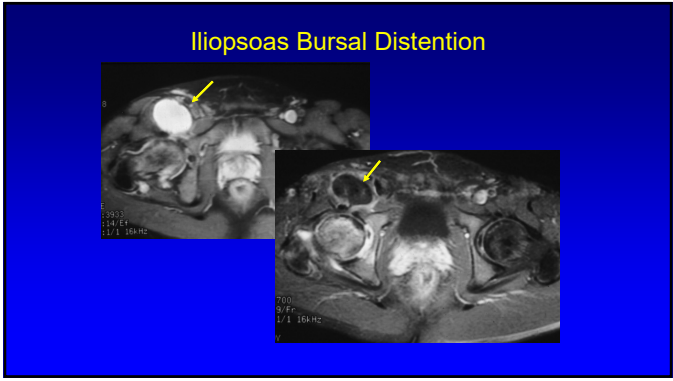
63



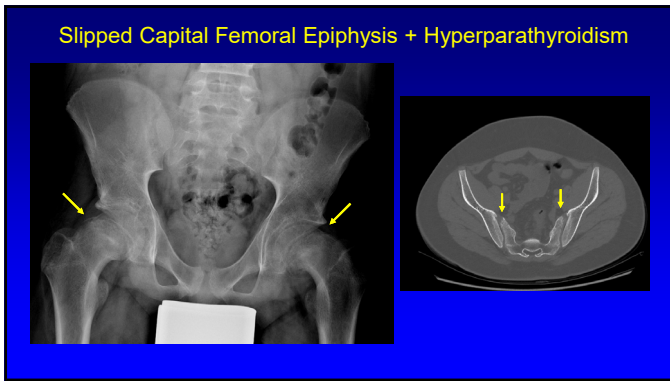
64



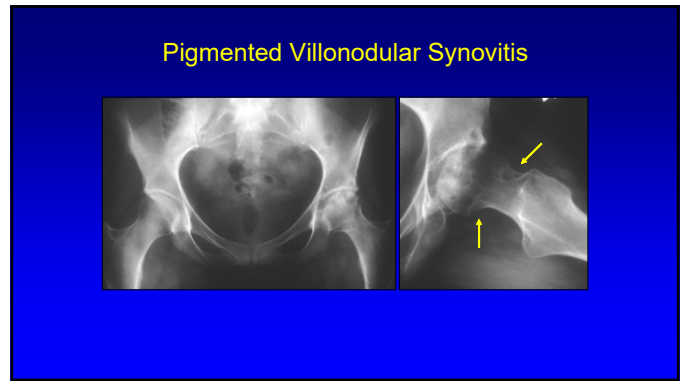
65



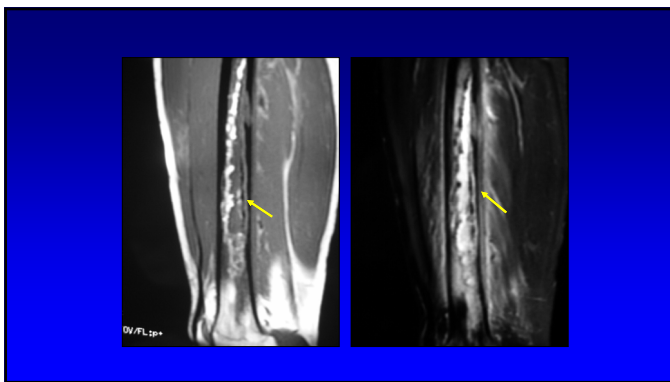
66



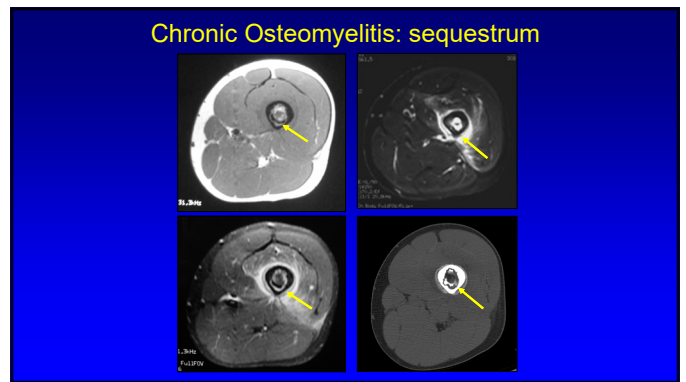
67



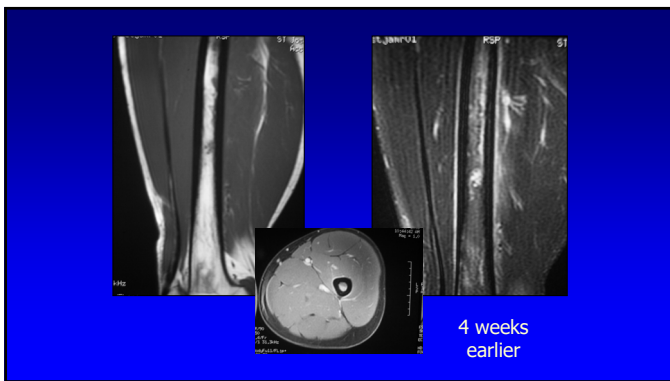
68



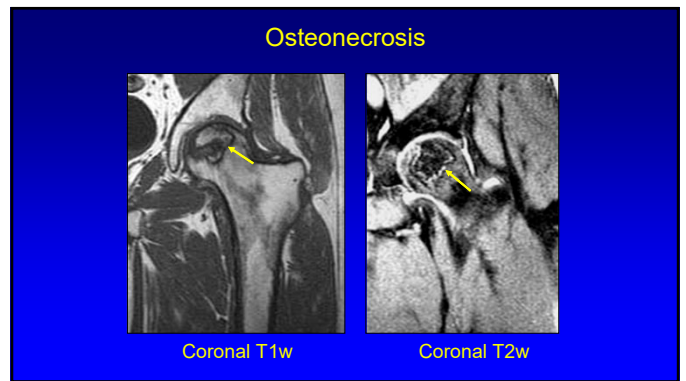
69



70

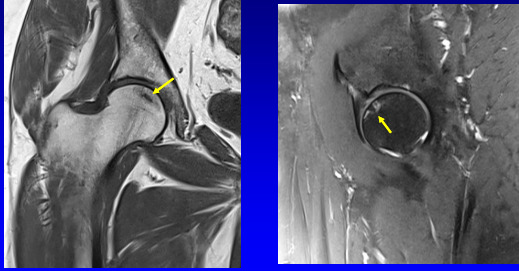


71

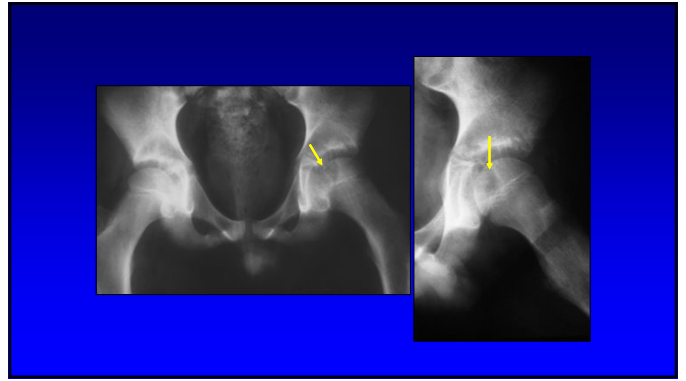


72

Insufficiency Fracture

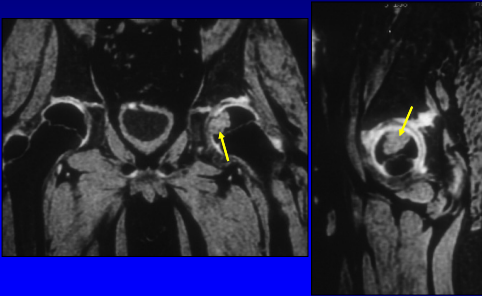


73



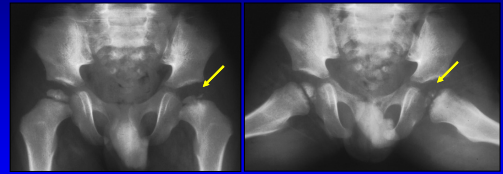
74

Chondroblastoma



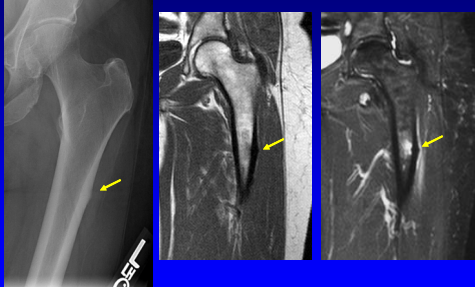
75

Meyer Dysplasia

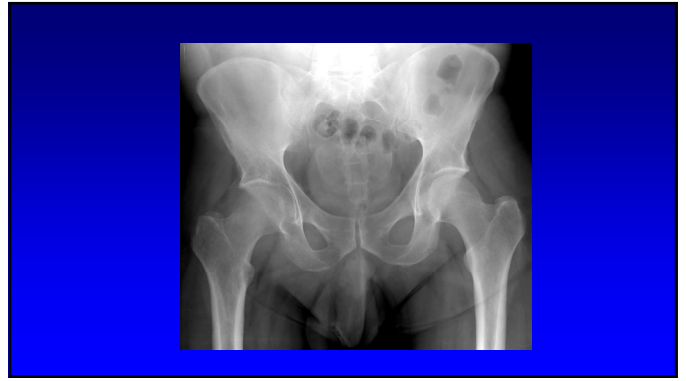

76

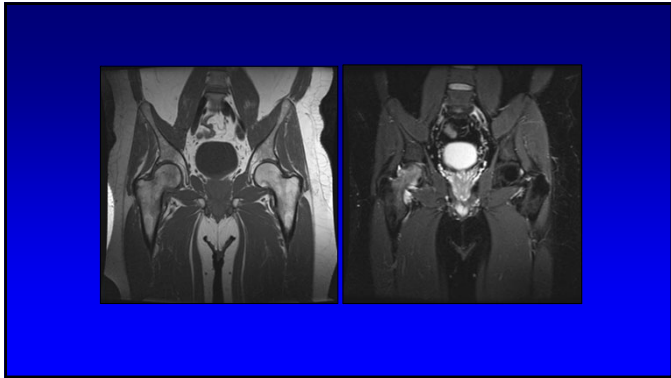
Insufficiency Fracture: bisphosphonate



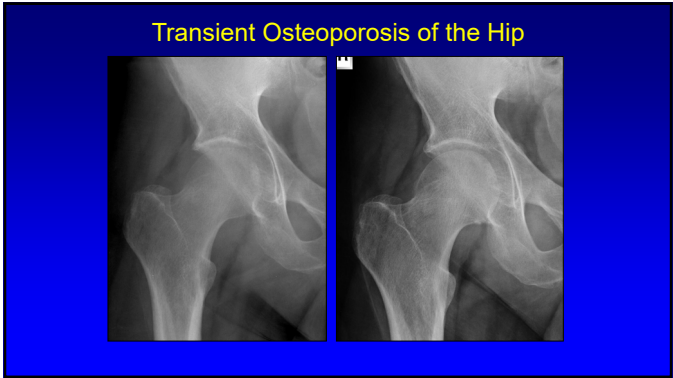
77



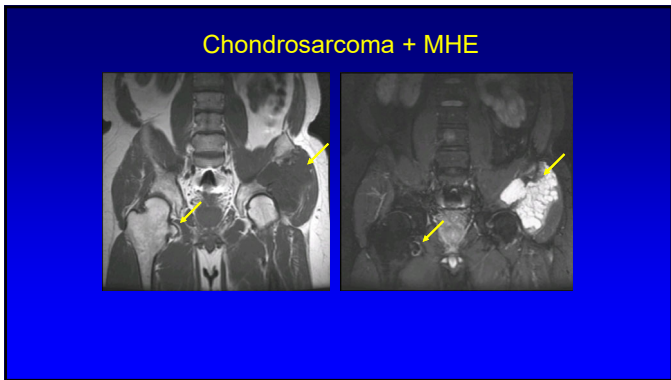
78



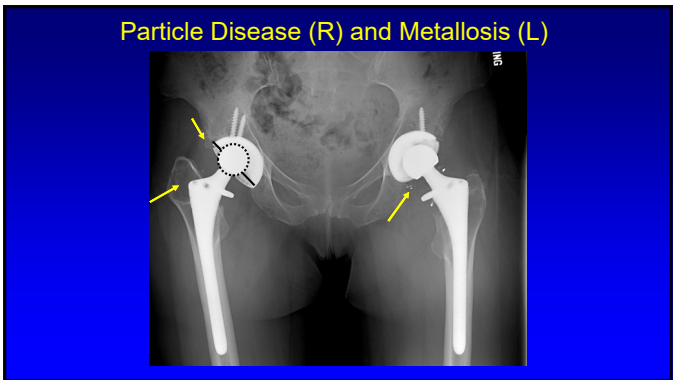
79



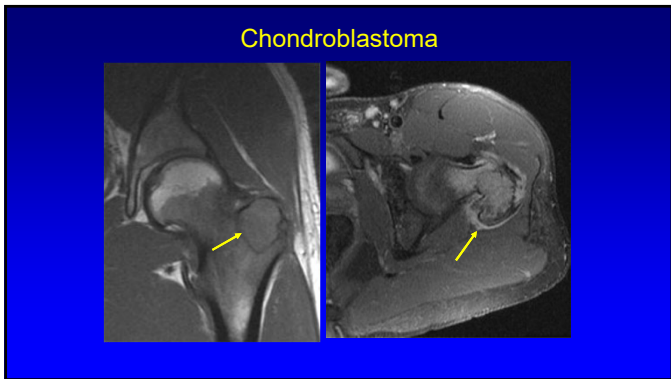
80



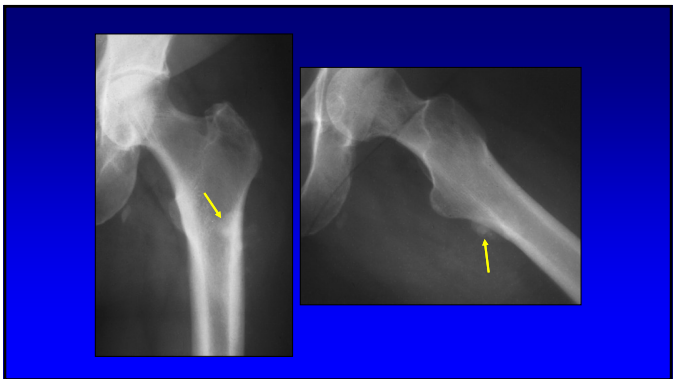
81



82

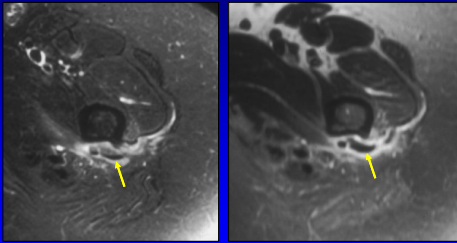


83

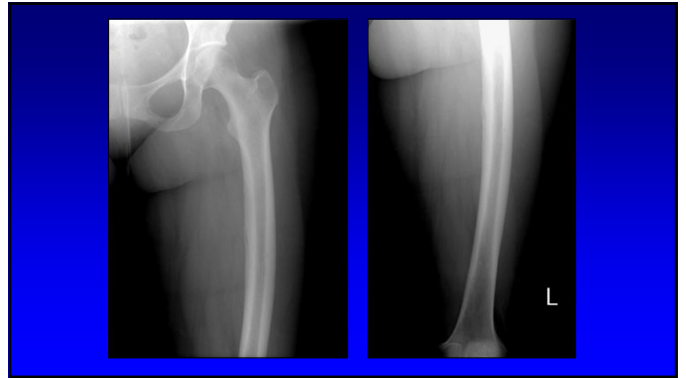


84

Gluteus Maximus: calcific tendinitis

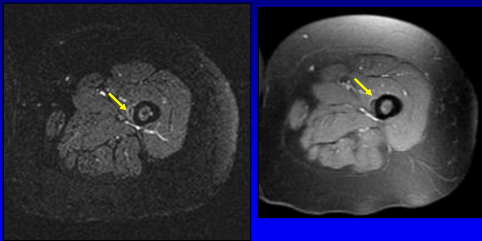


85



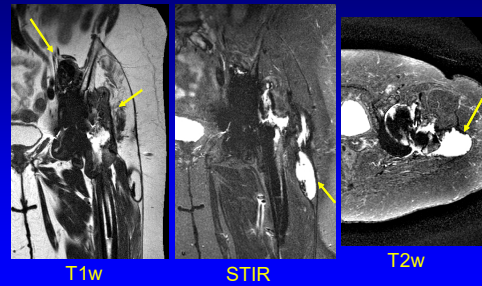
86

Thigh Splints

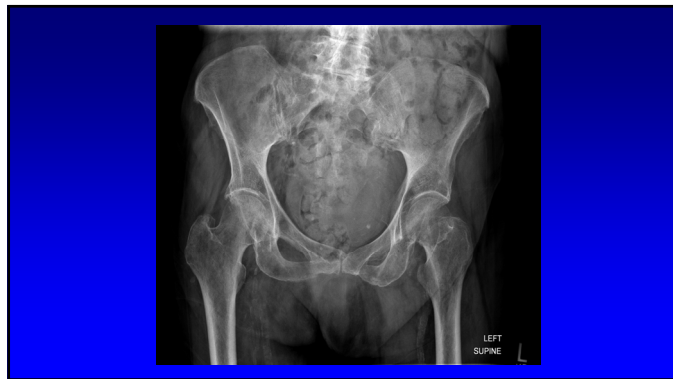


87

Metal-on-Metal: Pseudotumor

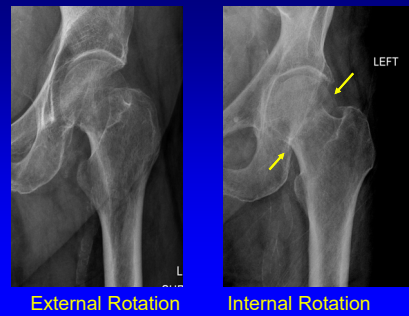


88



89

Femoral Neck Fracture



90

Femoral Neck Fracture:

- Internal rotation radiograph essential
- Goal: diagnose non-displaced femoral neck fracture
- Garden Classification: 1 – 4
 - 1 & 2: non-displaced → percutaneous pins
 - 3 & 4: displaced → arthroplasty (risk of AVN)
- With osteopenia, MRI necessary
 - CT not effective

91

Garden Classification

1 2
Valgus Impacted d
3 4

Type I: Impacted fracture
Type II: Non-displaced fracture
Type III: Partially displaced
Type IV: Displaced fracture. Vertical fracture line generally suggests poorer prognosis.

92

Femoral Neck Fracture: Garden 1

93

Femoral Neck Fracture: now displaced

Valgus Impacted Garden 1
Oops

94

Amyloidosis

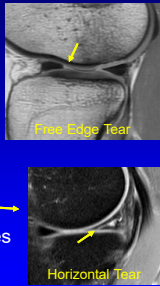
95

Bucket-handle Tear: medial meniscus

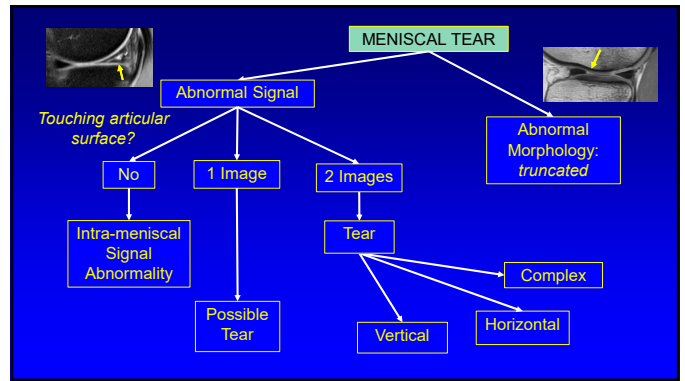
96

Meniscus Tear: MRI criteria

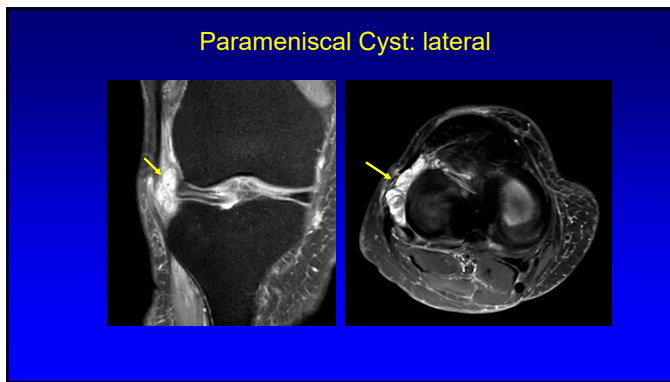
- Abnormal morphology
 - Truncation, absence
- Abnormal signal
 - Extends to articular surface (unequivocally)
 - Two consecutive or orthogonal images
 - "Two-slice-touch rule"



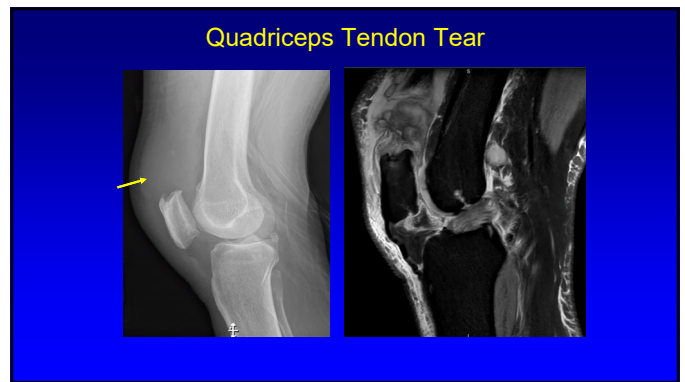
97



98



99



100