


Gamekeeper's Thumb

Jon A. Jacobson, MD
FACR, FSRU, FAIUM, RMSK

Professor of Radiology
Lenox Hill Radiology, NYC
University of California, San Diego



Syllabus PDF

1

Disclosures

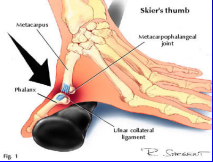
- Consultant: Bioclinica
- Book Royalties: Elsevier
- Not relevant to this lecture

See www.jacobsonmskus.com for syllabus other educational material


2

Gamekeeper's or Skier's Thumb

- Injury: ulnar collateral ligament of first MCP joint
- Chronic (gamekeeper's thumb): historically in Scottish gamekeepers
- Acute (skier's thumb): acute hyperabduction



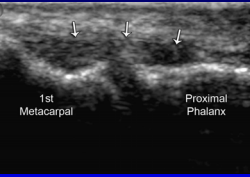
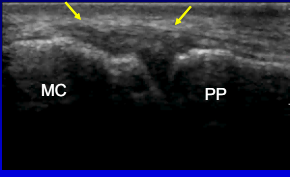
Acute Mechanism



Chronic Mechanism

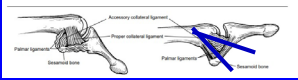
3

Ulnar Collateral Ligament: thumb






1st Metacarpal Proximal Phalanx MC PP

Note: sliding of adductor aponeurosis with isolated interphalangeal joint flexion



4

Ulnar Collateral Ligament: thumb


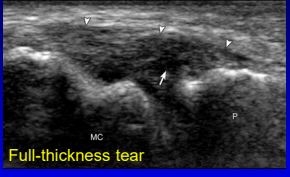
Normal Sprain Partial Tear Nondisplaced Complete Tear Displaced Complete Tear (Stener Lesion)

(+ fracture)


RadioGraphics 2006;26:1007

5

UCL: tears

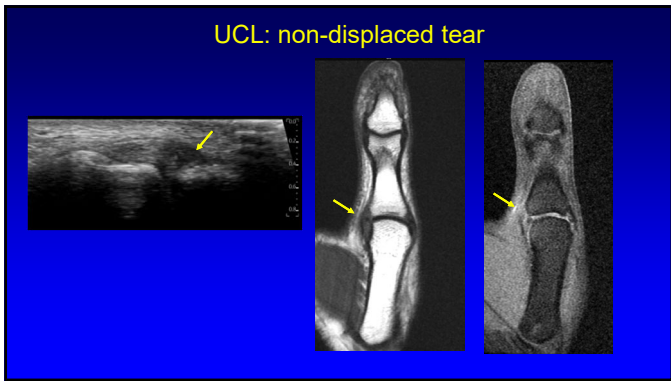
Partial-thickness tear Full-thickness tear



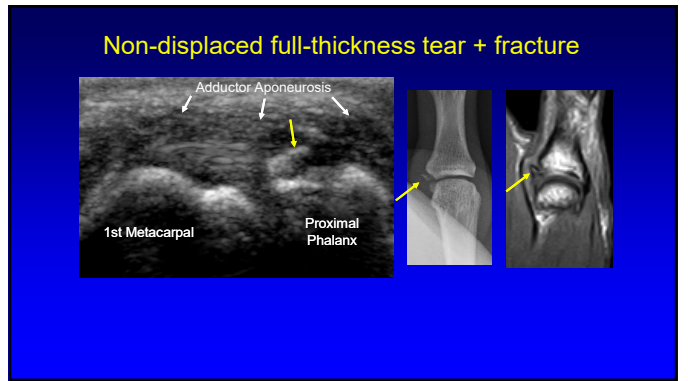
Normal

Teaching Point:
90% of UCL injuries are distal

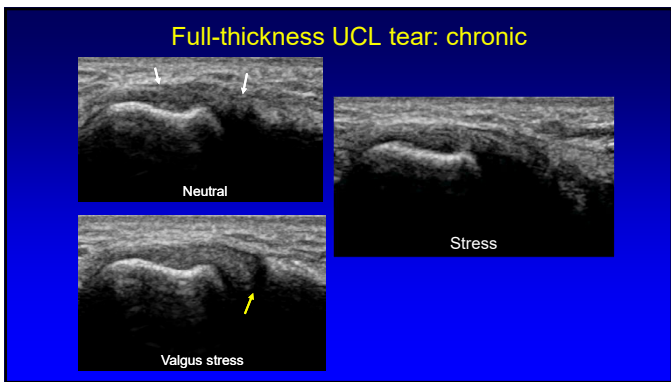
6



7



8



9

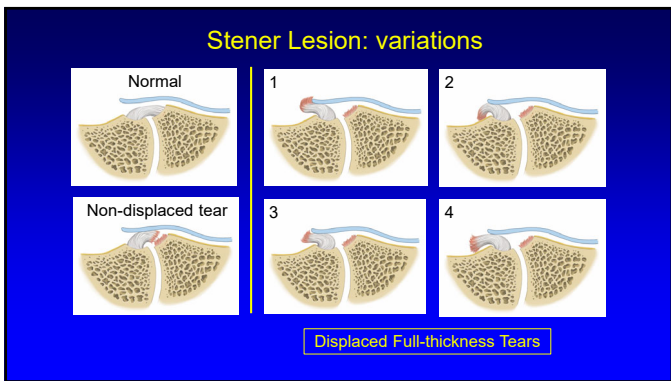
Stener Lesion

- Displaced proximal stump of UCL
 - Hypoechoic & round
 - Proximal to MCP joint
 - At proximal edge of adductor pollicis aponeurosis
- No tissue spanning MCP joint
- "Yo-yo on a string" sign
- Ultrasound: 100% accuracy

*Melville D. et al. Skeletal Radiology 2013; 42:667

Yellow arrows: Stener
White arrows: aponeurosis

10



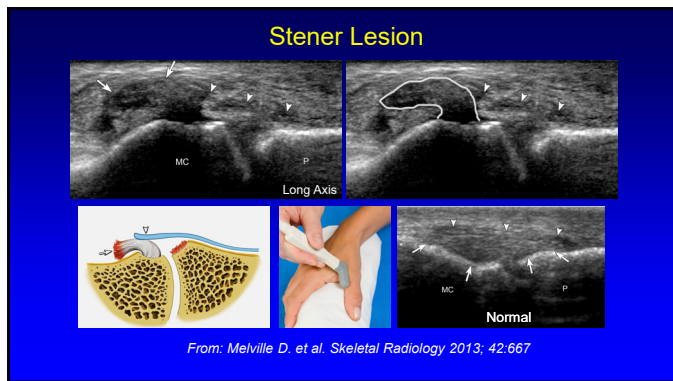
11

Stener Lesion: dynamic

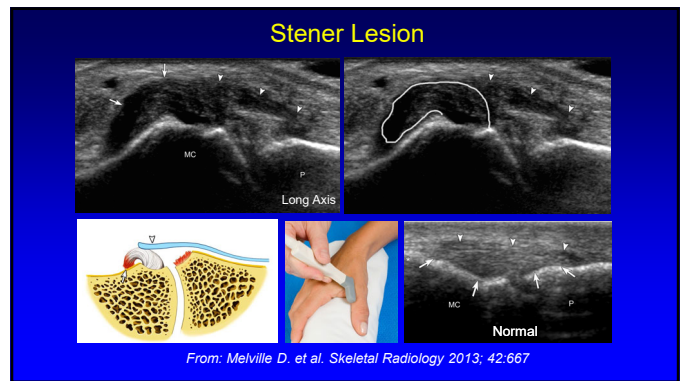
White arrows = adductor aponeurosis
Yellow arrows = Stener lesion

Teaching Point:
Note importance of active IP joint flexion at imaging showing aponeurosis

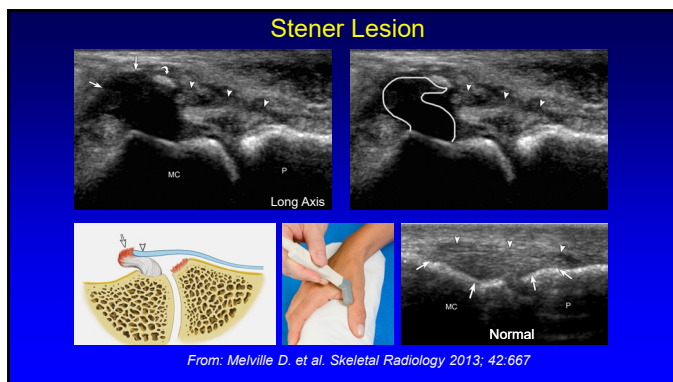
12



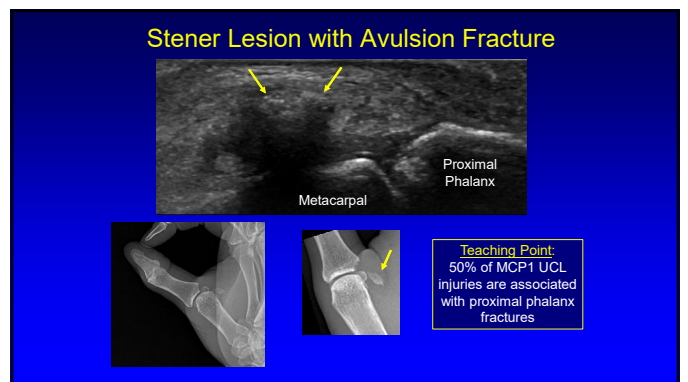
13



14



15



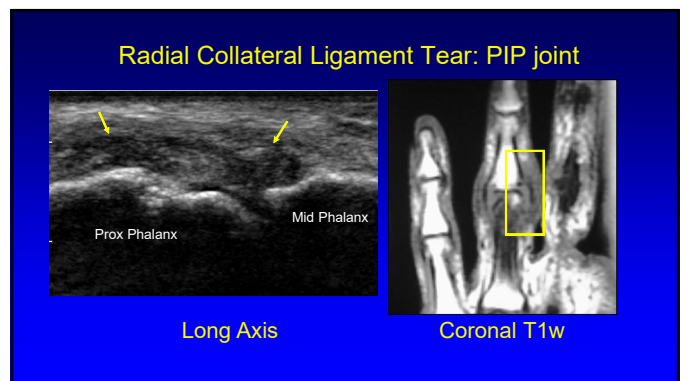
16

Adductor Policis Aponeurosis

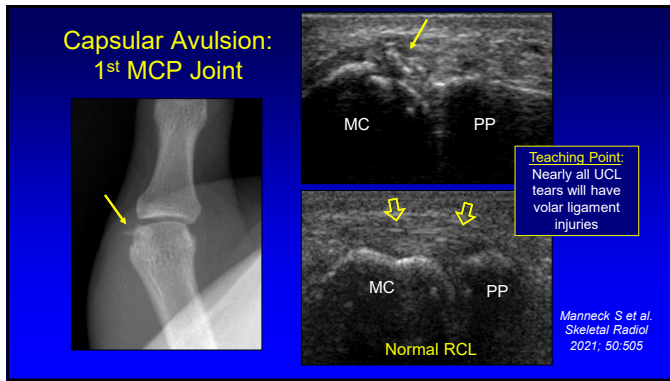
- Superficial to UCL of 1st MCP
- Examine long axis to UCL with passive 1st IP joint flexion/extension
- Commonly injury with Gamekeeper's thumb
 - Hypochoic and thickened
- Isolated injury: uncommon
 - Diffusely hypochoic thickened

Long Axis to UCL

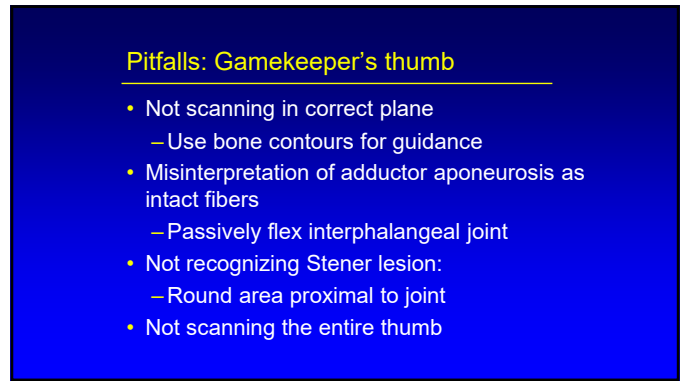
17



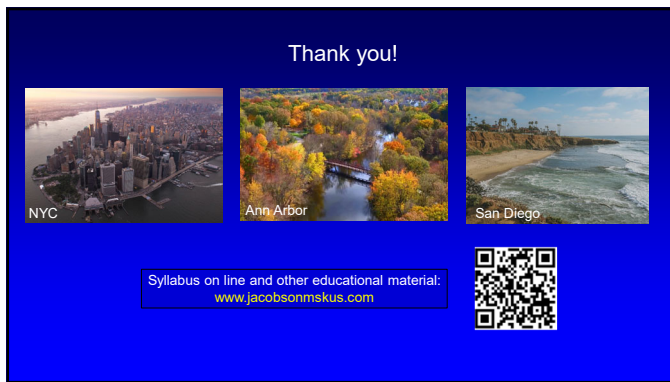18



19



20



21