

# Ultrasound of Common Ankle and Foot Pathology

Jon A. Jacobson, M.D.

Professor of Radiology  
Section Chief of Musculoskeletal Imaging



1

## Outline:

- Tendon Pathology
- Ligament Pathology
- Inflammation
- Masses

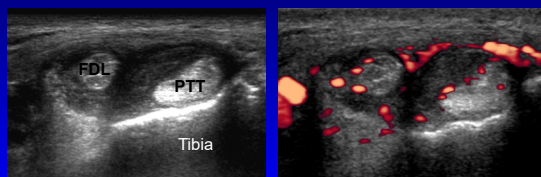
2

## Tenosynovitis: US

- Fluid distending tendon sheath
  - Anechoic or hypochoic
  - May be heterogeneous, complex
- Synovial proliferation:
  - Hypochoic
  - May be isoechoic to tendon
  - Variable flow on color Doppler imaging

3

## Tenosynovitis: ankylosing spondylitis



Short Axis

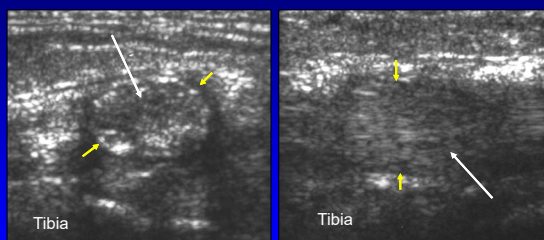
4

## Tendinosis

- Tendon degeneration
- Not tendinitis: no acute inflammation
- Swollen, hypochoic tendon
- Unlike tear:
  - Tendon fibers still continuous
  - No defined clefts

5

## Tendinosis: tibialis posterior



Transverse

Longitudinal

6

### Peroneal Tendon Tears: US

- 54 tendons (5 peroneal): surgery
  - US: 100% sensitivity, 93% accuracy<sup>1</sup>
- 60 peroneal tendons: surgery
  - US: 100% sensitivity, 90% accuracy<sup>2</sup>

<sup>1</sup>Waitches et al. JUM 1998; 17:249  
<sup>2</sup>Grant et al. 2005; 87:1788

7

### Tendon Tear Terminology

- Interstitial or intrasubstance tear
- Partial-thickness tear
- Longitudinal split tear
- Full-thickness tear

8

### Partial-thickness Tear: tibialis posterior

Short Axis

9

### Peroneus Brevis: Longitudinal Split

Short Axis

10

### Flexor Retinaculum Injury

Short Axis to Tibialis Posterior Tendon

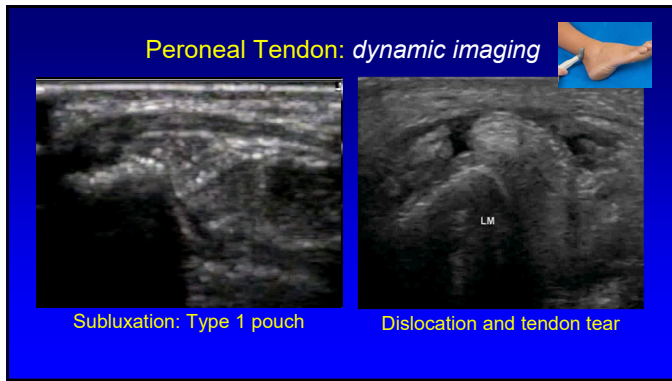
Long Axis

11

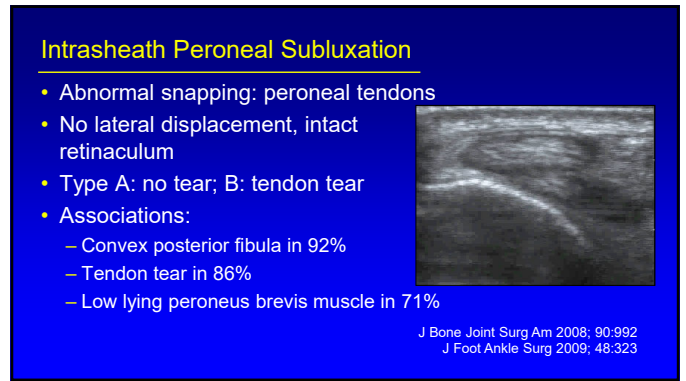
### Peroneal Retinaculum

Rosenberg et al. AJR 2003; 181:1551

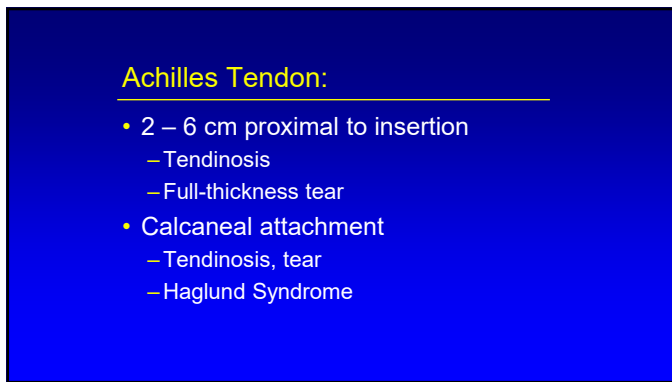
12



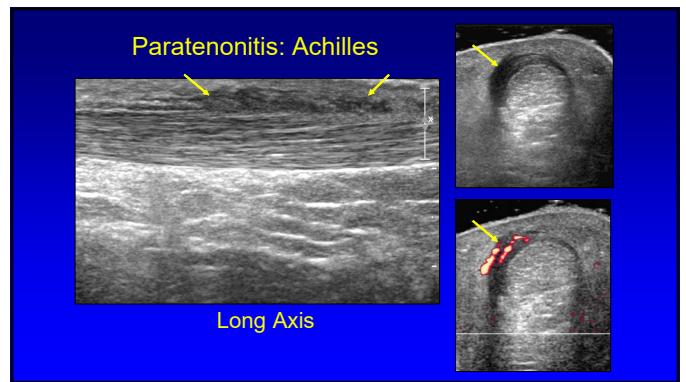
13



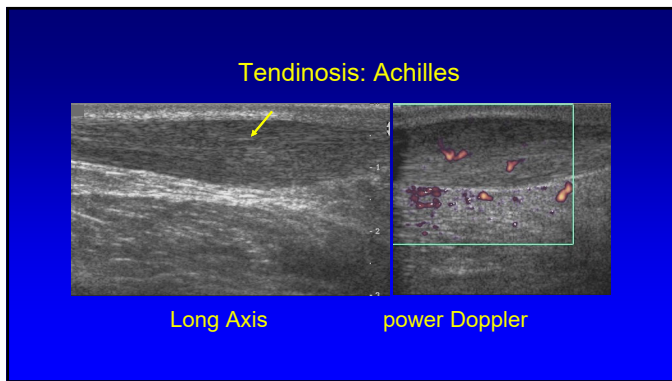
14



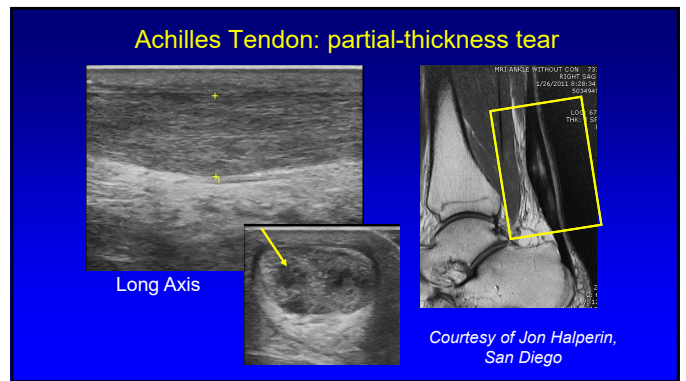
15



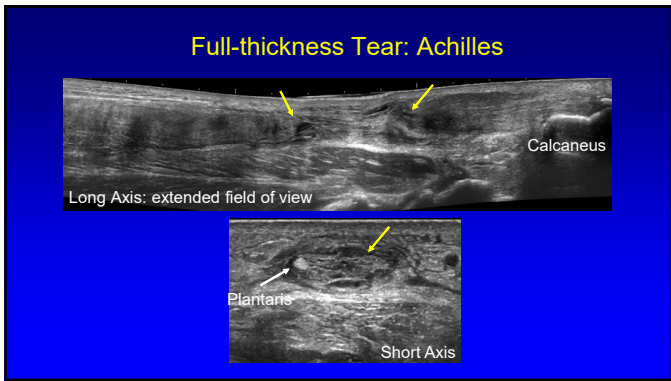
16



17



18



19

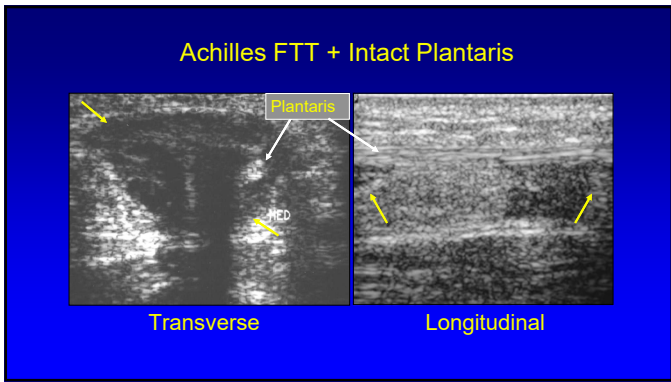
### Achilles Tendon: *complete tear*

---

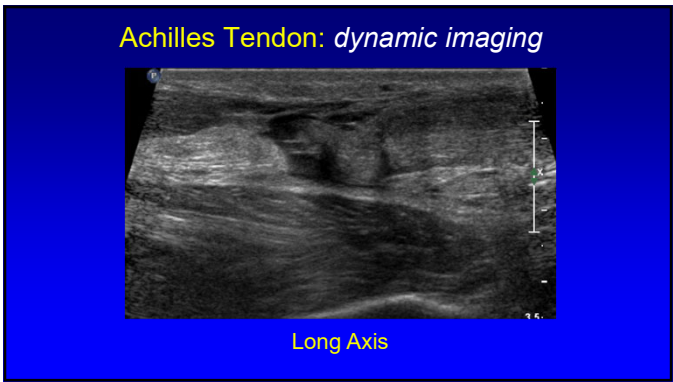
- Pitfall: intact plantaris tendon
  - Medial aspect of Achilles tendon
  - Misinterpreted as intact Achilles fibers

Radiology 2001; 220:406

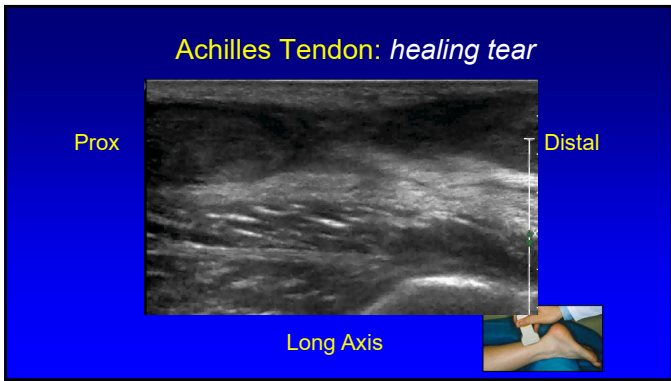20



21



22



23

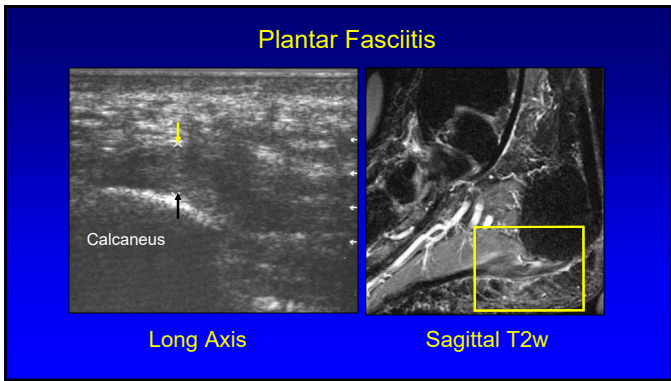
### Plantar Fascia:

---

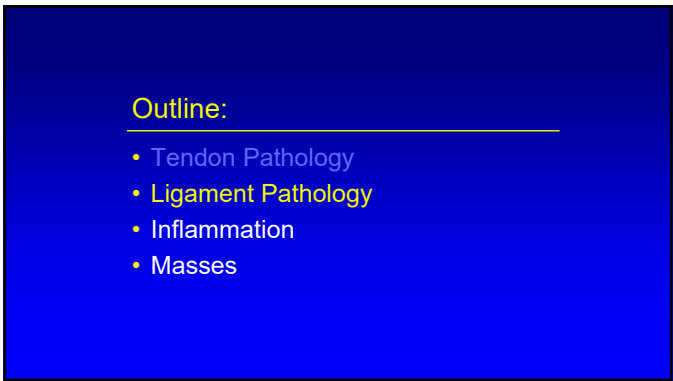- Fasciopathy
  - Central cord, proximal
  - Degenerative, tendinosis-like, tear
- US:
  - Hypoechoic, thickened > 4 mm
  - Painful with transducer pressure

Cardinal, E. et al. Radiology 1996; 201:257

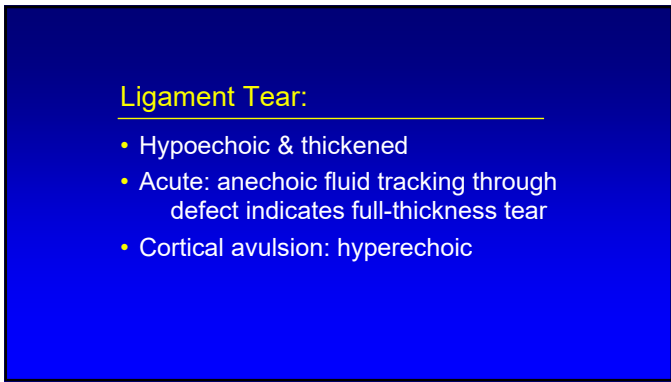
24



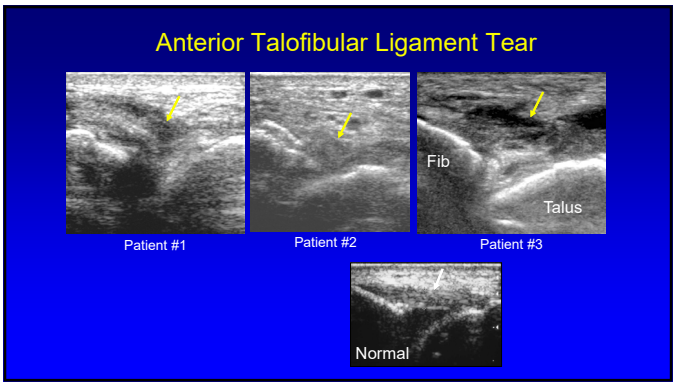
25



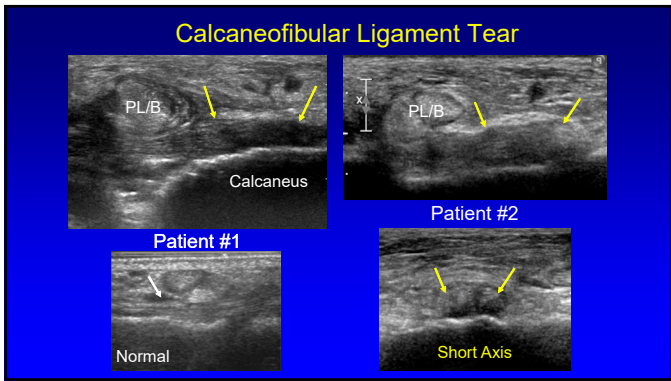
26



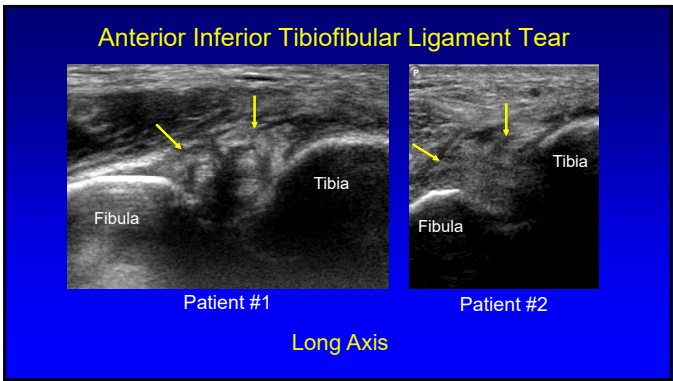
27



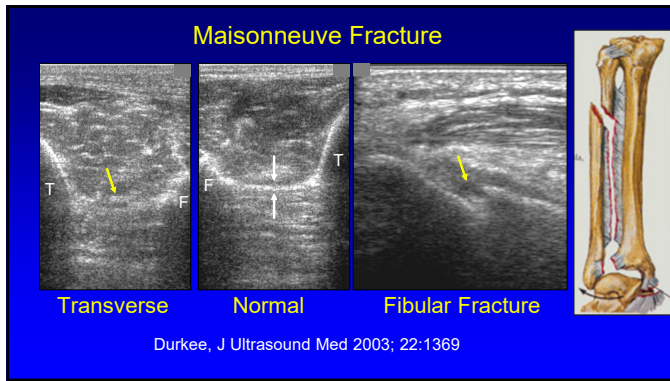
28



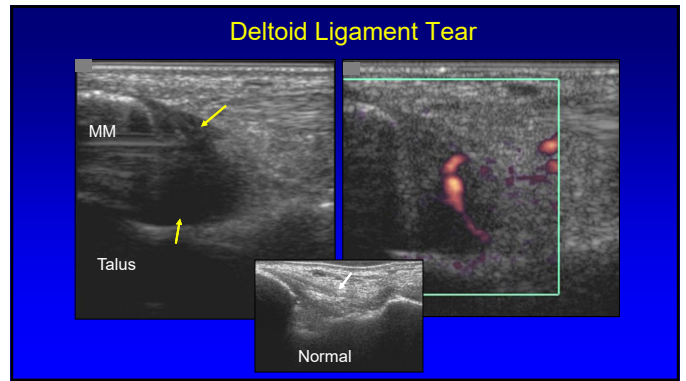
29



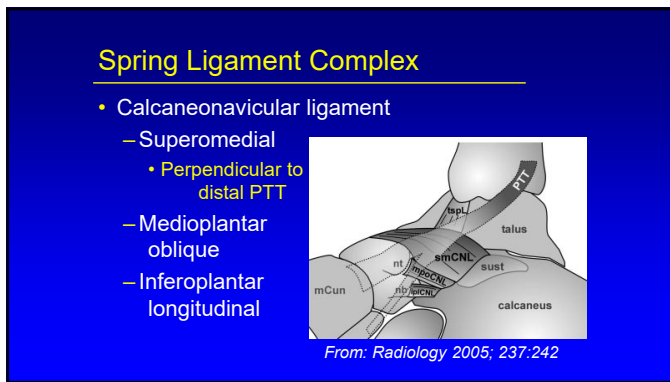
30



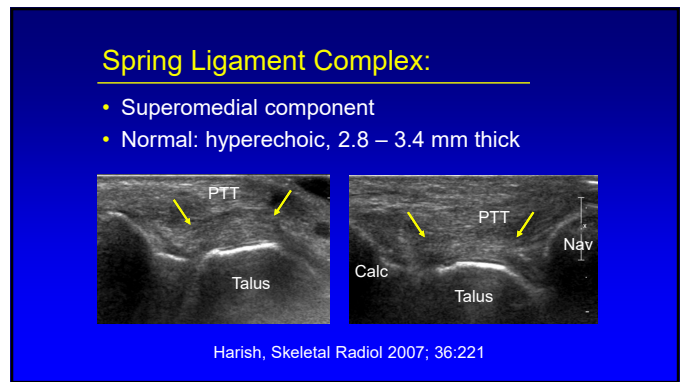
31



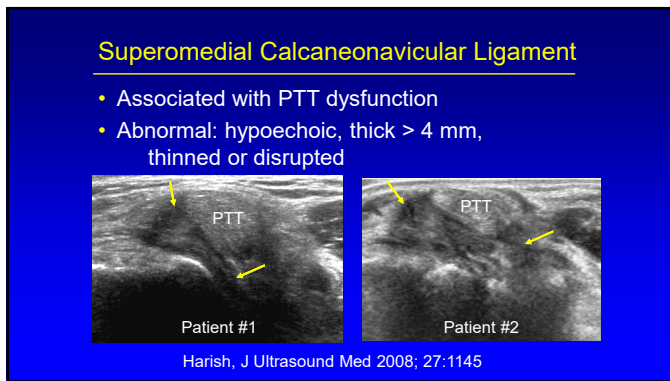
32



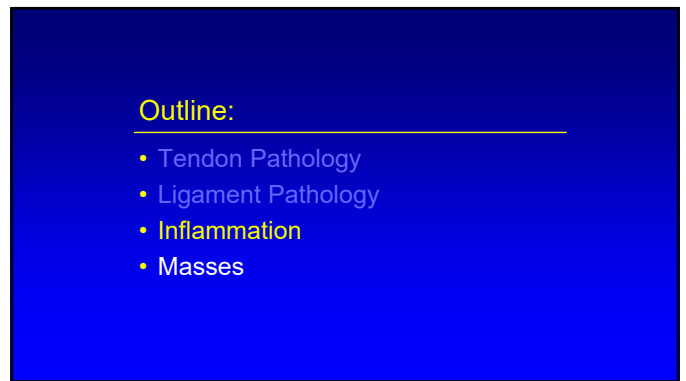
33



34



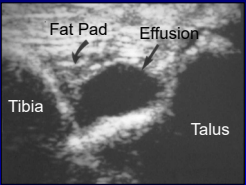
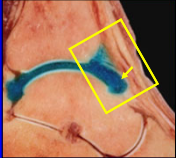
35



36

### Tibiotalar Joint: *effusion*

- Anterior evaluation most sensitive
- Plantar flexion
- Hyperechoic fat pad displaced by anechoic or hypoechoic fluid
- Sensitivity: MRI > US > PF

Jacobson, JA et al. AJR 1998; 170:1231

37

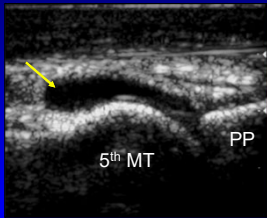
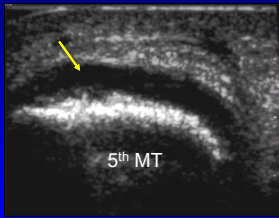
### Septic Joint:

- Anechoic or hypoechoic distention of joint recesses
- May be hyperechoic if complicated
  - Possible synovitis
- US or color Doppler cannot distinguish between septic and aseptic effusion\*

\*Strouse et al. Radiology 1998; 206:731

38

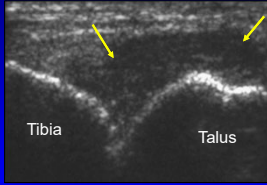
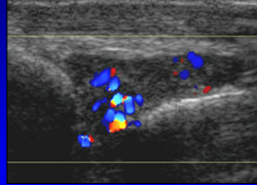
### 5<sup>th</sup> Metatarsal Phalangeal Joint: septic

Sagittal Coronal

39

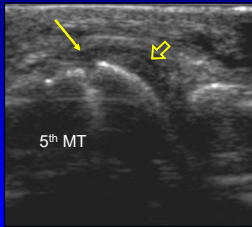
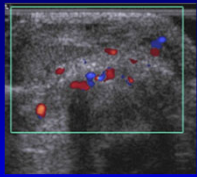
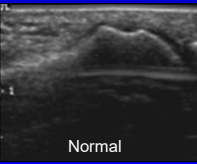
### Synovitis: color flow

RA Ankle No flow RA ankle Positive flow

40

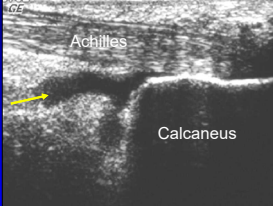
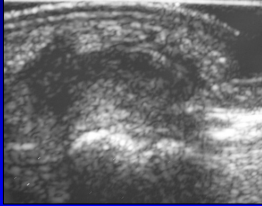
### Rheumatoid Arthritis

Erosion + Synovitis Normal

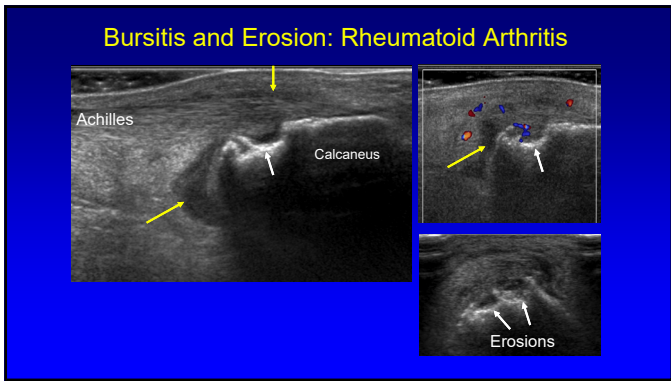
41

### Bursitis

Retrocalcaneal Adventitious

42



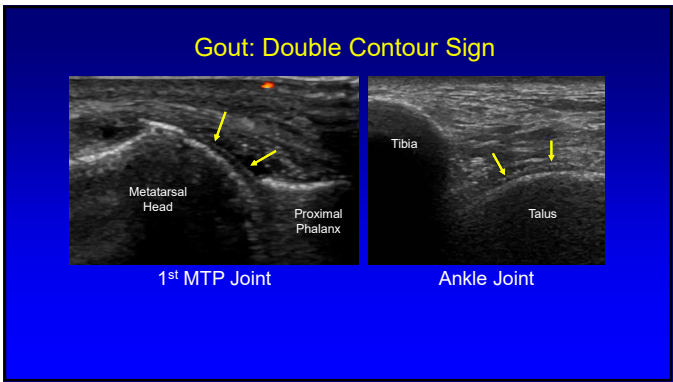
43

- ### Gout:
- Joint effusion / synovial hypertrophy
  - Double contour sign:
    - Monosodium urate crystal icing on cartilage
  - Tophi:
    - Hyperechoic with hypoechoic rim
  - Erosions:
    - Adjacent to tophi
    - Medial 1<sup>st</sup> metatarsal head

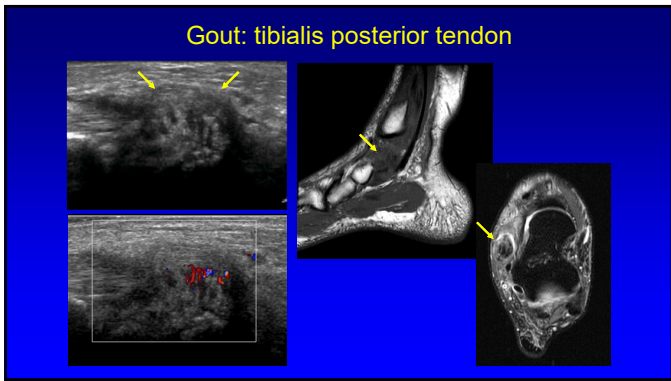
44

- ### Tophi
- 
- Hyperechoic heterogeneous with hypoechoic rim
  - Tiny internal speckles\*
  - “wet clump of sugar” appearance
  - Variable shadowing: even without calcification
- 
- Fernandes et al. Skeletal Radiol 2011; 40:309

45



46



47

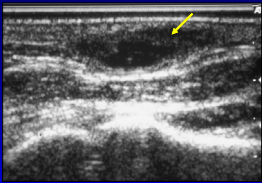
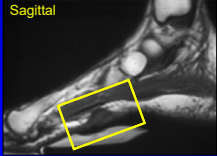
- ### Outline:
- Tendon Pathology
  - Ligament Pathology
  - Inflammation
  - Masses

48



### Plantar Fibromatosis

- Benign fibrous proliferation
- Multiple: 33%, bilateral: 20 – 50%
- Hypoechoic mass or masses
- Plantar aponeurosis
- Variable vascularity

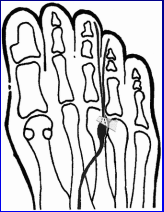
Sagittal

Griffith JF et al. AJR 2002; 179:1167

49

### Morton Neuroma:

- Interdigital nerve entrapment
- Edema, fibrosis, necrosis
- 3<sup>rd</sup> intermetatarsal space > 2<sup>nd</sup>
- Sharp, burning pain from metatarsal head to toes
- Females: pliable foot, high-heeled narrow-toed shoes



From: Martinoli, RadioGraphics 2000; 20:S199

50

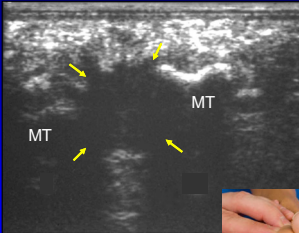
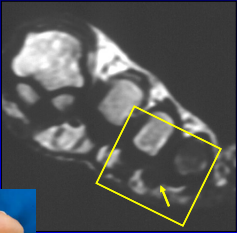
### Morton Neuroma

- Hypoechoic 5 mm mass
  - Sensitivity: 100% ; Specificity: 83%
  - Accuracy equal to MRI
  - Nerve continuity: sagittal plane
- Intermetatarsal bursa
  - Associated with neuroma
  - “Neuroma-bursal complex”

Quinn T et al. AJR 2000; 174:1723  
 Bignotti B et al. Eur Radiol 2015; 25:2254  
 Cohen SL et al. J Ultrasound Med 2016; 25:3191

51

### Morton Neuroma

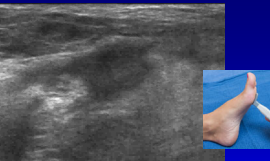
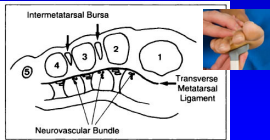
Transverse

Coronal T1w

52

### Dynamic Evaluation

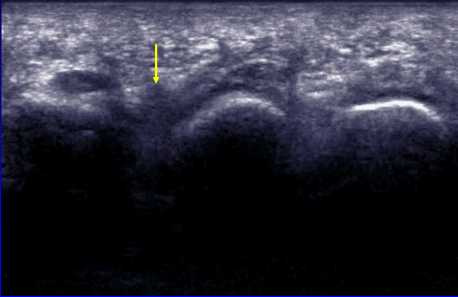
- Compression
  - Between transducer and palpation
  - Bursae (dorsal) compress, neuromas (plantar) do not
- Sonographic Mulder Sign
  - Scan plantar: coronal plane
  - Neuroma displaces: plantar
  - Palpable click

Torriani M et al. AJR 2003; 180:1121  
 Zanetti M et al. Radiology 1997; 203:516

53

### Dynamic imaging: Mulder's Maneuver



54

## Take Home Points

- Tendons:
  - Tenosynovitis, tendinosis, partial tear, longitudinal split, complete tear
- If concern for infection: aspirate
- Gout: specific findings
- **Dynamic imaging**
  - Peroneal subluxation
  - Achilles tear
  - Morton neuroma

55



Syllabus on line and other educational material:  
[www.jacobsonmskus.com](http://www.jacobsonmskus.com)

Twitter handle: @jjacobsn

56