

Ultrasound of Athletic Groin and Hernias

Jon A. Jacobson, MD
 FACR, FSRU, FAIUM, RMSK
 Professor of Radiology
 Lenox Hill Radiology, NYC
 University of California, San Diego



Syllabus PDF

1

Disclosures

- Consultant: Bioclinica
- Contractor: POCUS PRO
- Advisory Board: Philips
- Book Royalties: Elsevier
- Not relevant to this lecture

*Note: all images from the textbook
 Fundamentals of Musculoskeletal Ultrasound are
 copyrighted by Elsevier Inc.*

See www.jacobsonmskus.com for syllabus other educational material

2

Groin Pain

- Hip joint: labral tear
- Pubic symphysis
- Fracture
- Tendon tear and "sports hernia"
- Inguinal hernia
- Algorithm: radiographs, US, MRI

So many causes for groin pain.....



3

Sports Hernia?:

- A non-anatomic, non-diagnostic term attributed to many cause of groin pain
 - Tears or attenuation of inguinal structures
 - Bulge posterior wall of inguinal canal
 - Obturator nerve entrapment
 - **Common aponeurosis** abnormality:
 - Rectus abdominis and adductors tendons
 - Associated: pubic symphyseal instability, FAI

Omar IM et al. Radiographics 2008; 28:1415
 Garvey JFW et al. Hernia 2010; 14:17
 Hopkins JN et al. JBJS Reviews 2017; 5:1

4

to Durant, who missed 17 games and returned to action on December 2, the general public learned quickly about the injury and its ramifications. Even seasoned athletes were mystified.

"I'm so old that when you got hurt they didn't have names for it," says NBA Hall of Famer and TNT analyst Charles Barkley. "They come up with names for injuries now. Back in my day [they'd say], 'Oh, he broke a foot.'"

Durant's *Jones fracture* isn't the first time the sports media has felt the need for an explanatory article. Back in the mid-'90s, when Cincinnati Reds shortstop and future Hall of Famer Barry Larkin suffered an injury in the groin area that defied any straight-ahead medical vernacular—it was kind of like a hernia, but not quite—reporters hounded the Reds' medical director and chief orthopedic surgeon, Dr. Timothy Kremchek.

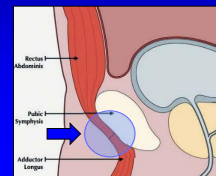
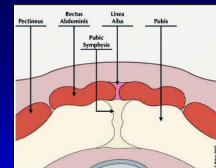
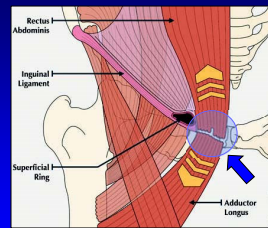
"The newspaper writers—there was no HIPAA back then, nothing—kept asking me about it," Kremchek says now, "so I said he's got a *sports hernia*. I had never even heard of it. I made it up."

Kremchek is referring to the privacy rule of the Health Insurance Portability and Accountability Act (HIPAA), which Congress passed in 1996 and which forbids public disclosure of medical information without appropriate consent.

Author: Joe Lemire, Hemisphere Magazine, Feb. 2015

5

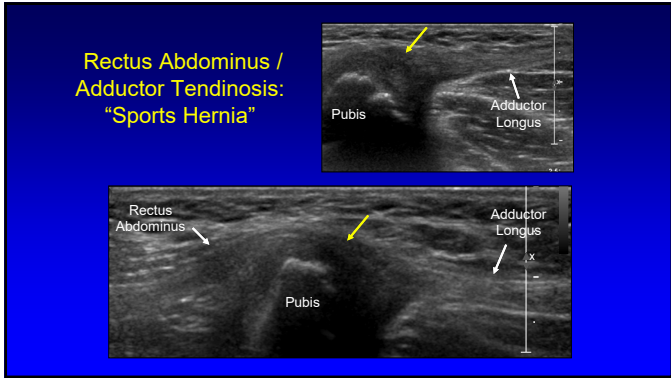
Rectus Abdominis + Adductor: "Sports Hernia"



Note: common aponeurosis

From: RadioGraphics 2008; 28:1415

6



7

Hernia

- Definition: abnormal movement of contents from one anatomic compartment to another
- Inguinal region hernia:
 - Indirect inguinal
 - Direct inguinal
 - Femoral

8

Inguinal Region Hernia: US technique

- Start transverse: rectus abdominis
- Find inferior epigastric artery
- Follow to origin at external iliac artery
- Move superior to find deep inguinal ring
- Angle toward pubis
- Scan Hesselbach's triangle

9

Inguinal Region Hernia: Posterior View

10

Inguinal Region Hernia: Posterior View

11

Inguinal Region Hernia: Posterior View

12

Imaging Inguinal Hernias:

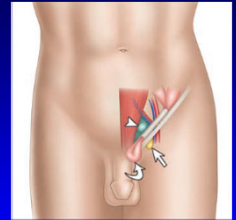
- In diagnosis of occult inguinal hernias:
- Ultrasound:
 - 86% sensitivity and 77% specificity
- CT:
 - 80% sensitivity and 65% specificity
- Herniography:
 - 91% sensitivity and 83% specificity

Robinson A. Surg Endosc 2013; 27:11

13

Indirect Inguinal Hernia:

- Extends through deep inguinal ring
- Lateral to inferior epigastric
- Courses medial within inguinal canal
- Parallel to skin surface
- Contains fat or less commonly bowel
- Confirm in two planes

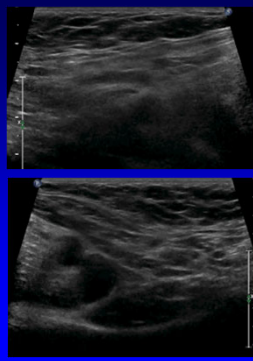
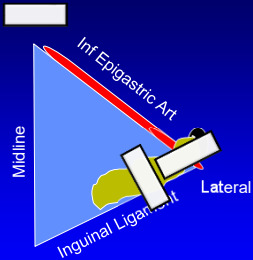


Curved arrow = indirect ing. hernia
Arrowhead = direct inguinal hernia
Arrow = femoral hernia

From: Jacobson JA, et al.
Am J Roentgenol 2015; 205:1

14

Indirect Hernia



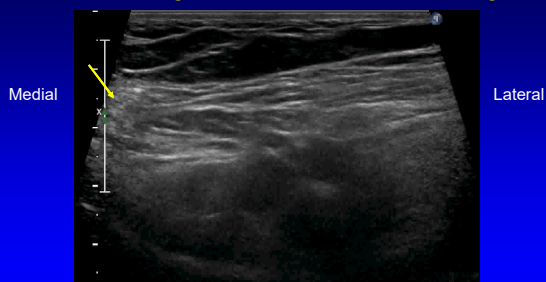
15

How do you Valsalva?

- Tighten belly
- Hold breath
- Blow on back of hand
- Stand up
- Clue: femoral vein should distend

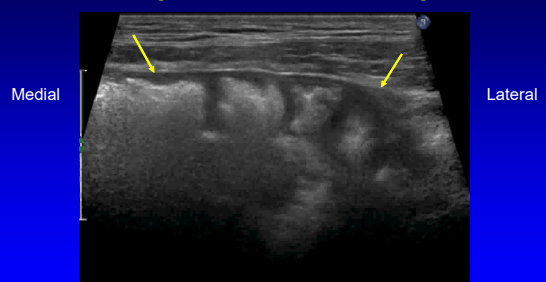
16

Indirect Inguinal Hernia: to external ring

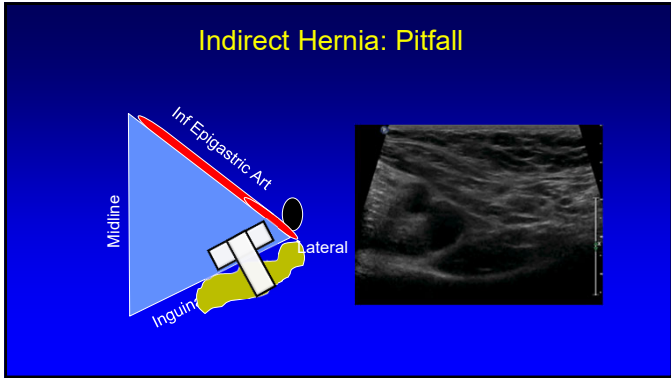


17

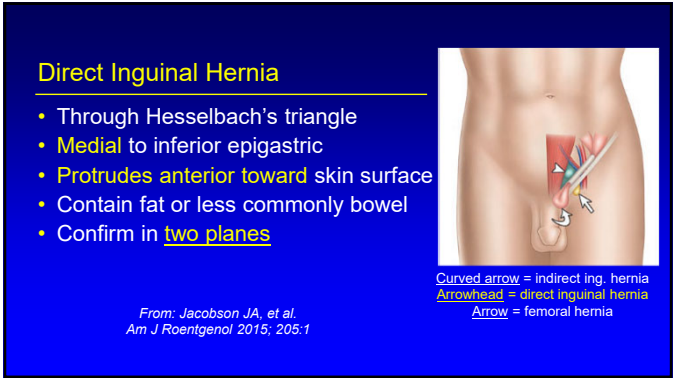
Indirect Inguinal Hernia: containing bowel



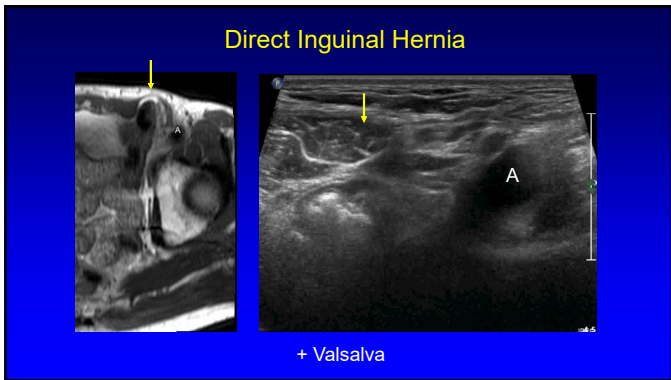
18



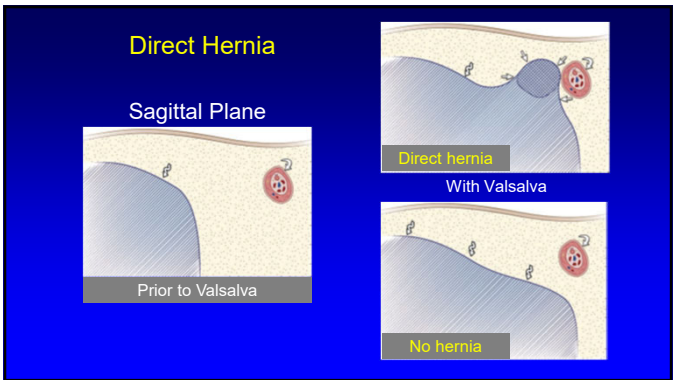
19



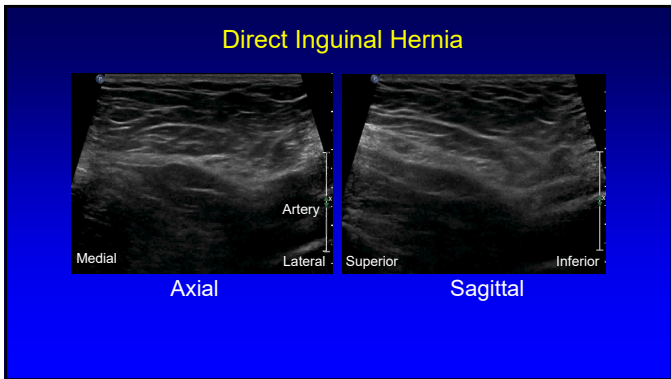
20



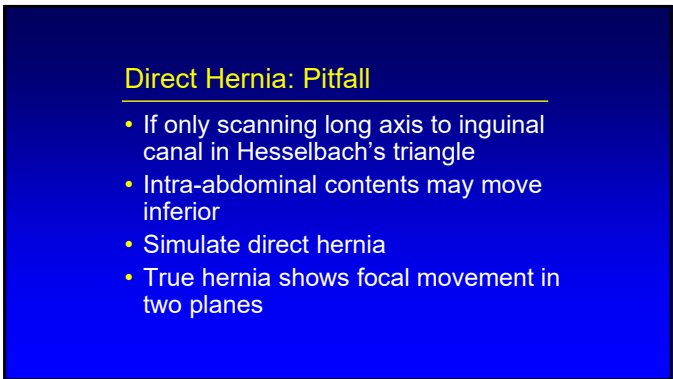
21



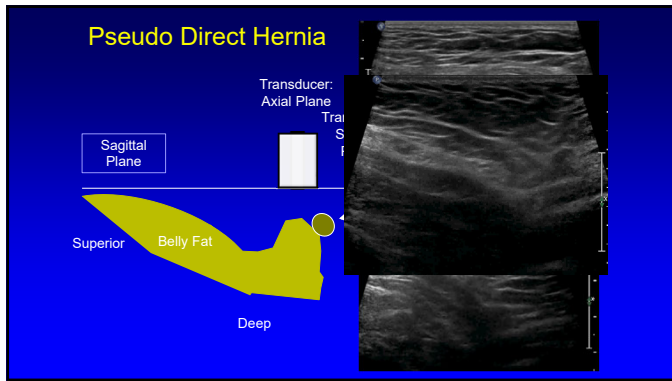
22



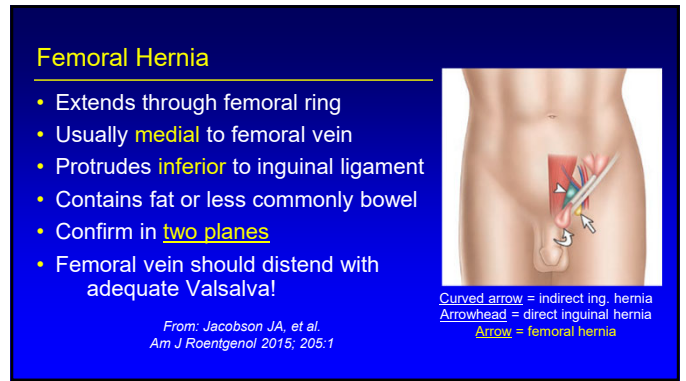
23



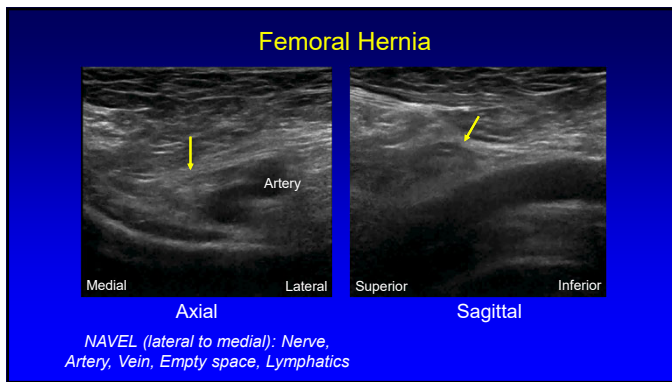
24



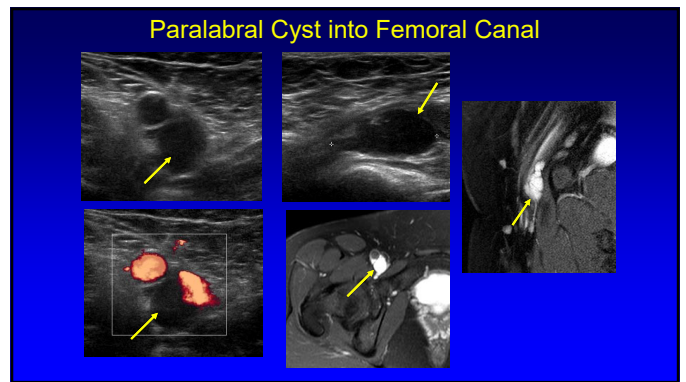
25



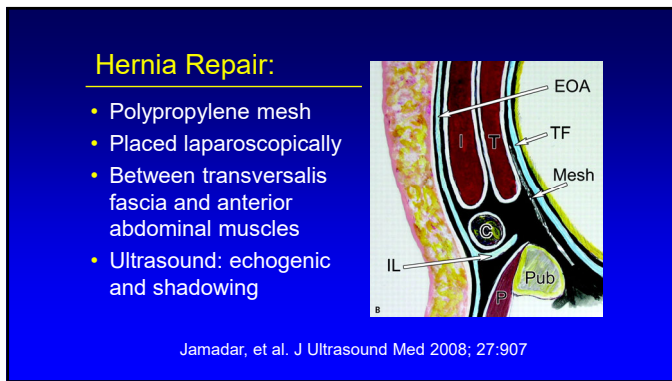
26



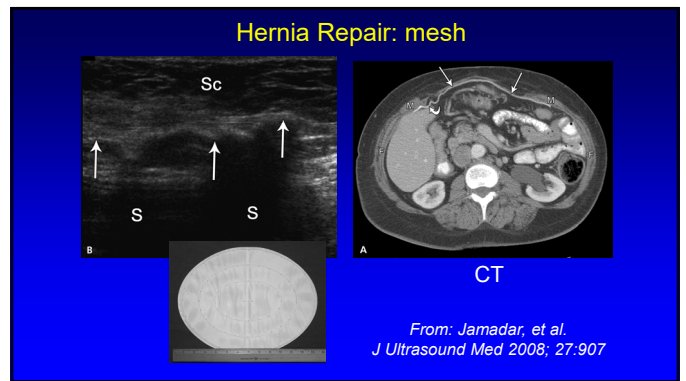
27



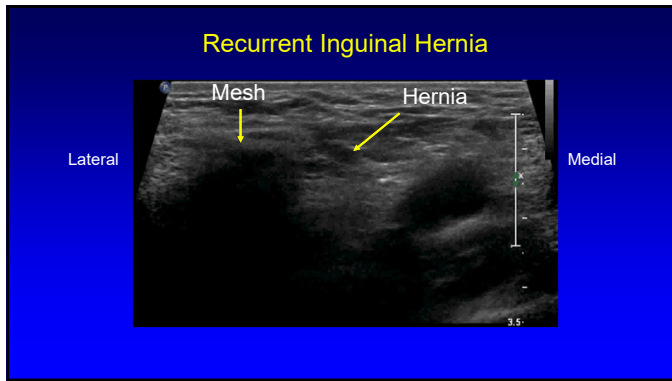
28



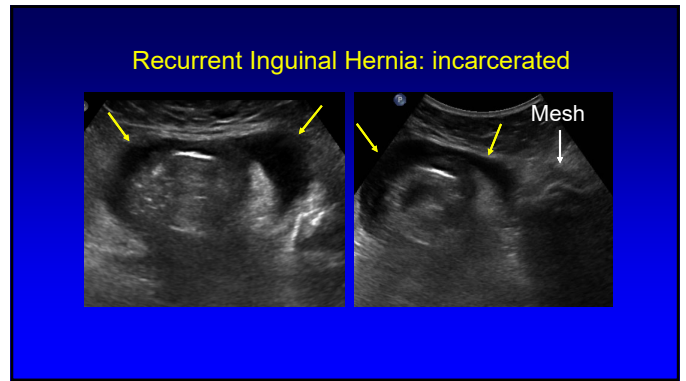
29



30



31



32

Take Home Points

- Groin pain is multifactorial
 - Include common aponeurosis
- Assess for inguinal hernias
 - Document in two planes
 - Sagittal plane is essential!
- Valsalva: femoral vein should distend

33




Inguinal Region Hernias

Curved arrow = indirect inguinal hernia
Arrowhead = direct inguinal hernia
Arrow = femoral hernia

From: Jacobson JA, et al. Am J Roentgenol 2015; 205:1


34

Thank you!

Syllabus on line and other educational material:
www.jacobsonmskus.com

Twitter handle: @jjacobsn



35