

# An Algorithmic Approach to Musculoskeletal Imaging Interpretation

Jon A. Jacobson, MD  
FACR, FSRU, FAIM, RMSK

Musculoskeletal Radiologist  
Lenox Hill Radiology, NYC

1

## Disclosures

- Consultant: Bioclinica
- Contractor: POCUS PRO
- Advisory Board: Philips
- Book Royalties: Elsevier
- Not relevant to this lecture

*Note: all images from the textbook  
Fundamentals of Musculoskeletal Ultrasound  
are copyrighted by Elsevier Inc.*

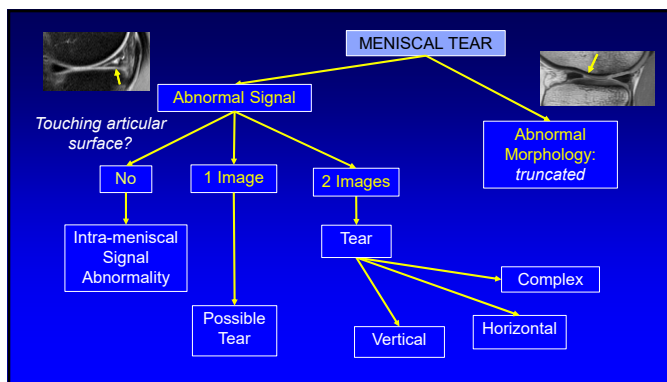
See [www.jacobsonmskus.com](http://www.jacobsonmskus.com) for syllabus other educational material

2

## Outline

- Meniscal tear
- Osteomyelitis
- Arthritis
- Mass
- "Cyst" on MRI

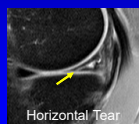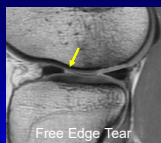3



4

## Meniscus Tear: MRI criteria

- Abnormal morphology
  - Truncation, absence
- Abnormal signal
  - Extends to articular surface (unequivocally)
  - Two consecutive or orthogonal images
  - "Two-slice-touch rule"



5

## Meniscus Tear: MRI criteria


- Positive predictive value for meniscus tear: One slice versus two slice touch


	1 Slice	2 Slice
Medial Meniscus	43%	94%
Lateral Meniscus	18%	96%
Reporting	"Possible Tear"	"Tear"

Nguyen JC et al. Radiographics 2014; 34:981

6

### Meniscus: internal signal

- Not in contact with articular surface
- Vascularity (periphery): children
- Radial tie fibers (periphery)<sup>1</sup> → 
- Contusion: globular, ill-defined<sup>2</sup>
- Degenerative signal
  - If linear in medial meniscus: progress to tear
  - If middle aged without osteoarthritis<sup>3</sup>

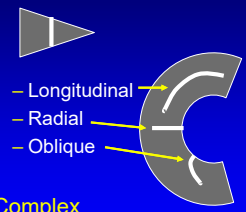


<sup>1</sup>Hauger O et al. Radiology 2000; 217:340  
<sup>2</sup>Cothran RJ et al. AJR 2001; 177:1189  
<sup>3</sup>Kumm J et al. Radiology 2015; 278:164

7

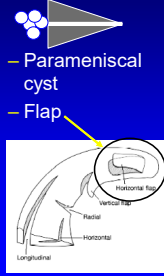
### Meniscus Tear: MRI Classification

#### Vertical




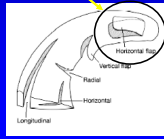
- Longitudinal
- Radial
- Oblique

#### Horizontal



- Parameniscal cyst
- Flap

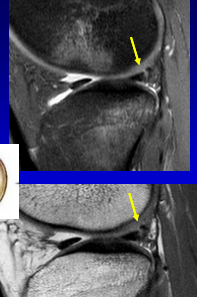

#### Complex

8

### Meniscal Tear: vertical

- Longitudinal: non-displaced
- Usually peripheral
- Often traumatic
- Associated with ACL tears
  - 90% of medial tears
  - 83% of lateral tears
- >1 cm in length: unstable
- Pitfall: meniscofemoral ligament of Wrisberg

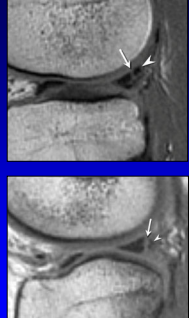
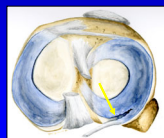



Nguyen JC et al. Radiographics 2014; 34:981

9

### PHLM Rip Tear

- Longitudinal tear PHLM
- Associated with ACL tears
- Pitfall: continuous with meniscofemoral ligament
- Cleft >3 images lateral to PCL (>10 mm) = tear






Park et al. Skeletal Radiol 2007; 36:399

10

### Meniscal Tear: vertical

- Longitudinal: displaced
  - Bucket-handle
    - Medial > lateral
    - Double-PCL (medial)
    - Intact meniscal ring
- Pitfall: oblique meniscomeniscal ligament

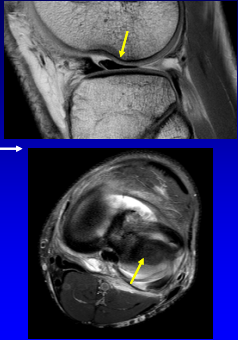




Nguyen JC et al. Radiographics 2014; 34:981

11

### Meniscal Tear: vertical

- Longitudinal: displaced
  - Flipped fragment
    - Connected at one end →
  - Free fragment

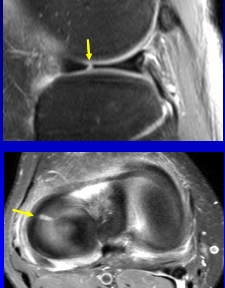




Lance V et al. Skeletal Radiol 2015; 44:375

12

### Meniscal Tear: vertical

- Radial
- Incomplete or complete
- Free edge tear
- Disrupted bow tie appearance of meniscus





Nguyen JC et al. Radiographics 2014; 34:981

13

### Meniscal Tear: vertical

- Radial
- Root tear
- "Ghost meniscus"
  - Absent on one slice
- Possible meniscal extrusion (relative to tibia)

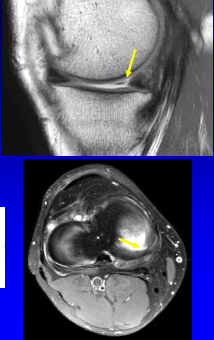




Choi JY et al. AJR 2014; 203:1286

14

### Meniscal Tear: vertical

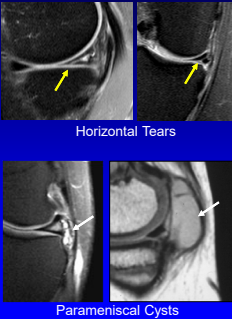
- Oblique vertical
  - Parrot beak
  - Vertical flap tear

15

### Meniscal Tear: horizontal

- Often to or near apex
- Parameniscal cyst
  - Multilocular
  - Axial plane around meniscus
  - Medial: away from meniscus
- Pitfall: AHLM ganglion cyst



Horizontal Tears

Parameniscal Cysts

Nguyen JC et al. Radiographics 2014; 34:981

16

### Meniscal Tear: horizontal

- Horizontal flap tear
- Flap: deep to MCL
  - May not be low signal
- Superior 6x > inferior
- Key: truncated meniscus
- Also: hemi-bucket handle




Lecas LK et al. AJR 2000; 174:161  
Engstrom SK et al. Skeletal Radiol 2012; 41:933

17

### Meniscal Tear: complex

- Does not fit into one specific tear pattern
- Often degenerative and macerated




18

### Outline

- Meniscal tear
- **Osteomyelitis**
- Arthritis
- Mass
- "Cyst" on MRI

19

### Osteomyelitis: adult

Soft tissue ulcer?

```

    graph TD
      A[Soft tissue ulcer?] -- Yes --> B[T2w: High Signal]
      A -- No --> C[Normal probably]
      B -- High --> D[T1w Signal]
      B -- None --> E[Normal]
      D -- Low --> F[Osteomyelitis]
      D -- Normal --> G[Reactive Edema]
      E --> G
  
```

IV Contrast: delineates abscess and sinus tracks

*\*In the absence of ulcer, surgery, or penetrating injury, osteomyelitis of foot is rare*

20

### Osteomyelitis: 5th metatarsal

21

### Reactive Edema

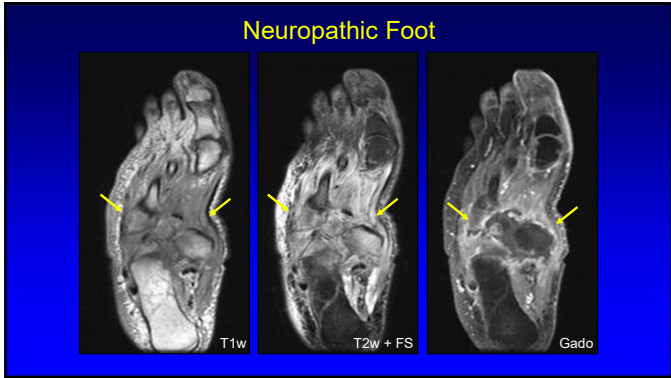
22

### Osteomyelitis: femur

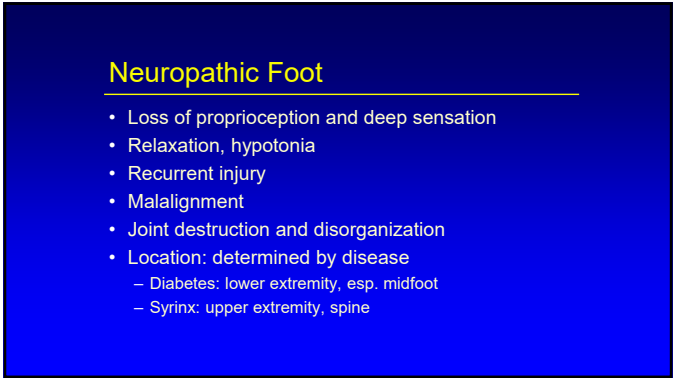23

### Osteomyelitis

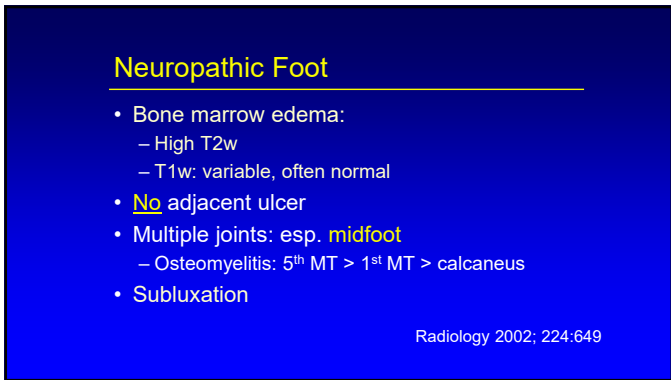
24



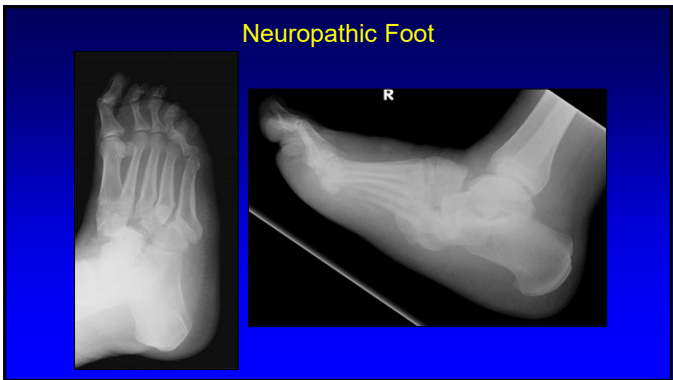
25



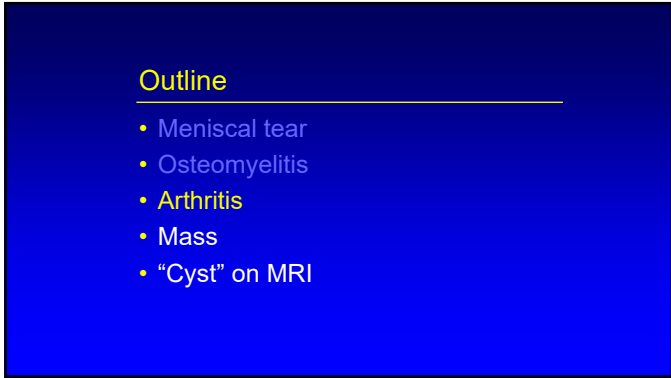
26



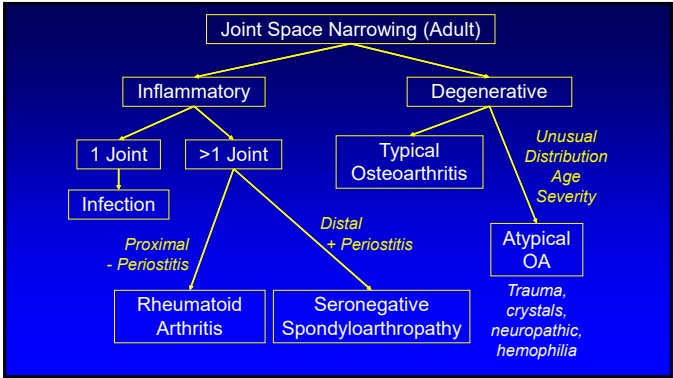
27



28



29



30

### Radiographic Algorithm: *adult*

- Starting point: joint space narrowing
- Inflammatory versus degenerative arthritis


\*Evaluation of Arthritis: Inflammatory Conditions. Radiology 2008; 248:378-389

\*Evaluation of Arthritis: Degenerative Joint Disease and Variations. Radiology 2008; 248:737-747

31

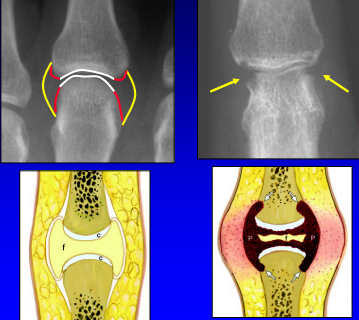
### Inflammatory Arthritis

- Periarticular osteopenia
- Soft tissue swelling
- Erosions:
  - Initially marginal
  - Cortex discontinuous
- Joint space narrowing: **uniform**



32

### Marginal Erosions: rheumatoid arthritis



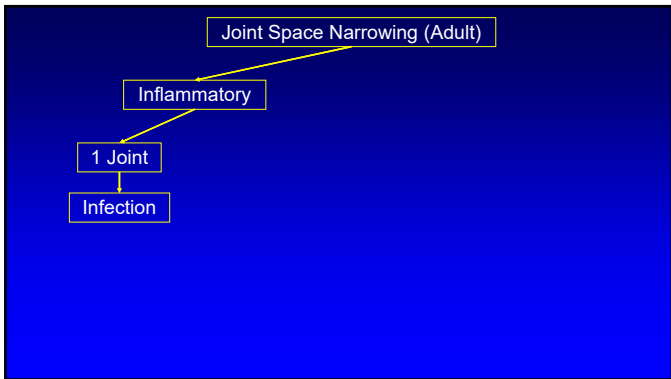
33

### Degenerative Arthritis:

- Joint space narrowing: not uniform
- Normal mineralization
- Osteophytes
- Sclerosis and eburnation

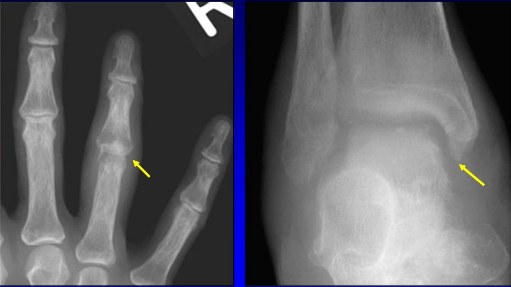


34



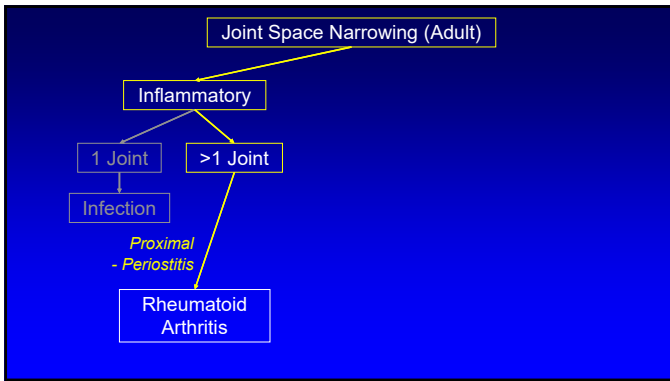
35

### Inflammatory: septic joint

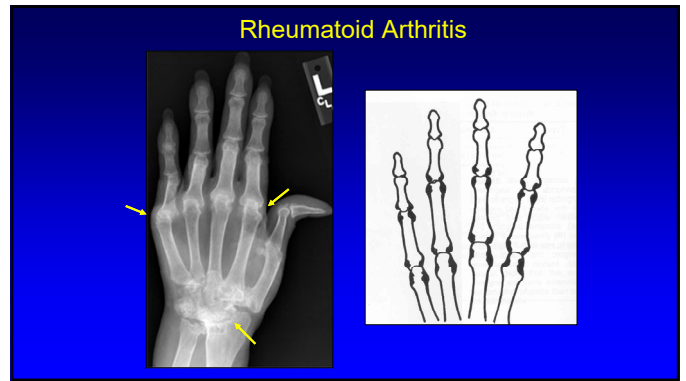


Staph. Aureus
Tuberculosis

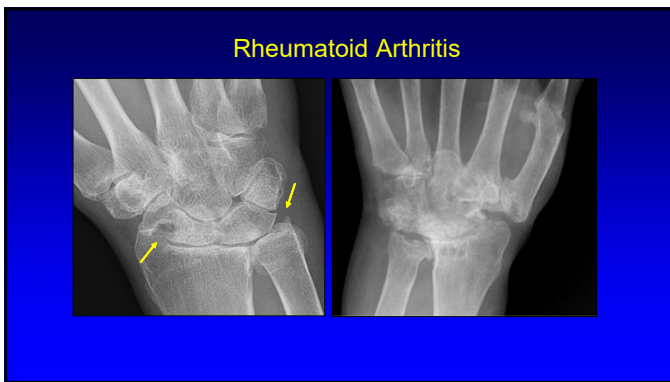
36



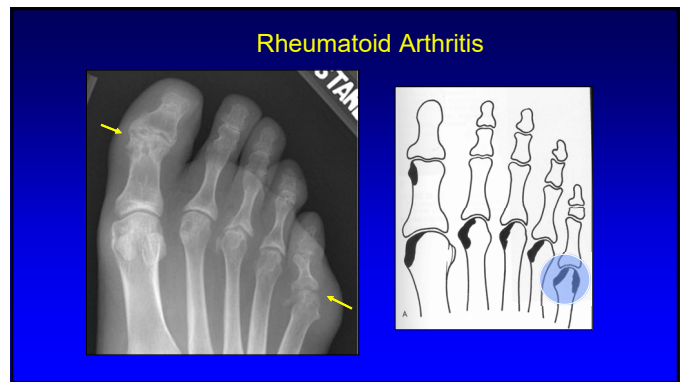
37



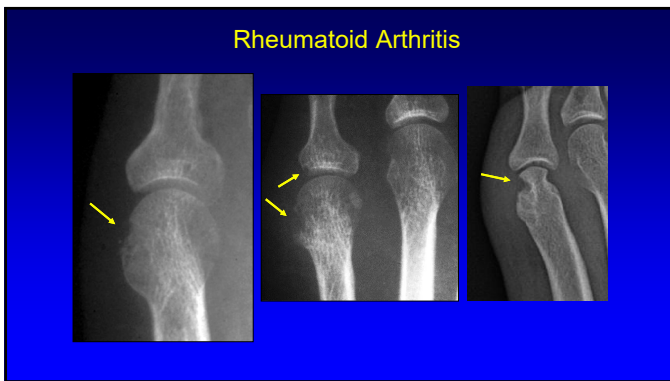
38



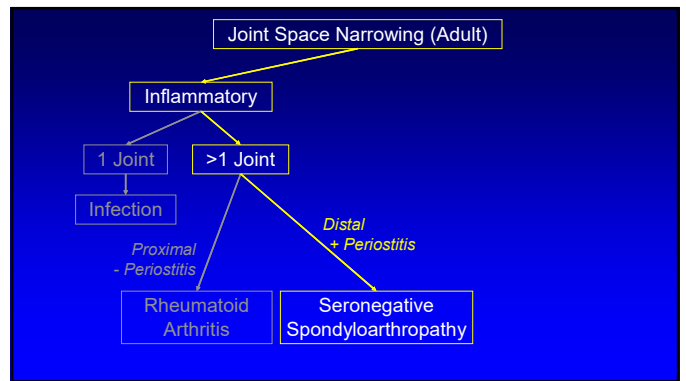
39



40



41



42

### Seronegative Spondyloarthropathy:

- Synovial joints:
  - Erosions, uniform joint space narrowing
  - Periostitis
- Cartilaginous joints: erosions
- Enteses:
  - Tendon and ligament attachment
  - Fluffy enthesophytes, erosions

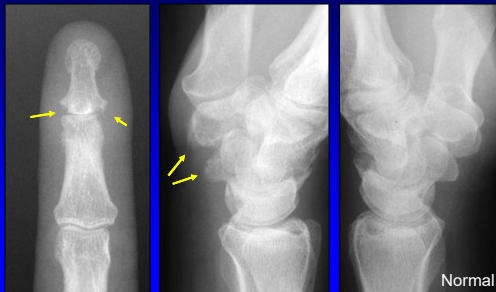
43

### Seronegative Spondyloarthropathy:

- Key to diagnosis: **distribution**
- Psoriasis: hands, feet, spine, SI joints
- Reactive arthritis: feet, SI joints
- Ankylosing spondylitis: axial skeleton, glenohumeral joints

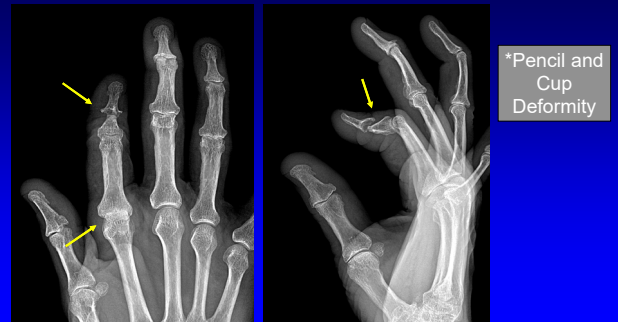
44

### Psoriatic Arthritis



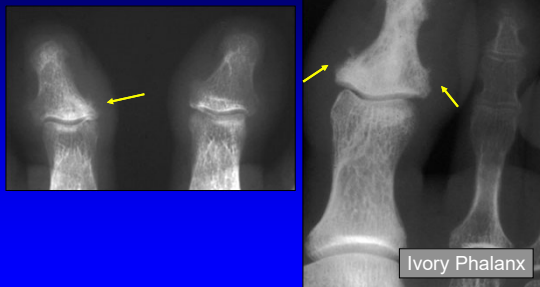45

### Psoriatic Arthritis



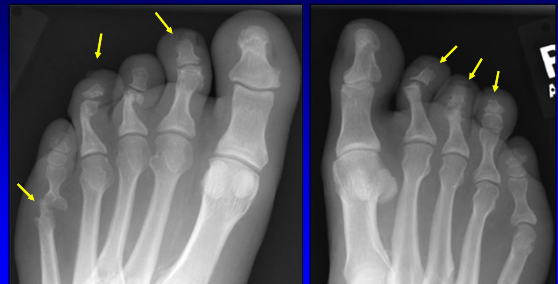46

### Psoriatic Arthritis



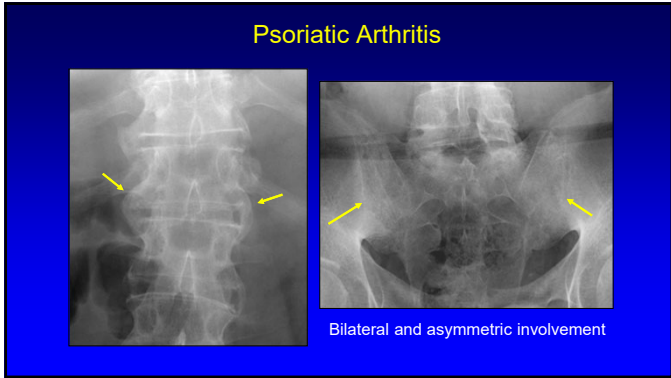
47

### Psoriatic Arthritis

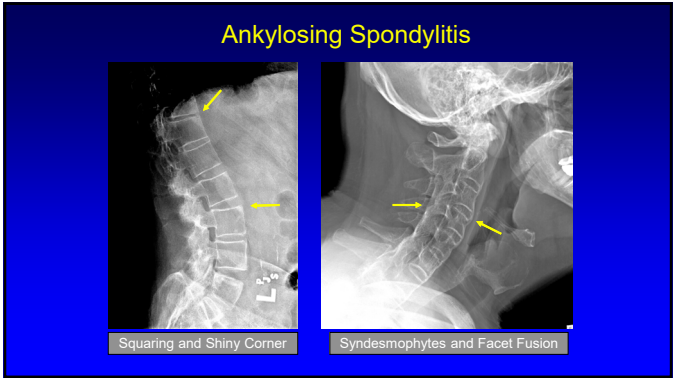


48

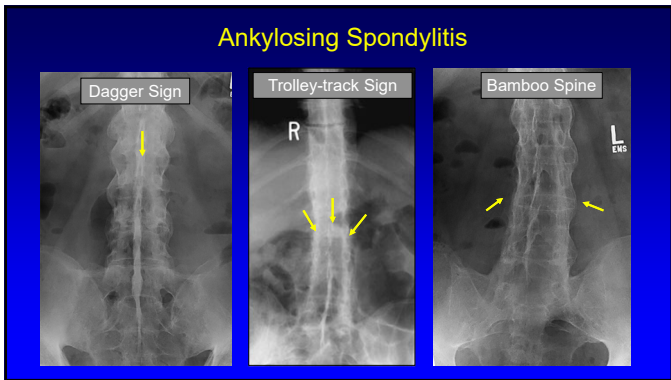




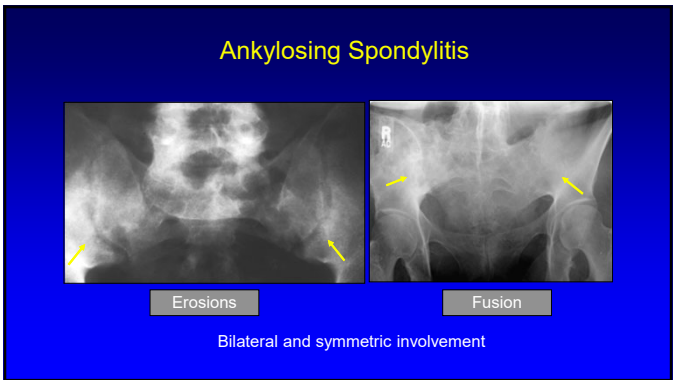
49



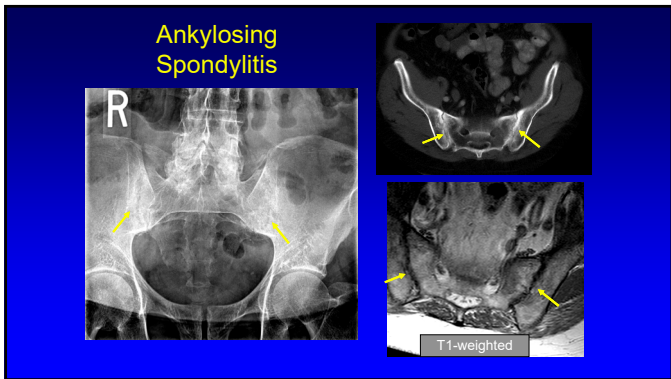
50



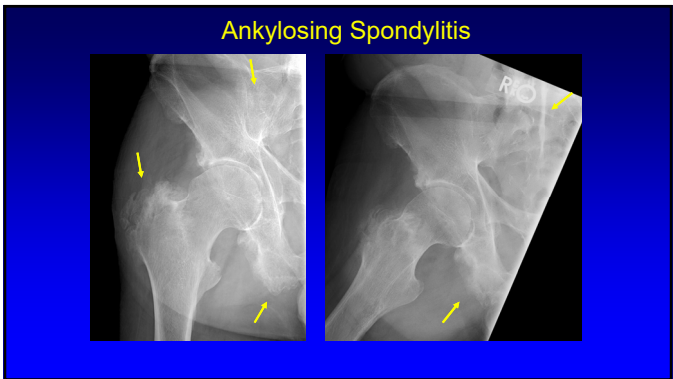
51



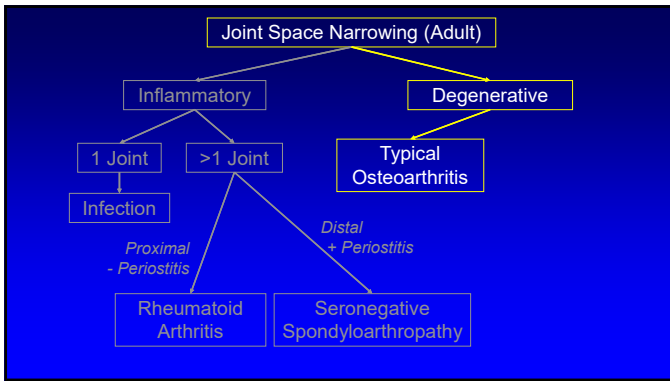
52



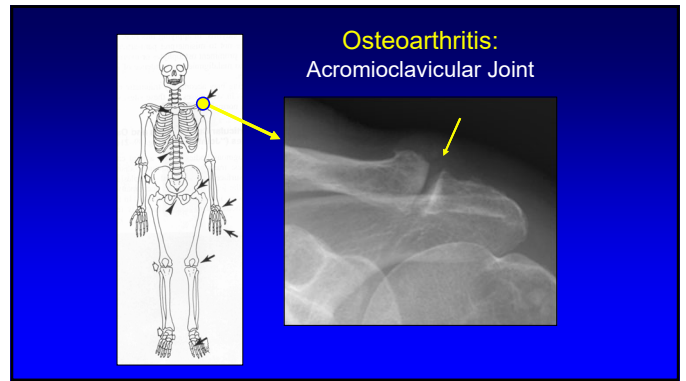
53



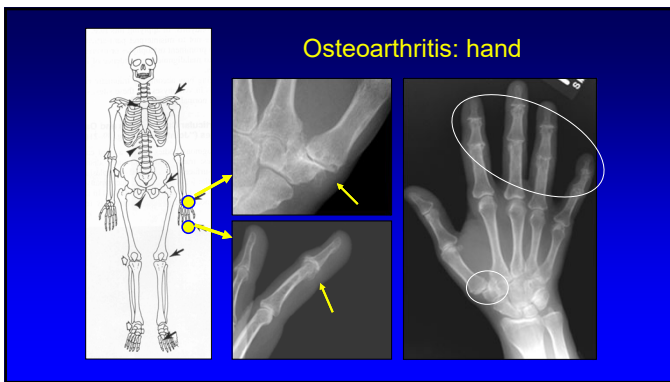
54



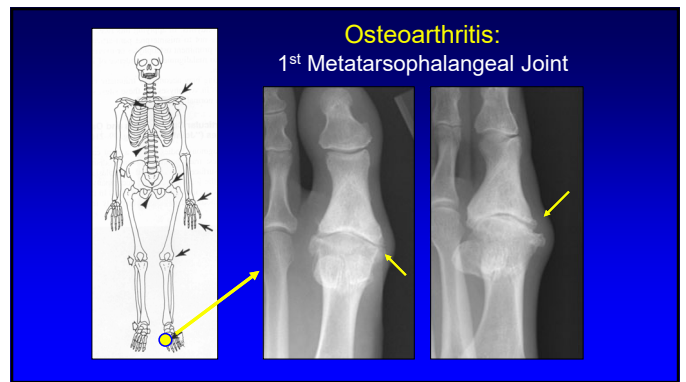
55



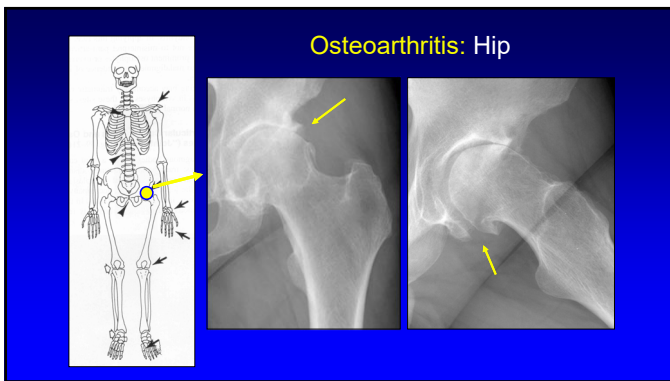
56



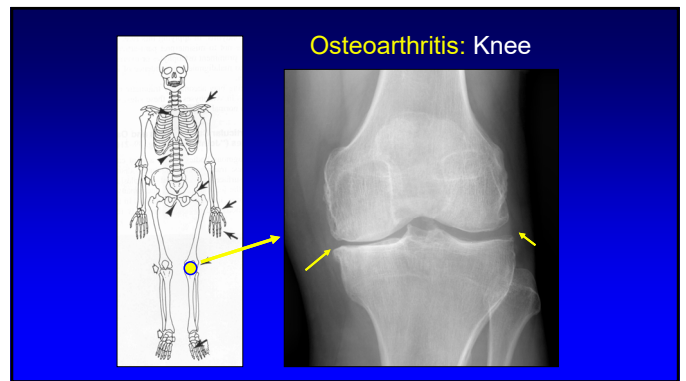
57



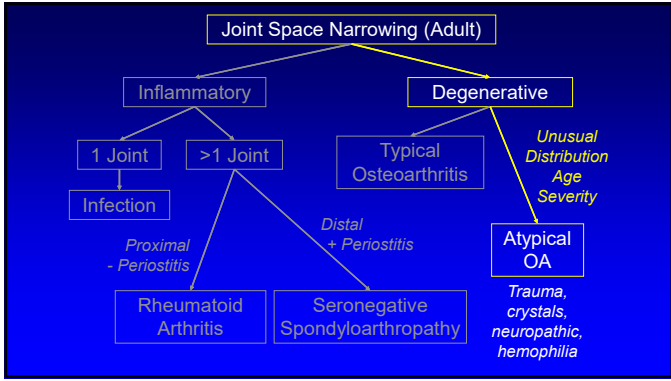
58



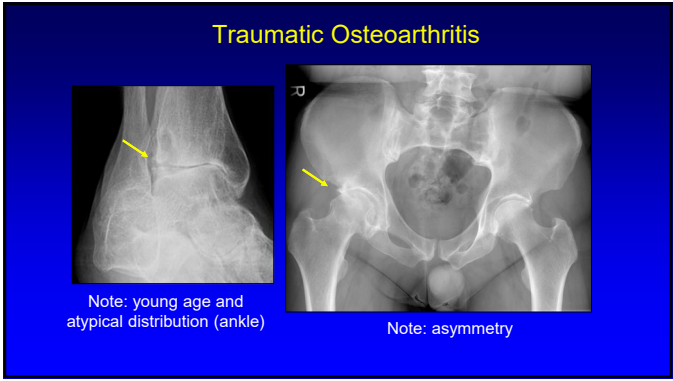
59



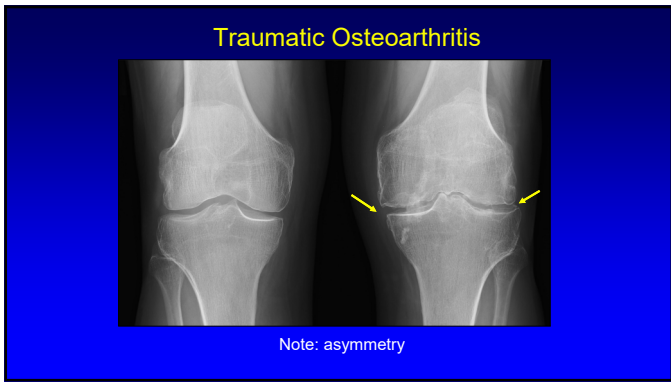
60



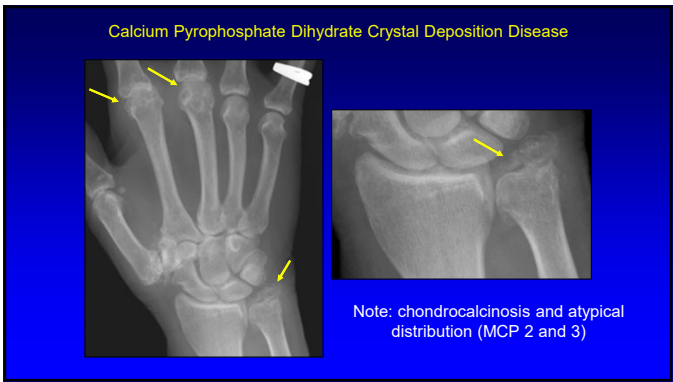
61



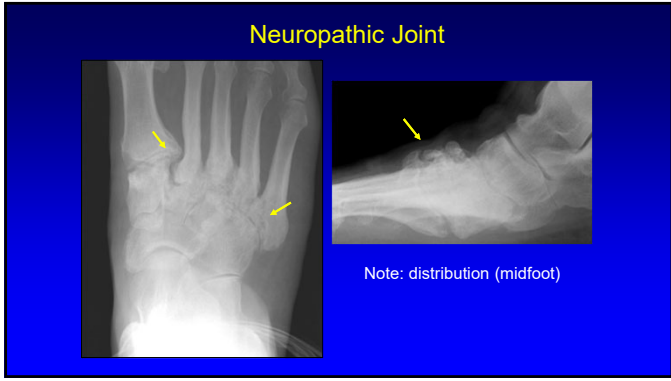
62



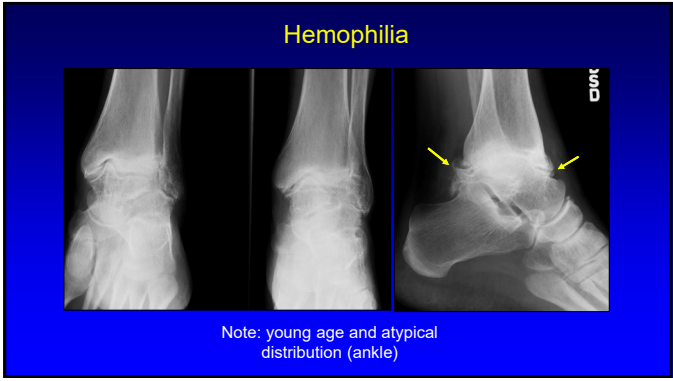
63



64



65



66

### Outline

- Meniscal tear
- Osteomyelitis
- Arthritis
- **Mass**
- "Cyst" on MRI

67

### Mass Algorithm

Bone	Synovial Space <small>Joint, bursa, tendon sheath</small>	Other
<ul style="list-style-type: none"> <li>• &gt; 40 years old</li> <li>✓ Mets</li> <li>✓ Myeloma</li> <li>• Primary tumor</li> <li>• Infection</li> </ul>	<ul style="list-style-type: none"> <li>• Inflammatory</li> <li>✓ Rheumatoid</li> <li>✓ TB, fungal</li> <li>• Proliferative</li> <li>✓ PVNS</li> <li>✓ Synovial chondromatosis</li> <li>✓ Amyloid</li> <li>✓ Hemophilia</li> </ul>	<ul style="list-style-type: none"> <li>• Sarcoma</li> <li>• Lymphoma</li> <li>• Met</li> <li>• Infection</li> </ul>

68

### Pigmented Villonodular Synovitis

69

### Pigmented Villonodular Synovitis

Gradient Echo

70

### Outline

- Meniscal tear
- Osteomyelitis
- Arthritis
- Mass
- "Cyst" on MRI

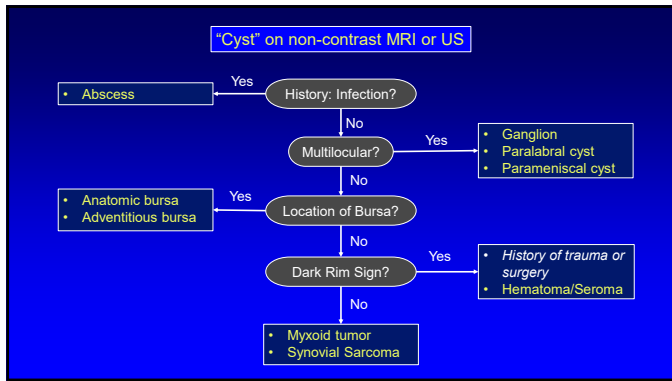
71

### Synovial Sarcoma

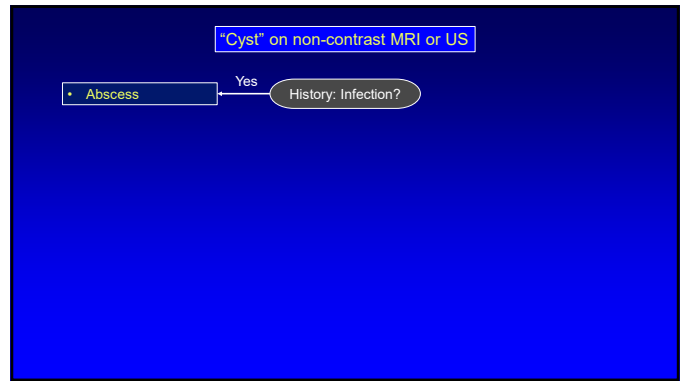
Sagittal T1w      TSE/M      Sagittal T2w      Axial T2w

Teaching Point:  
All that is bright on T2w is not a cyst

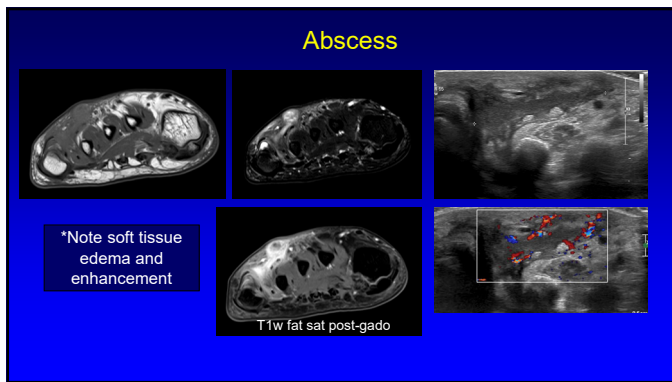
72



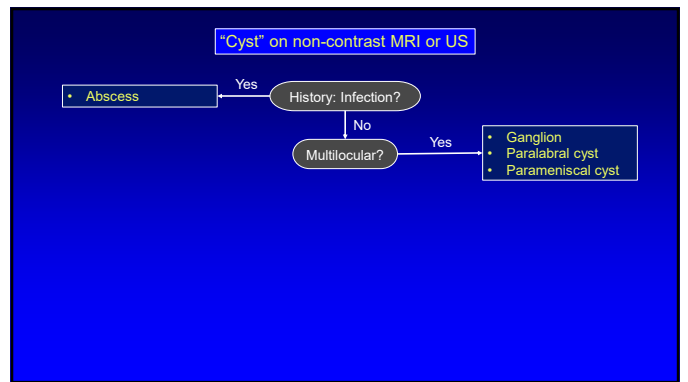
73



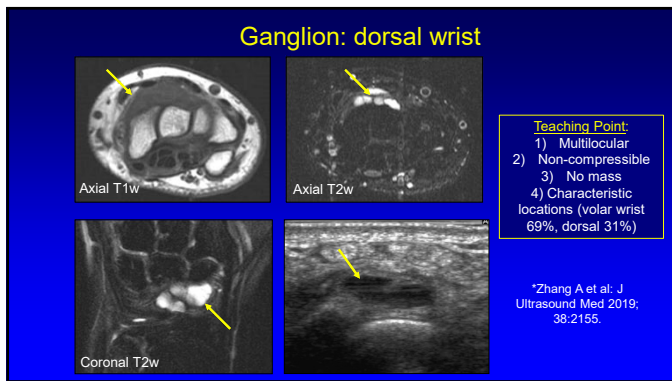
74



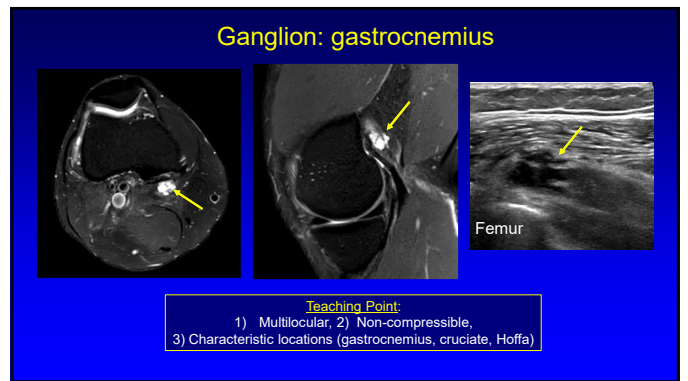
75



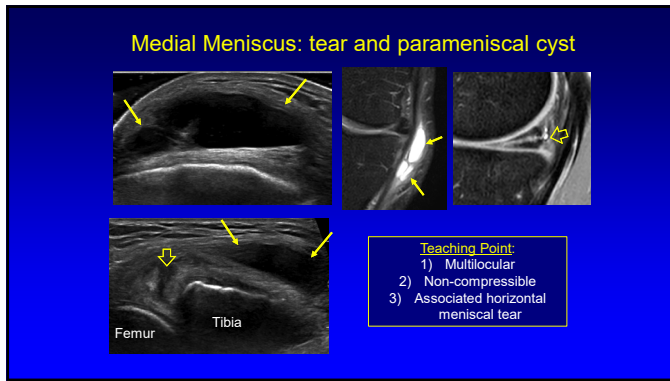
76



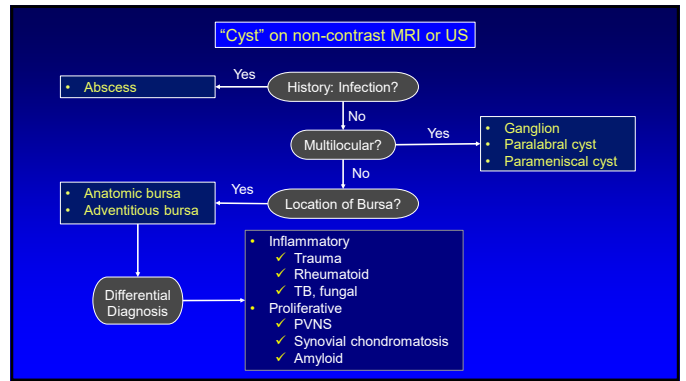
77



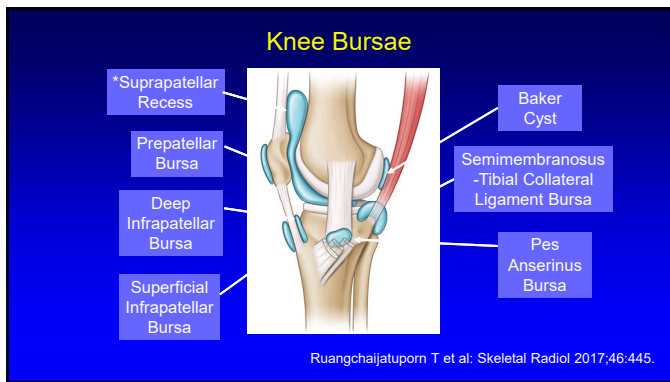
78



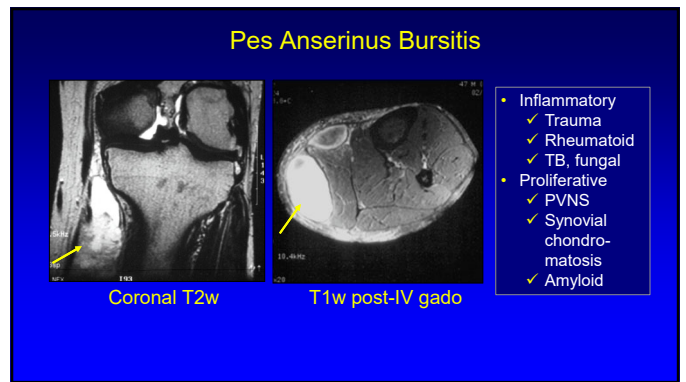
79



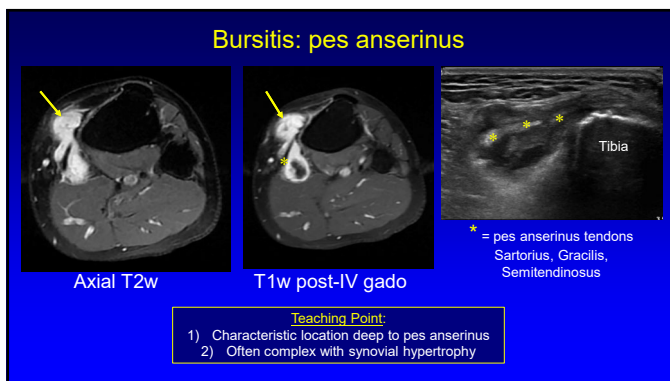
80



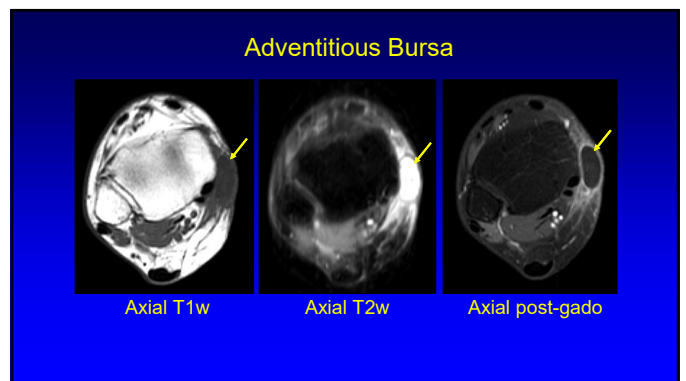
81



82



83



84

### Baker Cyst

**Teaching Point:**  
1) Must see characteristic "neck" between semimembranosus and medial gastrocnemius

Ward E et al: AJR 2001;176:373.

85

### Liposarcoma: myxoid/round cell

**Teaching Point:**  
No "neck" = not a Baker cyst!

86

### "Cyst" on non-contrast MRI or US

```

    graph TD
      A["Abscess"] -- Yes --> B{History: Infection?}
      B -- No --> C{Multilocular?}
      C -- Yes --> D["Ganglion  
Paralabral cyst  
Parameniscal cyst"]
      C -- No --> E{Location of Bursa?}
      E -- Yes --> F["Anatomic bursa  
Adventitious bursa"]
      E -- No --> G{Dark Rim Sign?}
      G -- Yes --> H["History of trauma or surgery  
Hematoma/Seroma"]
      G -- No --> I["Myxoid tumor  
Synovial Sarcoma"]
  
```

87

### Seroma

**Teaching Point:**  
1) Low signal rim from hemosiderin  
2) High T1w signal on fat-sat with no internal enhancement  
3) Mural nodules are okay

Lantos JE et al: AJR 2014;202:1297.

88

### "Cyst" on non-contrast MRI or US

```

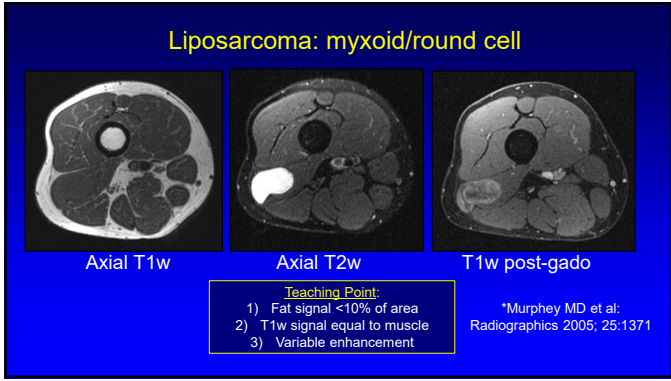
    graph TD
      A["Abscess"] -- Yes --> B{History: Infection?}
      B -- No --> C{Multilocular?}
      C -- Yes --> D["Ganglion  
Paralabral cyst  
Parameniscal cyst"]
      C -- No --> E{Location of Bursa?}
      E -- Yes --> F["Anatomic bursa  
Adventitious bursa"]
      E -- No --> G{Dark Rim Sign?}
      G -- Yes --> H["History of trauma or surgery  
Hematoma/Seroma"]
      G -- No --> I["Myxoid tumor  
Synovial Sarcoma"]
  
```

89

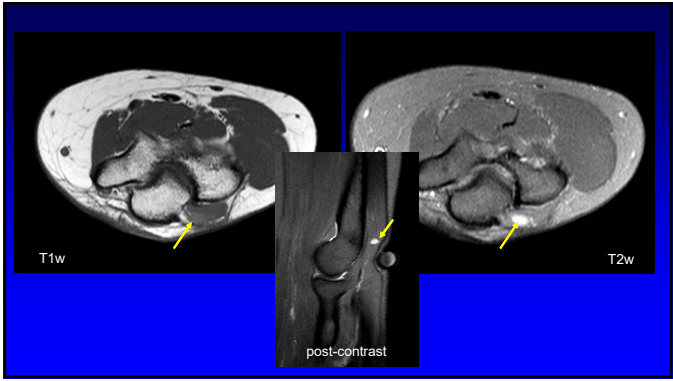
### Intramuscular Myxoma

**Teaching Point:**  
1) Low T1 signal and variable enhancement  
2) US: increased through transmission  
3) Location (thigh)

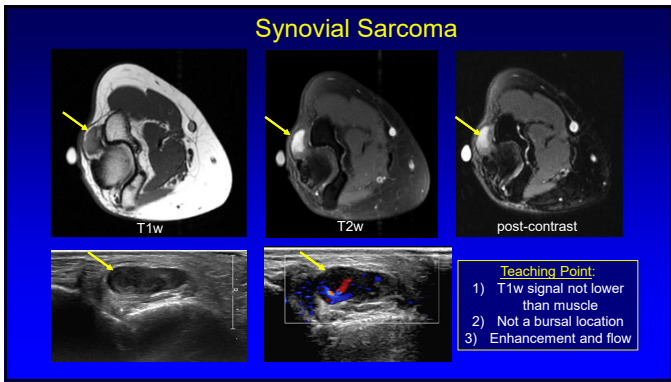
90



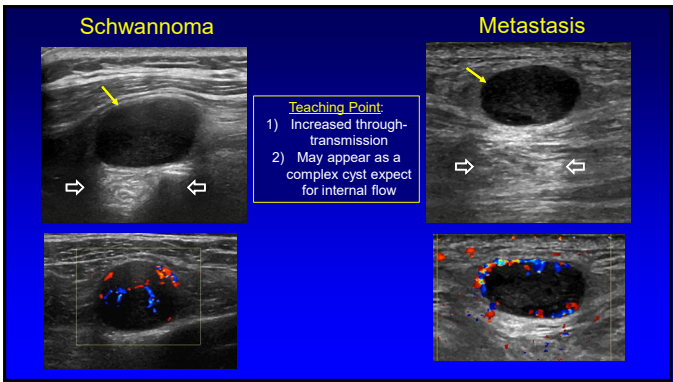
91



92



93



94

Thank you!

Syllabus on line and other educational material:  
[www.jacobsonmskus.com](http://www.jacobsonmskus.com)

Twitter handle: @jjacobsn

95