

An Algorithmic Approach to Imaging of Musculoskeletal Pathology

Jon A. Jacobson, MD, FACR

Professor of Radiology
Section Chief, Musculoskeletal Imaging
University of Cincinnati



1

Disclosures

- Consultant: Bioclinica
- Contractor: POCUS PRO
- Book Royalties: Elsevier
- Not relevant to this lecture

*Note: all images from the textbook
Fundamentals of Musculoskeletal Ultrasound
are copyrighted by Elsevier Inc.*

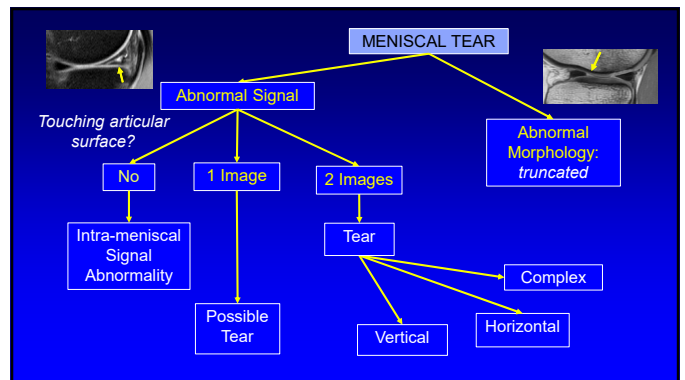
See www.jacobsonmskus.com for syllabus other educational material

2

Outline

- Meniscal tear
- Osteomyelitis
- Arthritis
- Mass
- "Cyst" on MRI
- Periostitis
- Bone marrow

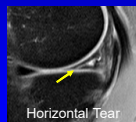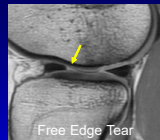3



4

Meniscus Tear: MRI criteria

- Abnormal morphology
 - Truncation, absence
- Abnormal signal
 - Extends to articular surface (unequivocally)
 - Two consecutive or orthogonal images
 - "Two-slice-touch rule"



5

Meniscus Tear: MRI criteria


- Positive predictive value for meniscus tear: One slice versus two slice touch


	1 Slice	2 Slice
Medial Meniscus	43%	94%
Lateral Meniscus	18%	96%
Reporting	"Possible Tear"	"Tear"

Nguyen JC et al. Radiographics 2014; 34:981

6

Meniscus: internal signal

- Not in contact with articular surface
- Vascularity (periphery): children
- Radial tie fibers (periphery)¹ → 
- Contusion: globular, ill-defined²
- Degenerative signal
 - If linear in medial meniscus: progress to tear
 - If middle aged without osteoarthritis³

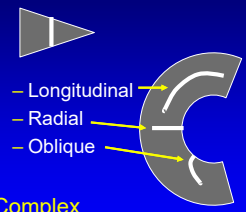


¹Hauger O et al. Radiology 2000; 217:340
²Cothran RJ et al. AJR 2001; 177:1189
³Kumm J et al. Radiology 2015; 278:164

7

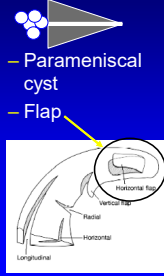
Meniscus Tear: MRI Classification

Vertical




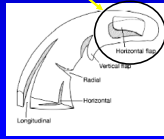
- Longitudinal
- Radial
- Oblique

Horizontal



- Parameniscal cyst
- Flap

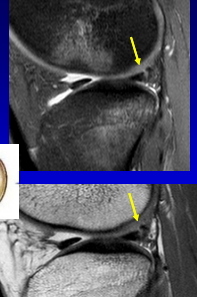

Complex

8

Meniscal Tear: vertical

- Longitudinal: non-displaced
- Usually peripheral
- Often traumatic
- Associated with ACL tears
 - 90% of medial tears
 - 83% of lateral tears
- >1 cm in length: unstable
- Pitfall: meniscofemoral ligament of Wrisberg

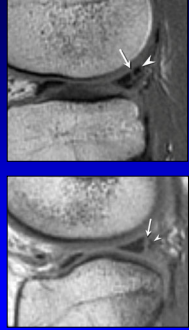
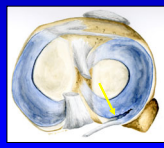



Nguyen JC et al. Radiographics 2014; 34:981

9

PHLM Rip Tear

- Longitudinal tear PHLM
- Associated with ACL tears
- Pitfall: continuous with meniscofemoral ligament
- Cleft >3 images lateral to PCL (>10 mm) = tear






Park et al. Skeletal Radiol 2007; 36:399

10

Meniscal Tear: vertical

- Longitudinal: displaced
 - Bucket-handle
 - Medial > lateral
 - Double-PCL (medial)
 - Intact meniscal ring
- Pitfall: oblique meniscomeniscal ligament

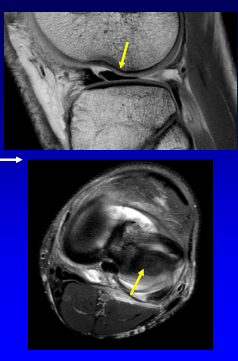




Nguyen JC et al. Radiographics 2014; 34:981

11

Meniscal Tear: vertical

- Longitudinal: displaced
 - Flipped fragment
 - Connected at one end →
 - Free fragment

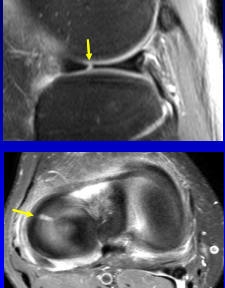




Lance V et al. Skeletal Radiol 2015; 44:375

12

Meniscal Tear: vertical

- Radial
- Incomplete or complete
- Free edge tear
- Disrupted bow tie appearance of meniscus





Nguyen JC et al. Radiographics 2014; 34:981

13

Meniscal Tear: vertical

- Radial
- Root tear
- "Ghost meniscus"
 - Absent on one slice
- Possible meniscal extrusion (relative to tibia)





Choi JY et al. AJR 2014; 203:1286

14

Meniscal Tear: vertical

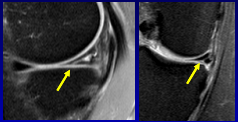
- Oblique vertical
 - Parrot beak
 - Vertical flap tear

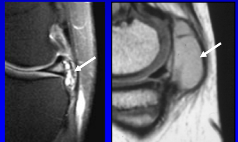
15

Meniscal Tear: horizontal

- Often to or near apex
- Parameniscal cyst
 - Multilocular
 - Axial plane around meniscus
 - Medial: away from meniscus
- Pitfall: AHLM ganglion cyst



Horizontal Tears



Parameniscal Cysts

Nguyen JC et al. Radiographics 2014; 34:981

16

Meniscal Tear: horizontal

- Horizontal flap tear
- Flap: deep to MCL
 - May not be low signal
- Superior 6x > inferior
- Key: truncated meniscus
- Also: hemi-bucket handle




Lucas LK et al. AJR 2000; 174:161
Engstrom SK et al. Skeletal Radiol 2012; 41:933

17

Meniscal Tear: complex

- Does not fit into one specific tear pattern
- Often degenerative and macerated




18

Outline

- Meniscal tear
- **Osteomyelitis**
- Arthritis
- Mass
- "Cyst" on MRI
- Periostitis
- Bone marrow

19

Osteomyelitis: adult

Soft tissue ulcer?

```

    graph TD
      A[Soft tissue ulcer?] -- Yes --> B[T2w: High Signal]
      A -- No --> C[Normal probably]
      B -- High --> D[T1w Signal]
      B -- None --> E[Normal]
      D -- Low --> F[Osteomyelitis]
      D -- Normal --> G[Reactive Edema]
      E --> G
  
```

IV Contrast: delineates abscess and sinus tracks

**In the absence of ulcer, surgery, or penetrating injury, osteomyelitis of foot is rare*

20

Osteomyelitis: 5th metatarsal

21

Reactive Edema

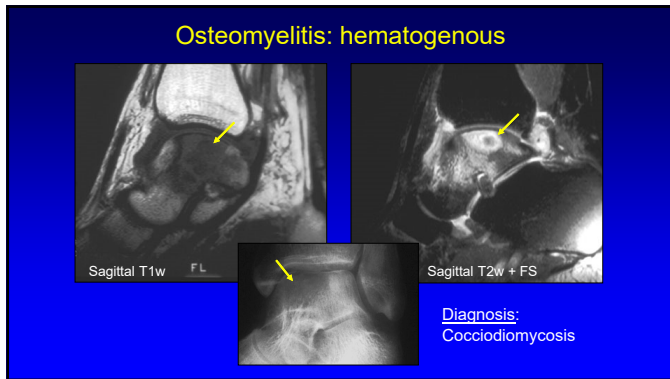
22

Osteomyelitis: femur

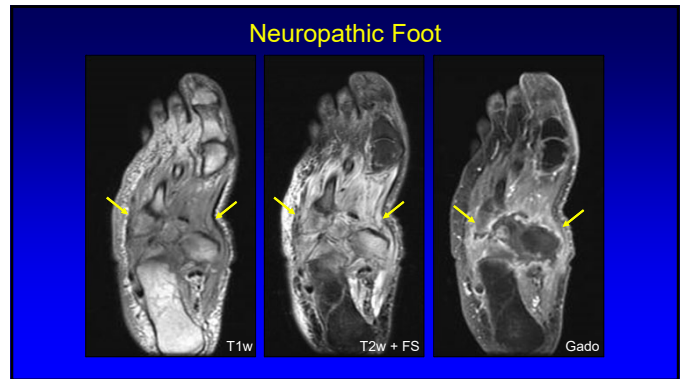
23

Osteomyelitis

24



25



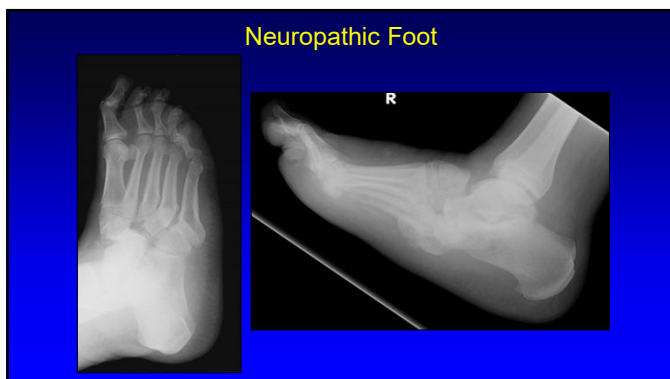
26

- ### Neuropathic Foot
- Loss of proprioception and deep sensation
 - Relaxation, hypotonia
 - Recurrent injury
 - Malalignment
 - Joint destruction and disorganization
 - Location: determined by disease
 - Diabetes: lower extremity, esp. midfoot
 - Syring: upper extremity, spine

27

- ### Neuropathic Foot
- Bone marrow edema:
 - High T2w
 - T1w: variable, often normal
 - **No** adjacent ulcer
 - Multiple joints: esp. **midfoot**
 - Osteomyelitis: 5th MT > 1st MT > calcaneus
 - Subluxation
- Radiology 2002; 224:649

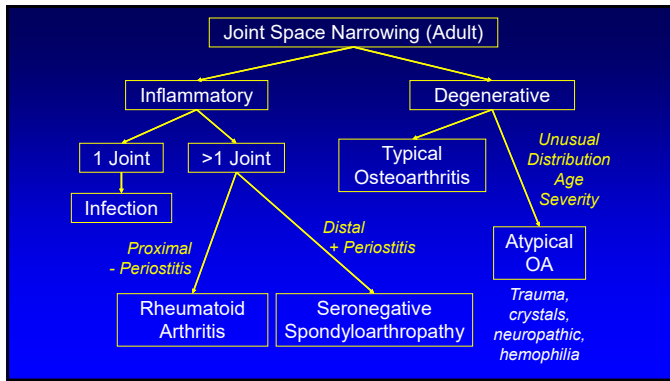
28



29

- ### Outline
- Meniscal tear
 - Osteomyelitis
 - **Arthritis**
 - Mass
 - “Cyst” on MRI
 - Periostitis
 - Bone marrow

30



31

Radiographic Algorithm: adult

- Starting point: joint space narrowing
- Inflammatory versus degenerative arthritis


*Evaluation of Arthritis: Inflammatory Conditions. Radiology 2008; 248:378-389

*Evaluation of Arthritis: Degenerative Joint Disease and Variations. Radiology 2008; 248:737-747

32

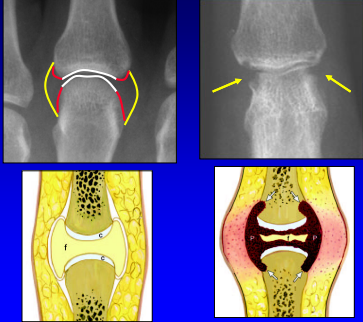
Inflammatory Arthritis

- Periarticular osteopenia
- Soft tissue swelling
- Erosions:
 - Initially marginal
 - Cortex discontinuous
- Joint space narrowing: **uniform**



33

Marginal Erosions: rheumatoid arthritis



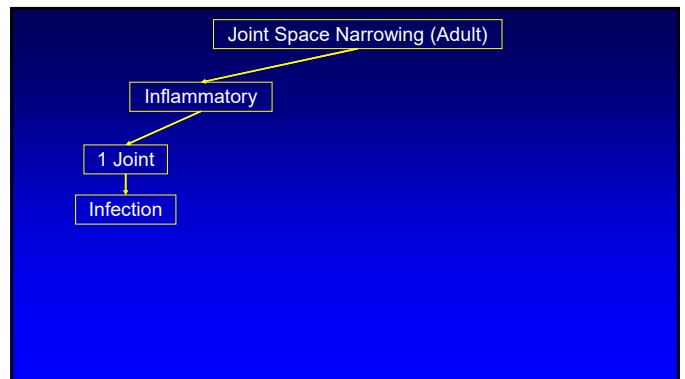
34

Degenerative Arthritis:

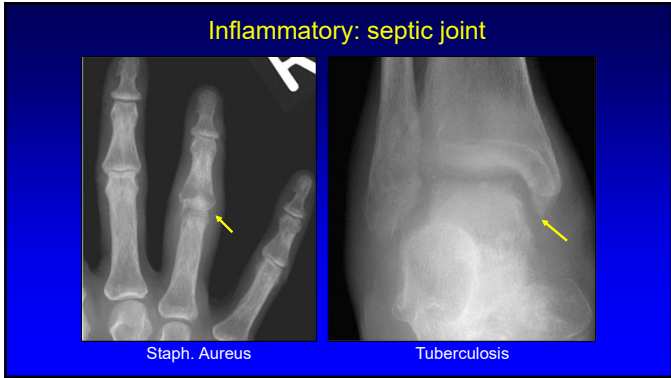
- Joint space narrowing: not uniform
- Normal mineralization
- Osteophytes
- Sclerosis and eburnation



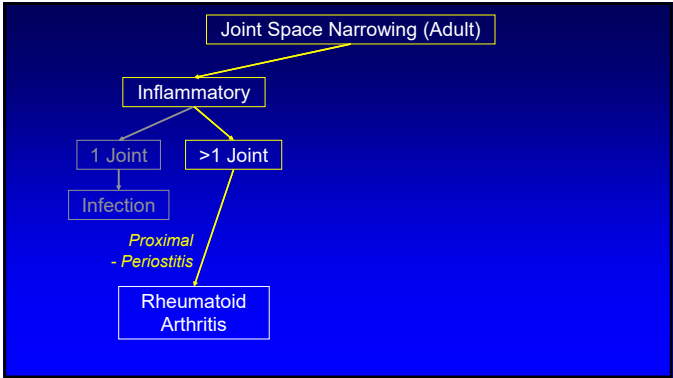
35



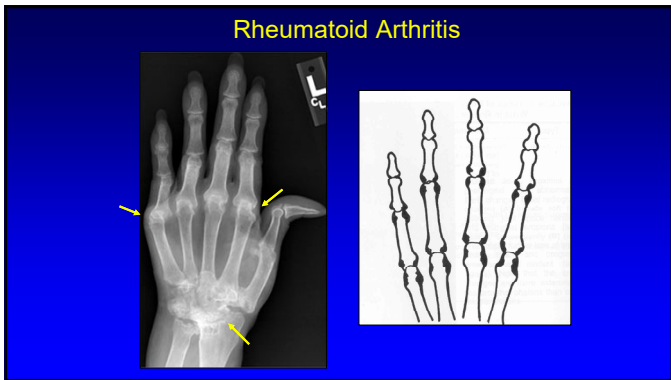
36



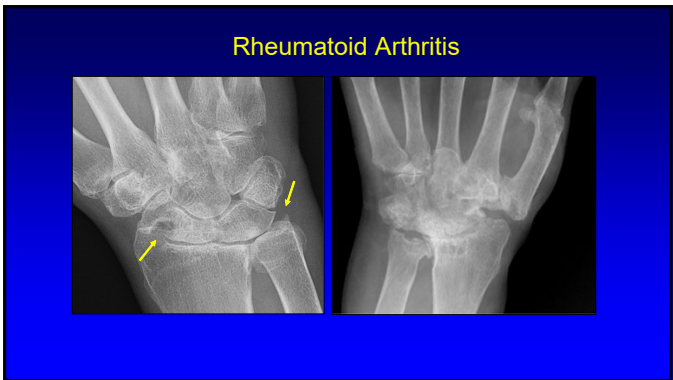
37



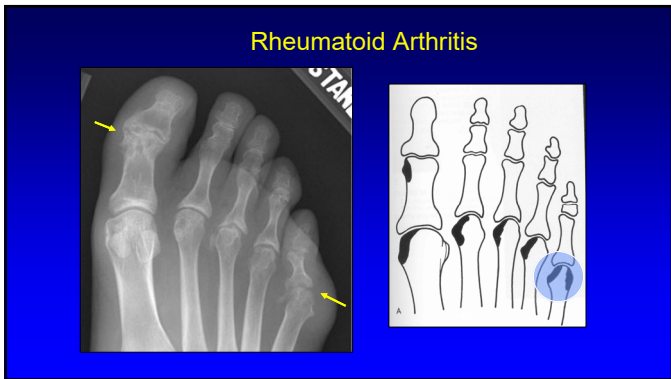
38



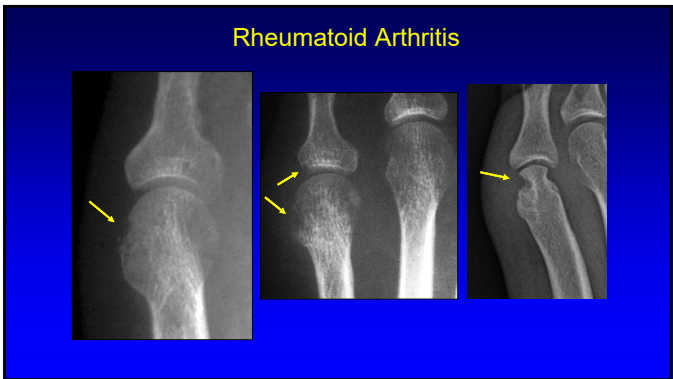
39



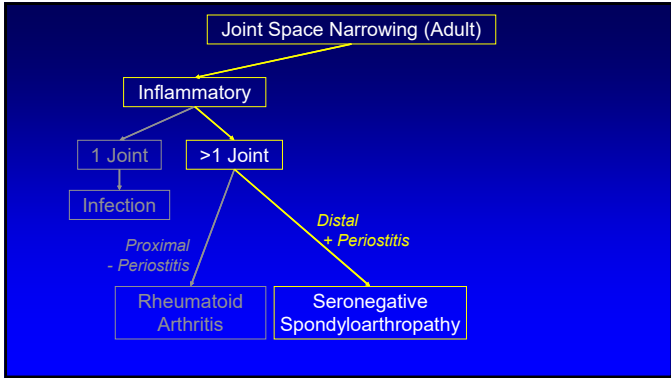
40



41



42



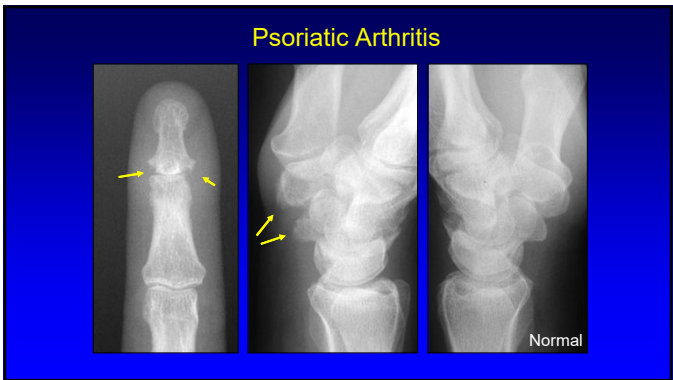
43

- Seronegative Spondyloarthritis:
- Synovial joints:
 - Erosions, uniform joint space narrowing
 - Periostitis
 - Cartilaginous joints: erosions
 - Enteses:
 - Tendon and ligament attachment
 - Fluffy enthesophytes, erosions

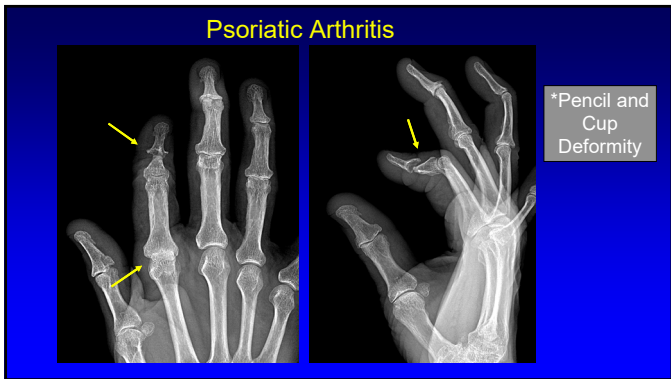
44

- Seronegative Spondyloarthritis:
- Key to diagnosis: **distribution**
 - Psoriasis: hands, feet, spine, SI joints
 - Reactive arthritis: feet, SI joints
 - Ankylosing spondylitis: axial skeleton, glenohumeral joints

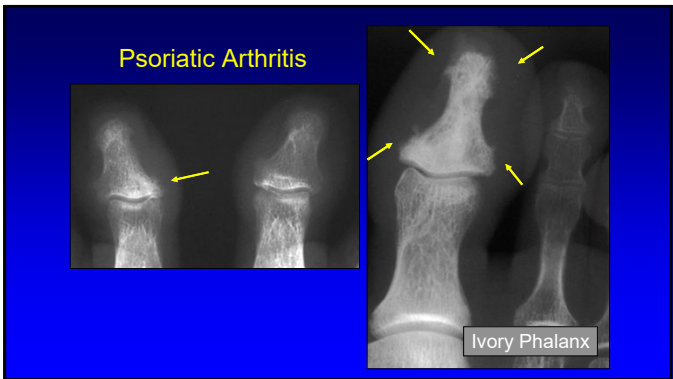
45



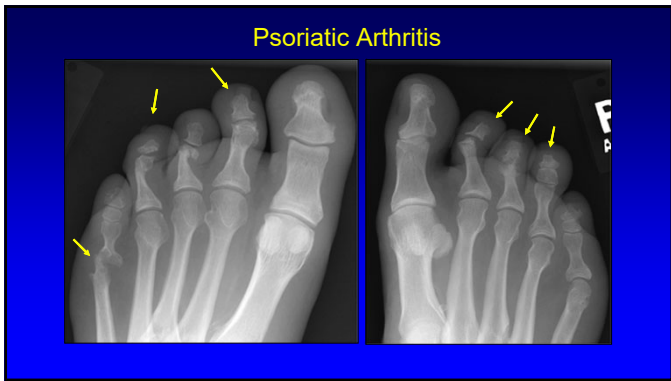
46



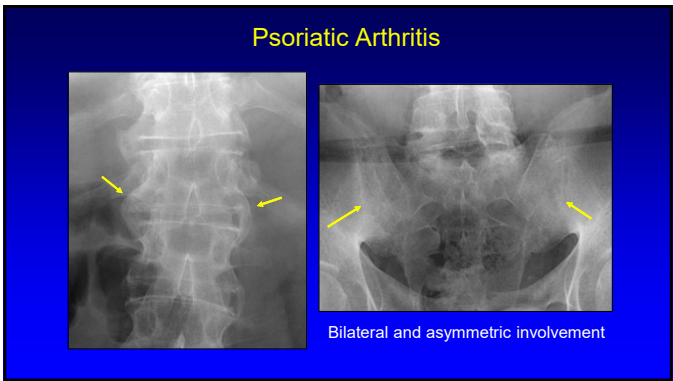
47



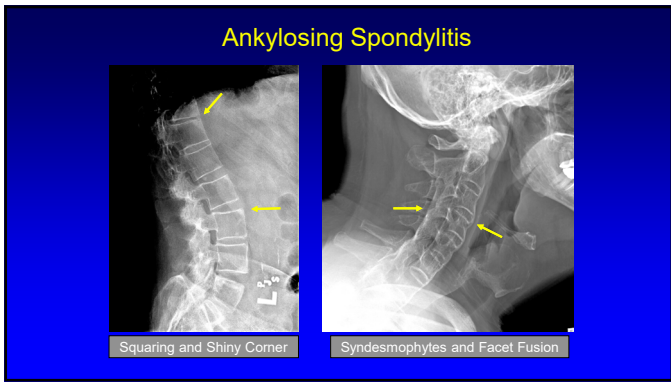
48



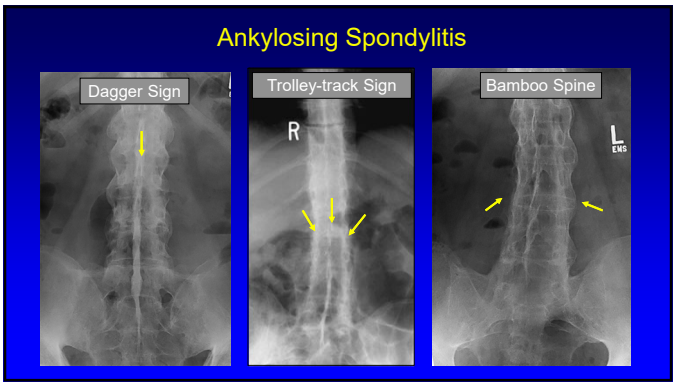
49



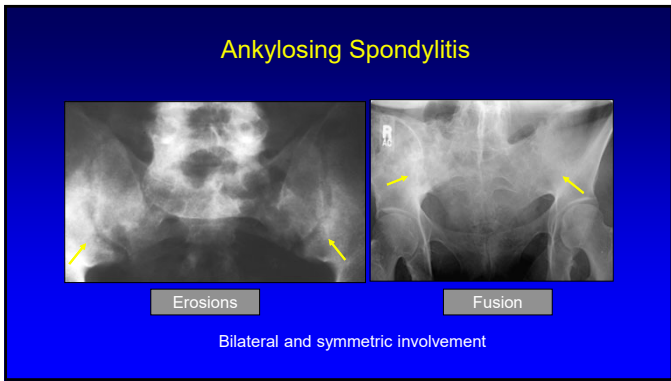
50



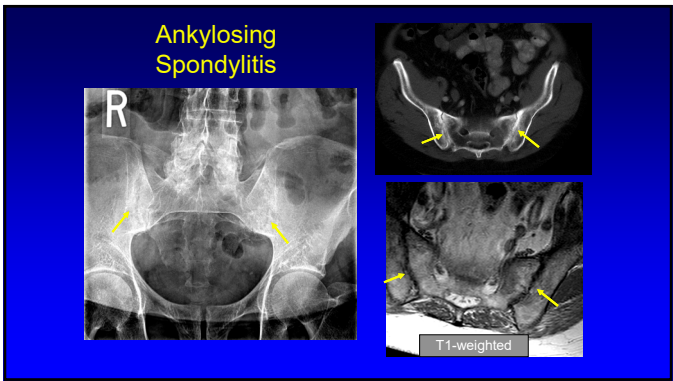
51



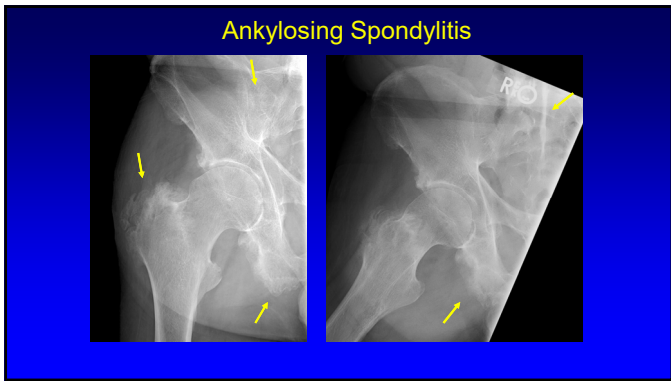
52



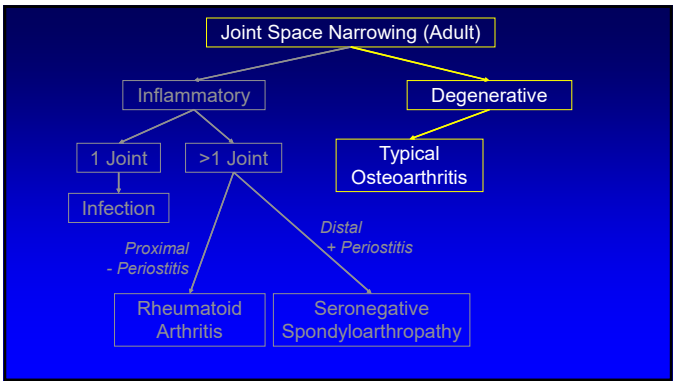
53



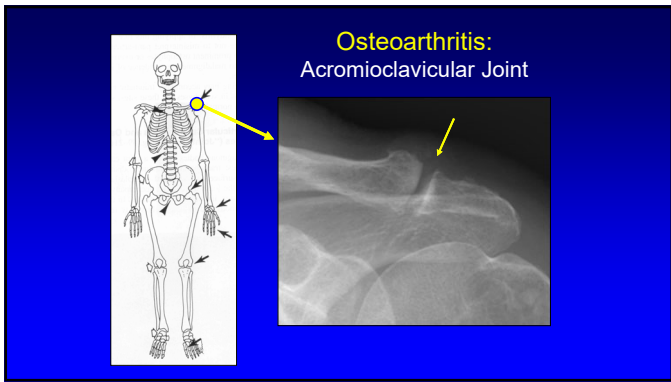
54



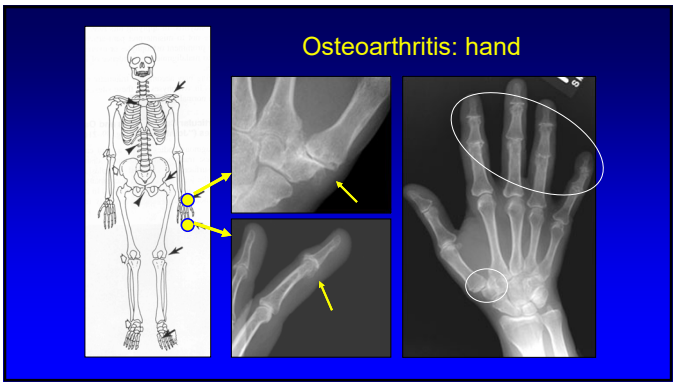
55



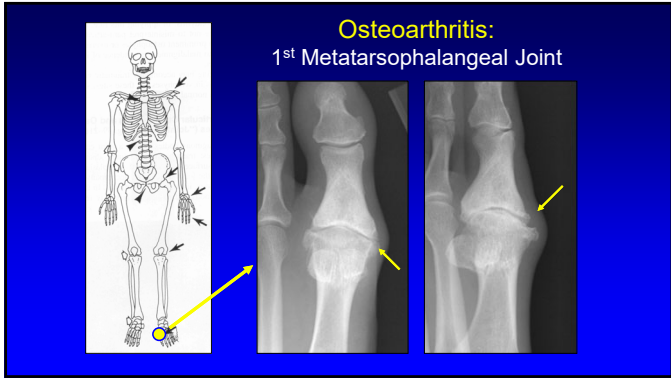
56



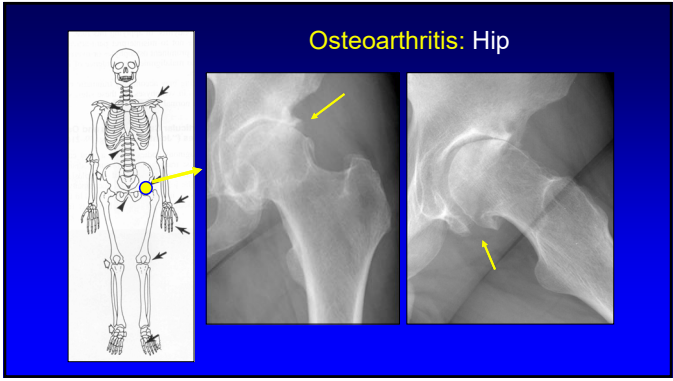
57



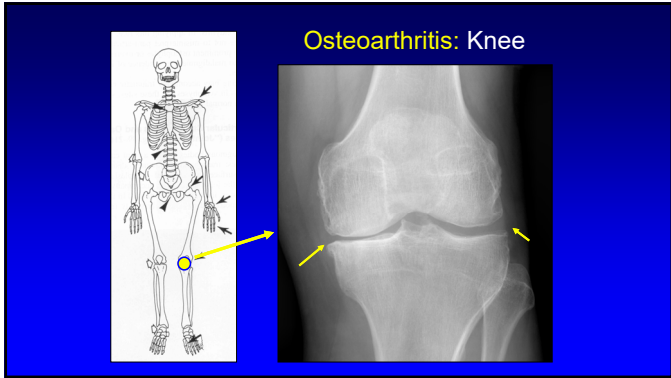
58



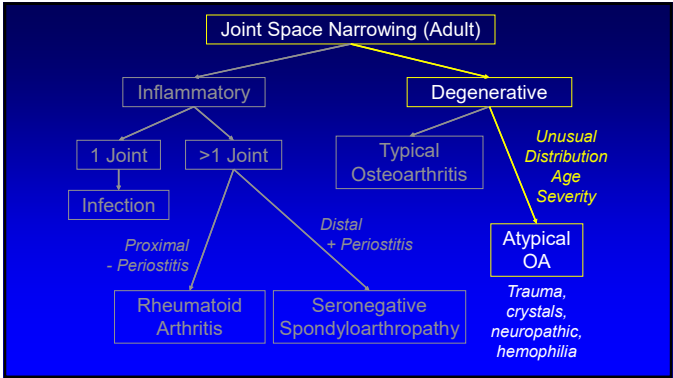
59



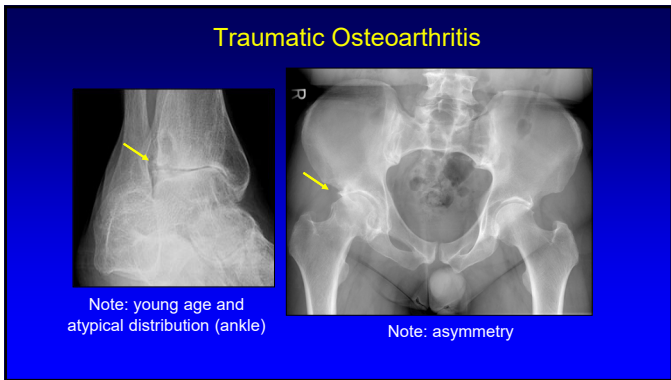
60



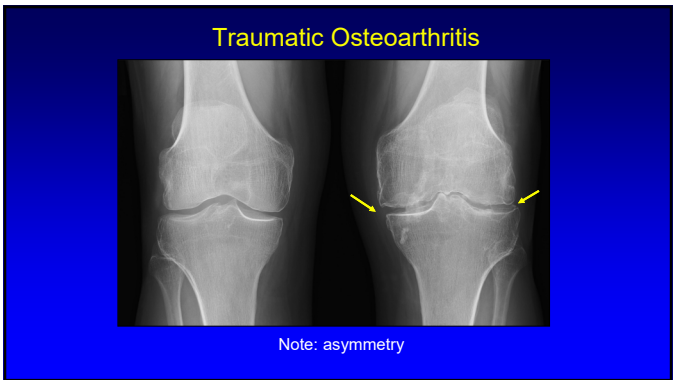
61



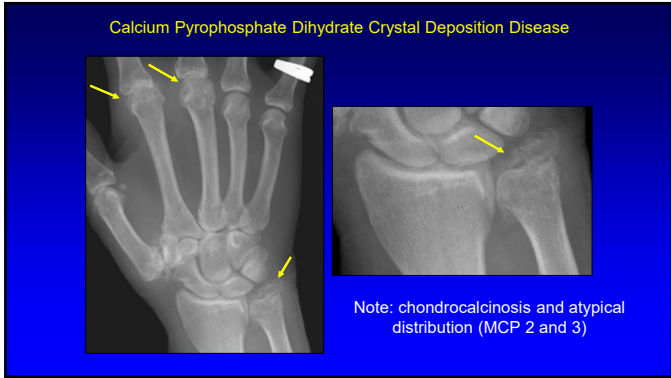
62



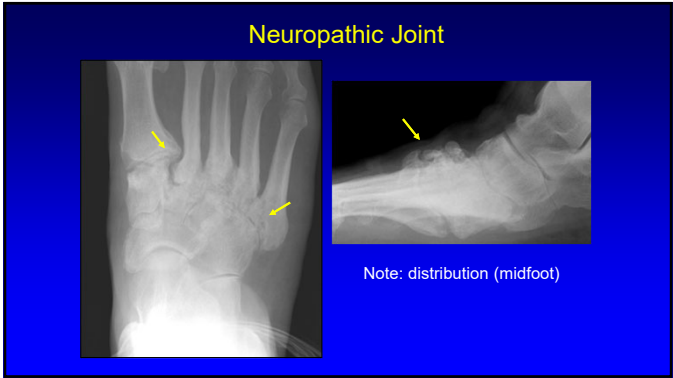
63



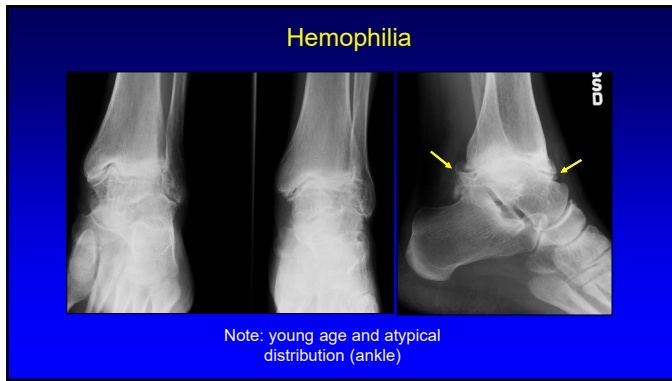
64



65



66

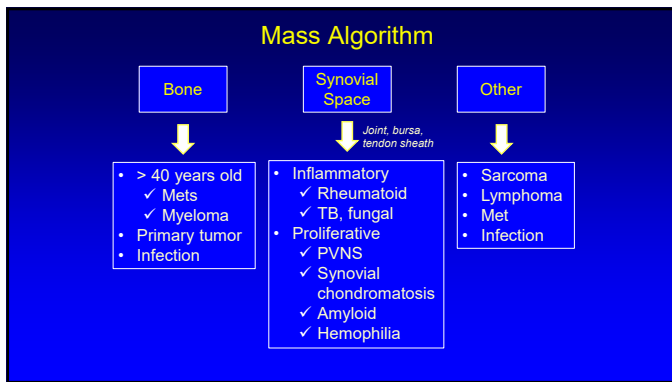


67

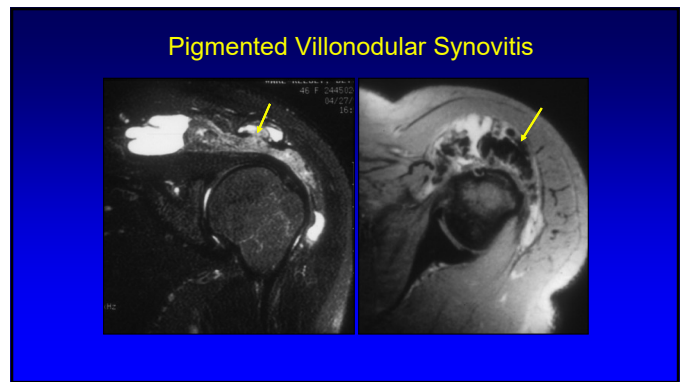
Outline

- Meniscal tear
- Osteomyelitis
- Arthritis
- **Mass**
- "Cyst" on MRI
- Periostitis
- Bone marrow

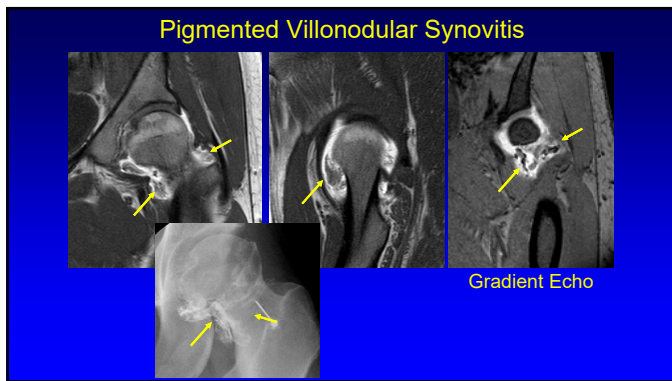
68



69



70

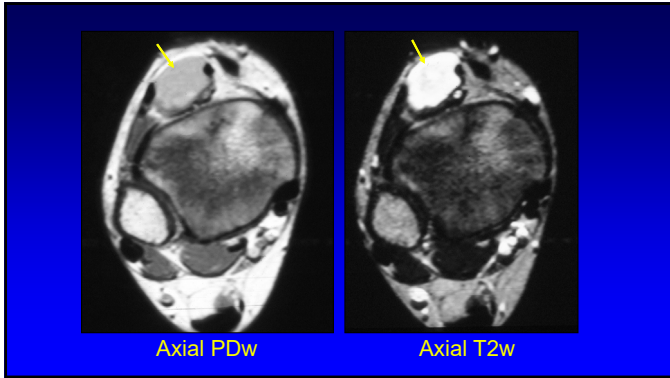


71

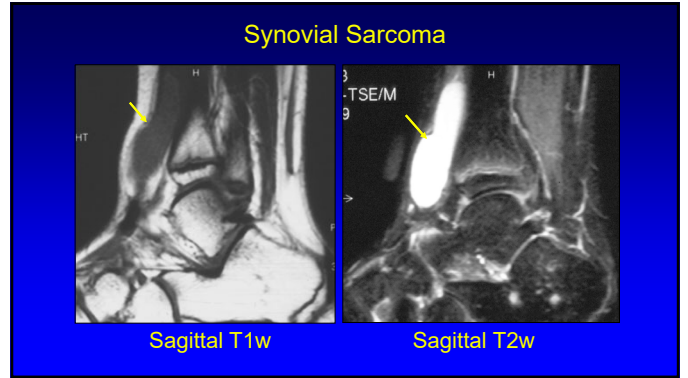
Outline

- Meniscal tear
- Osteomyelitis
- Arthritis
- **Mass**
- "Cyst" on MRI
- Periostitis
- Bone marrow

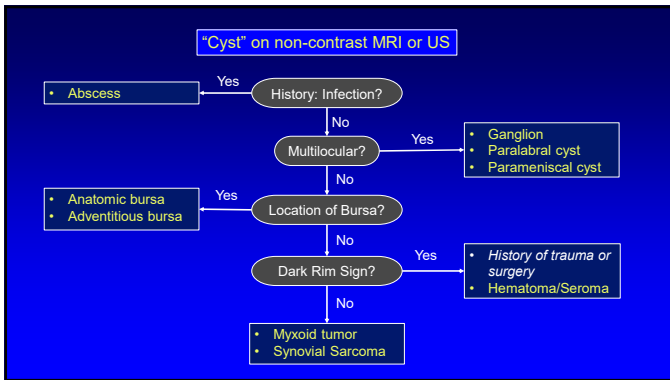
72



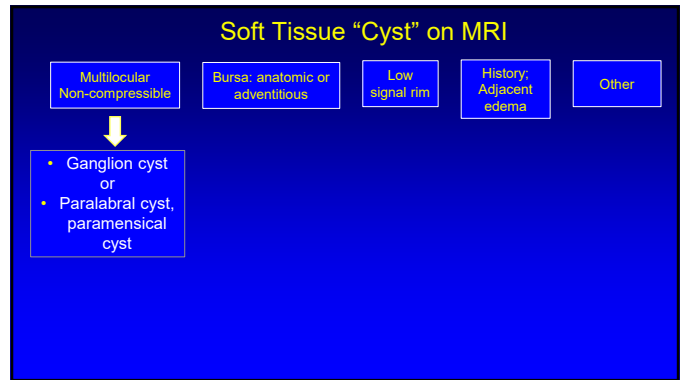
73



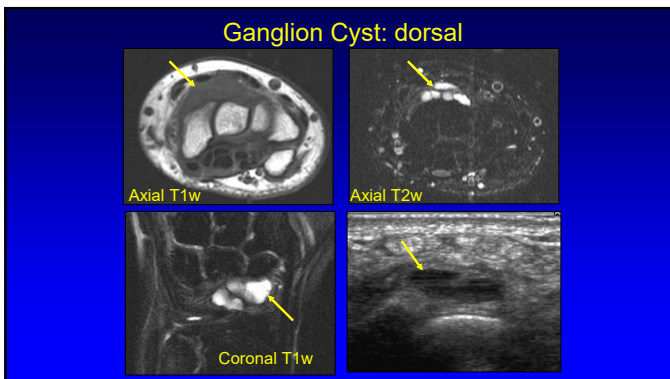
74



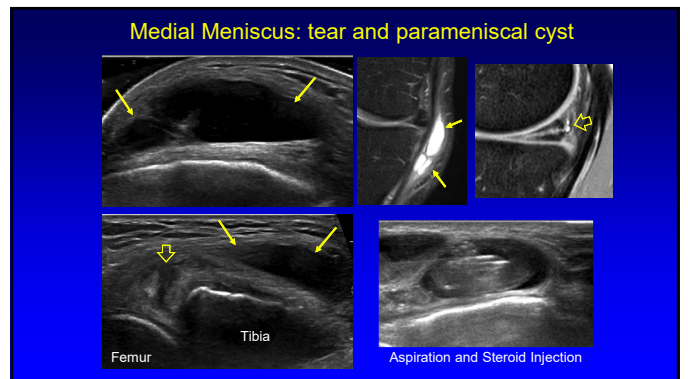
75



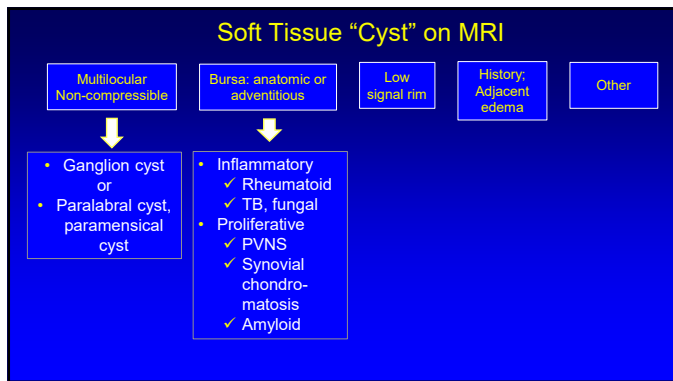
76



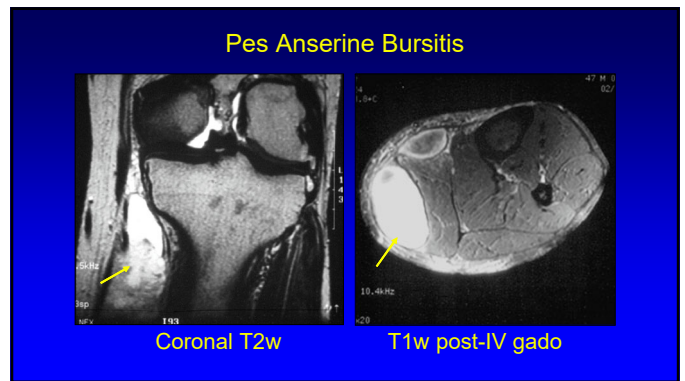
77



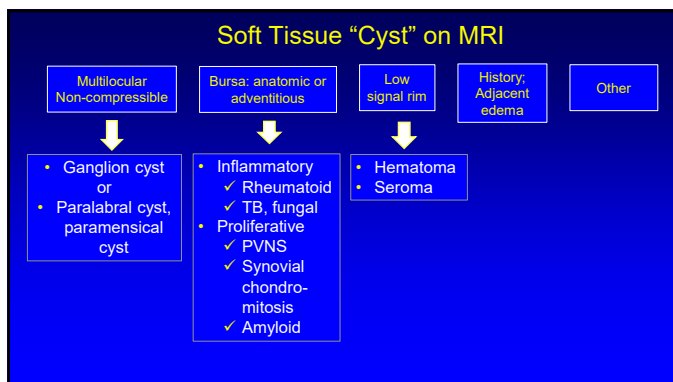
78



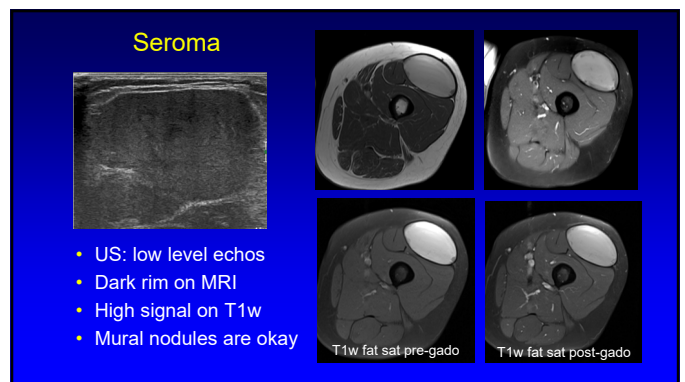
79



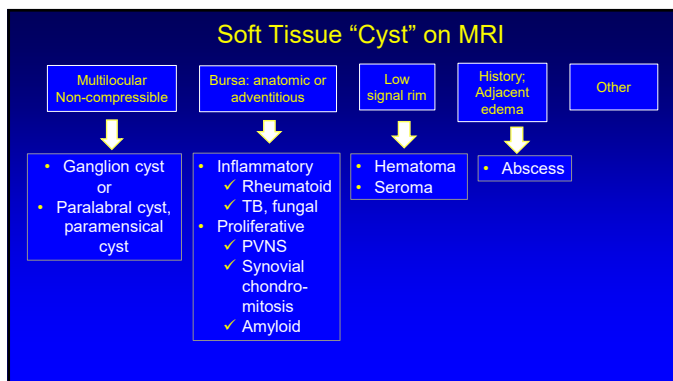
80



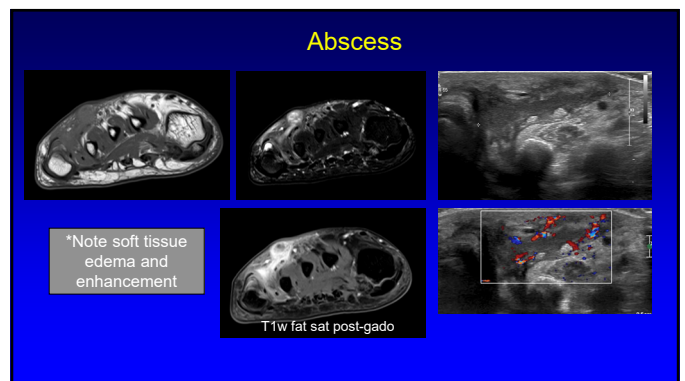
81



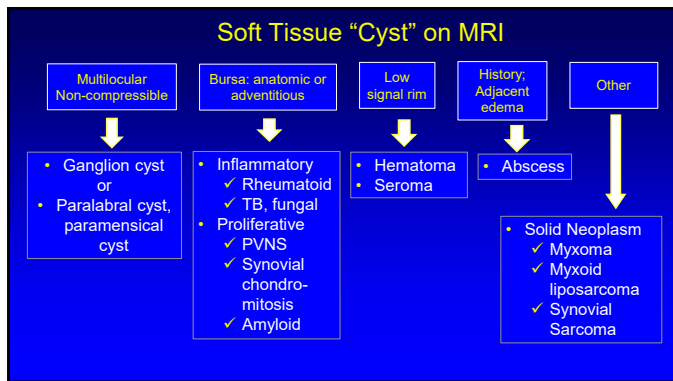
82



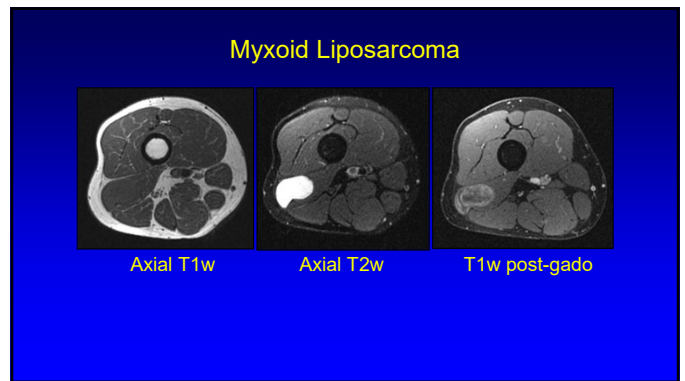
83



84



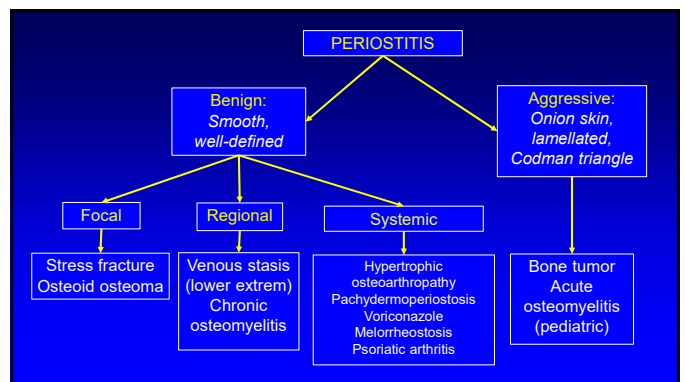
85



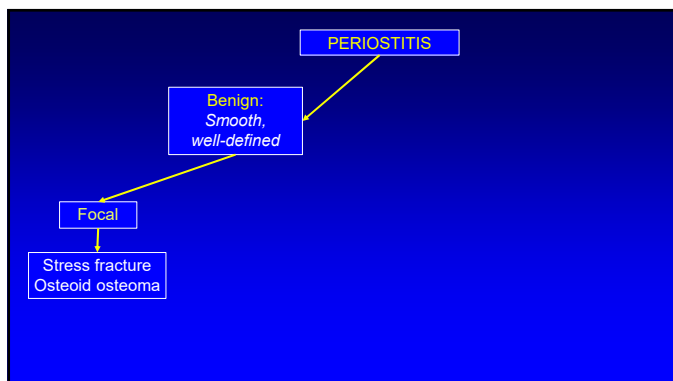
86

- ### Outline
- Meniscal tear
 - Osteomyelitis
 - Arthritis
 - Mass
 - "Cyst" on MRI
 - **Periostitis**
 - Bone marrow

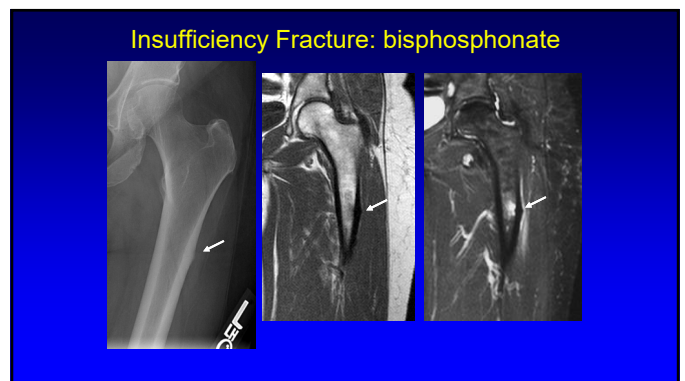
87



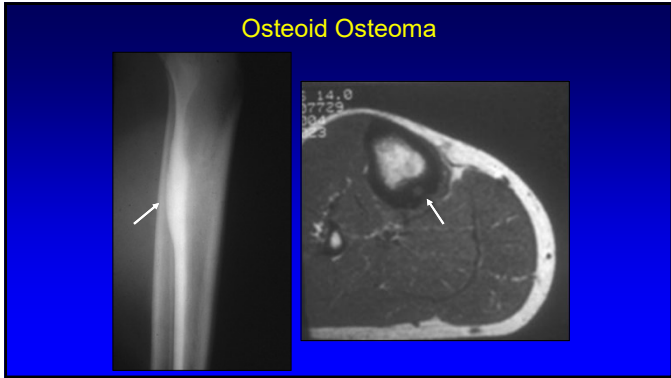
88



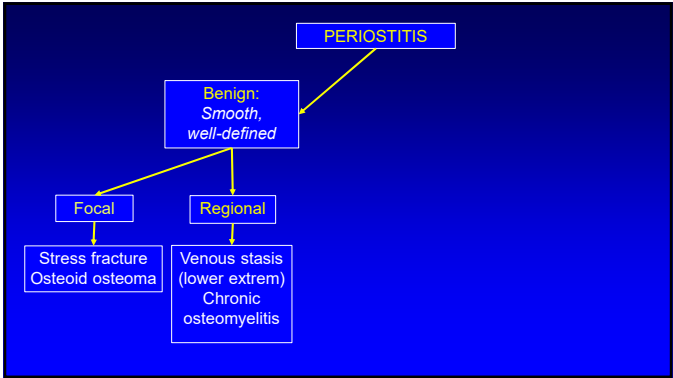
89



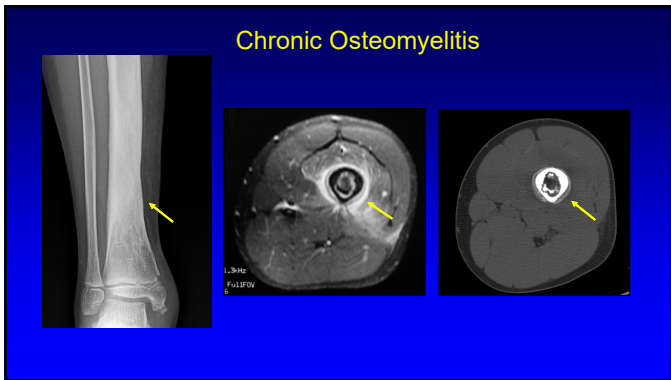
90



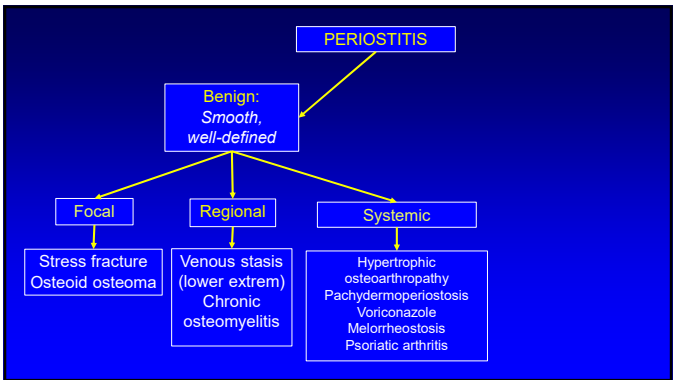
91



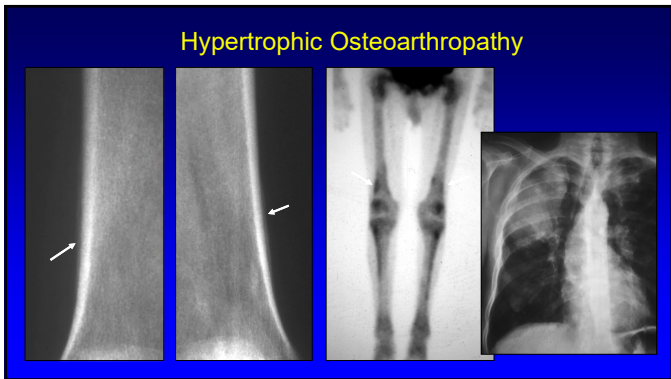
92



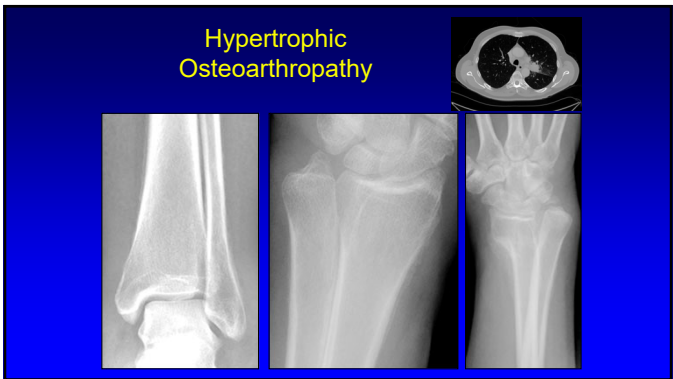
93



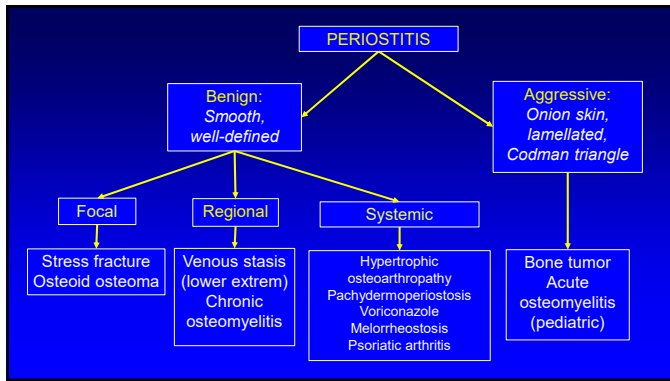
94



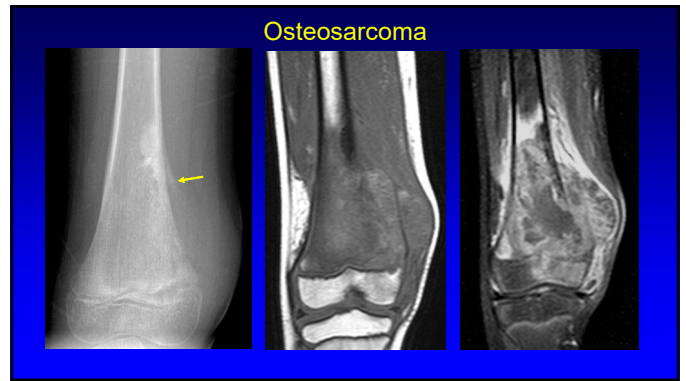
95



96



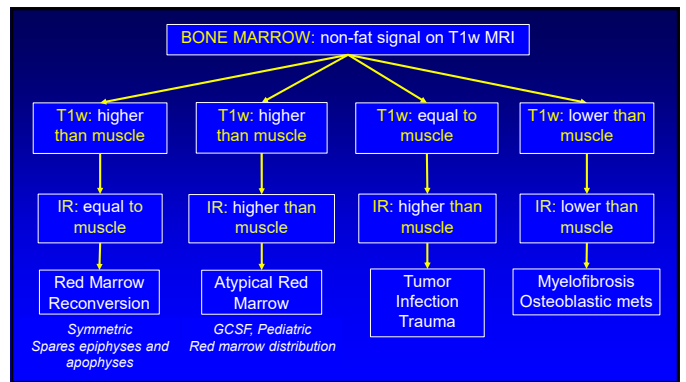
97



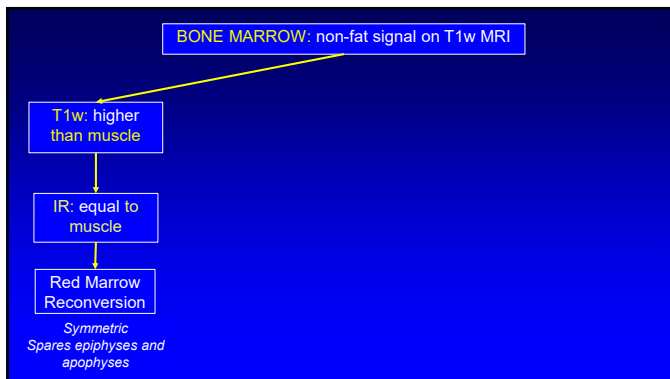
98

- Outline**
- Meniscal tear
 - Osteomyelitis
 - Arthritis
 - Mass
 - "Cyst" on MRI
 - Periostitis
 - **Bone marrow**

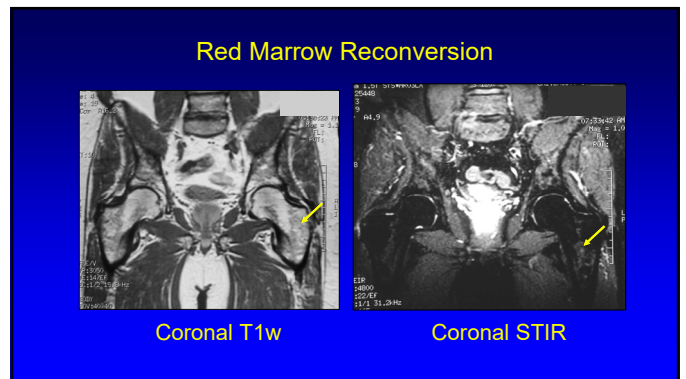
99



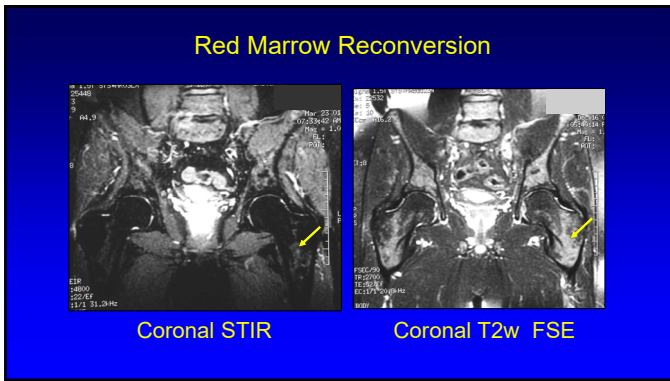
100



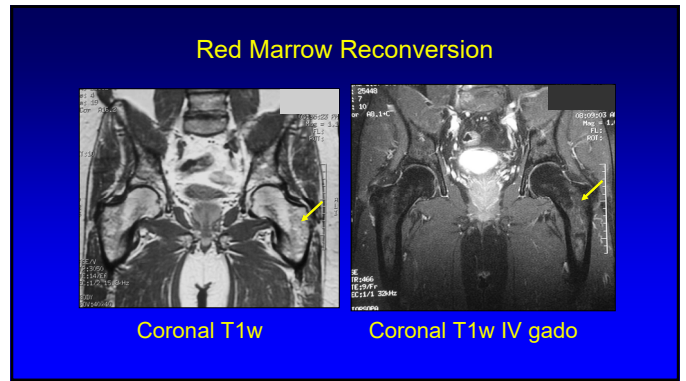
101



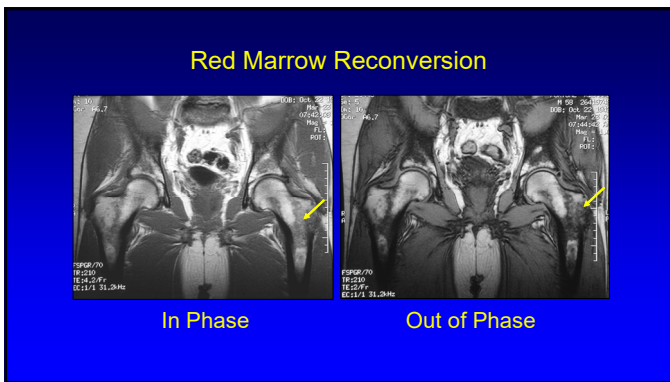
102



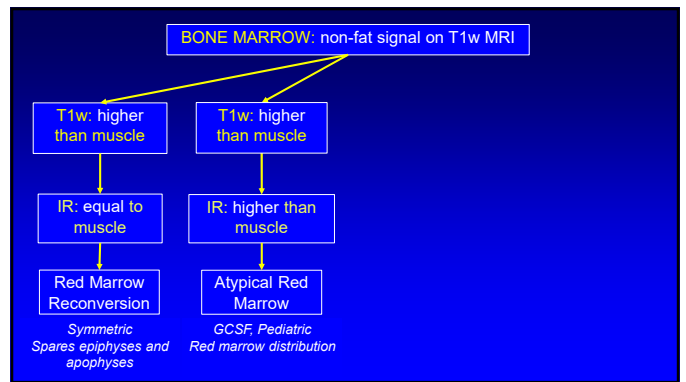
103



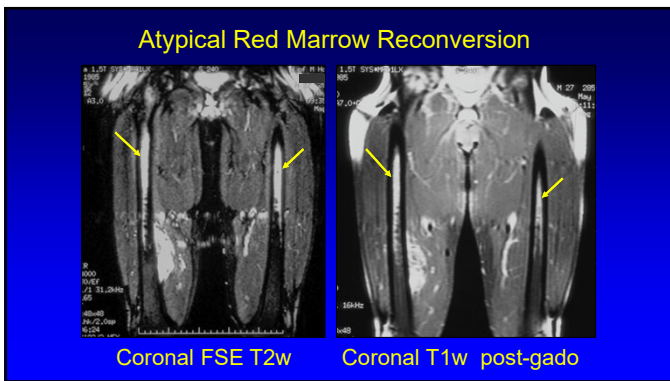
104



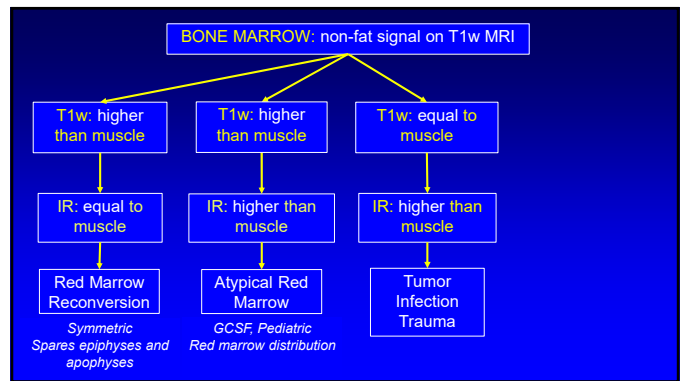
105



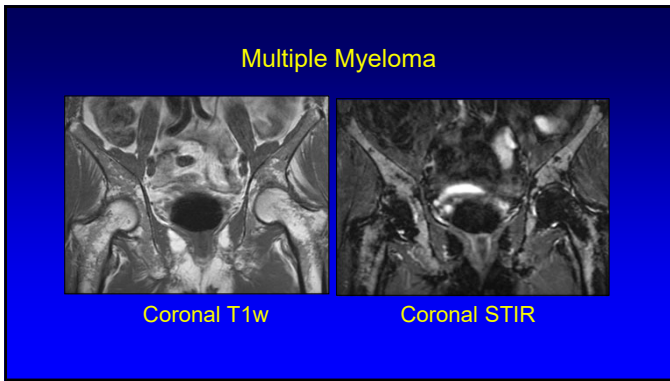
106



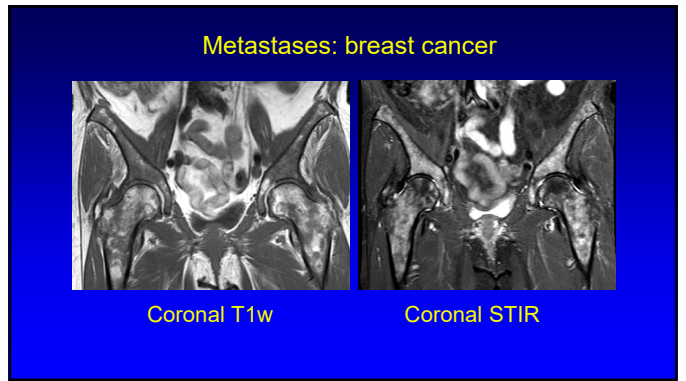
107



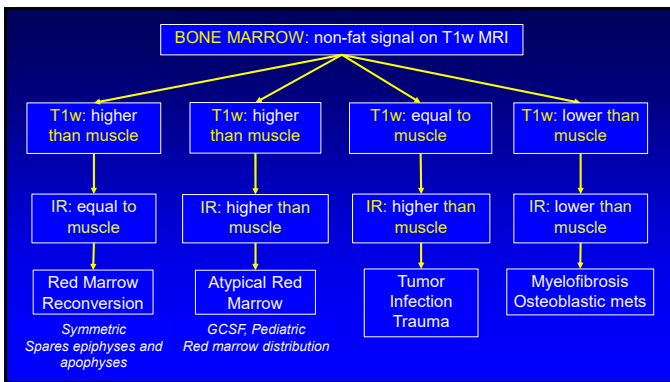
108



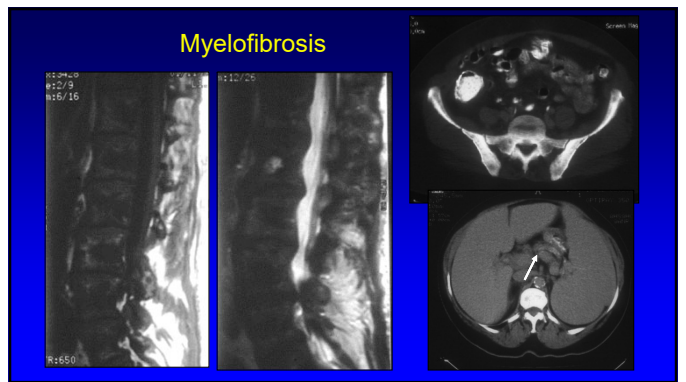
109



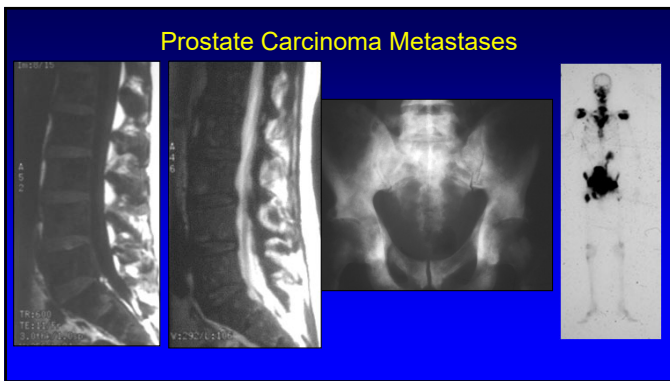
110



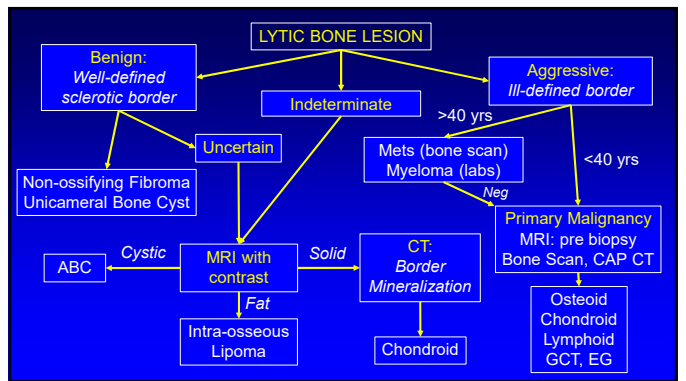
111



112



113



114

Take Home Points:

- Osteomyelitis: adult
 - Look at bone adjacent to ulcer
 - Radiograph: loss of cortical line
 - MRI:
 - High T2, low T1 = osteomyelitis
 - High T2, normal T1 = reactive edema
- Osteomyelitis: child
 - Subperiosteal abscess, periostitis

115



Syllabus on line and other educational material:
www.jacobsonmskus.com

Twitter handle: @jjacobsn

116