

Ultrasound of Nerve Entrapment: Lower Extremity

Jon A. Jacobson, MD
FACR, FSRU, FAIUM, RMSK

Professor of Radiology
Lenox Hill Radiology, NYC
University of California, San Diego

1

Disclosures

- Consultant: Bioclinica
- Contractor: POCUS PRO
- Advisory Board: Philips
- Book Royalties: Elsevier
- Not relevant to this lecture



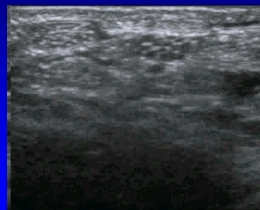
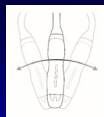
Syllabus PDF

See www.jacobsonmskus.com for syllabus other educational material

2

Normal Peripheral Nerve

- Ultrasound appearance:
 - Hypoechoic nerve fascicles
 - Hyperechoic connective tissue
- Transverse:
 - Honeycomb appearance



Silvestri et al. Radiology 1995; 197:291

Median Nerve

3

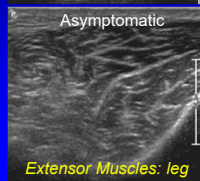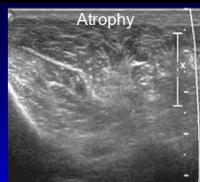
Nerve Entrapment

- US findings:
 - Nerve enlargement proximal to entrapment
 - Best appreciated transverse to nerve
 - Abnormally hypoechoic
 - Especially the connective tissue layers
 - Variable enlargement or flattening at entrapment site

4

Denervation

- Edema: hyperechoic
- Fatty degeneration:
 - Hyperechoic
 - Echogenic interfaces
- Atrophy:
 - Hyperechoic with decreased muscle size
- Compare to other side!



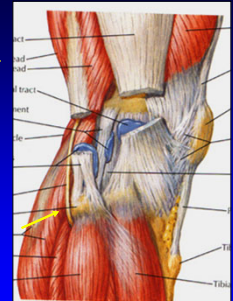
J Ultrasound Med 1993; 2:73

Extensor Muscles: leg

5

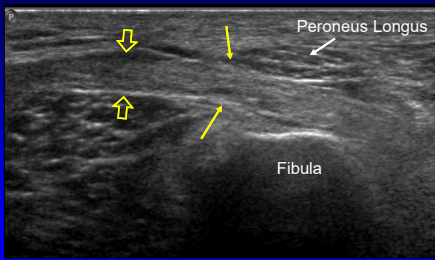
Common Peroneal Nerve

- Entrapment
 - Between fibula and peroneus longus
 - Swollen, hypoechoic nerve
- Injury:
 - Direct trauma, laceration
 - Fibular fracture



6

Common Peroneal Nerve: entrapment



Long Axis

7

Peroneal Intraneural Ganglion

- Pain: knee or peroneal nerve distribution
 - Possible palpable mass, fluctuating course
- 18% of those with foot drop¹
- No identifiable etiology
 - Weight loss, trauma, leg crossing
- High body mass index²
 - Unlike other causes for peroneal neuropathy

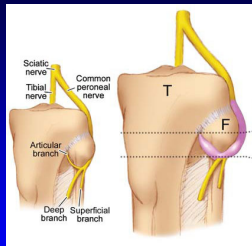
¹Visser et al. Neurology 2006; 67:1473
²Young et al. Neurology 2009; 72:447

8

Peroneal Intraneural Ganglion

- Joint fluid from proximal tibiofibular joint
 - Enters peroneal nerve via articular nerve branches
 - Shown at MR arthrography after exercise
 - Extends proximal via epineurial sheath¹

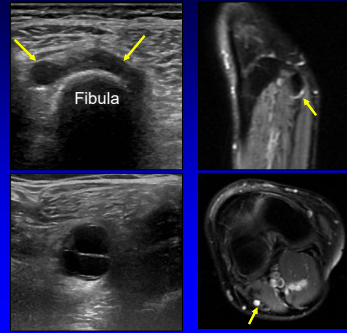
Spinner et al. Clin Anatomy 2007; 20:826



From: Spinner et al. Skeletal Radiol 2008;37:1091

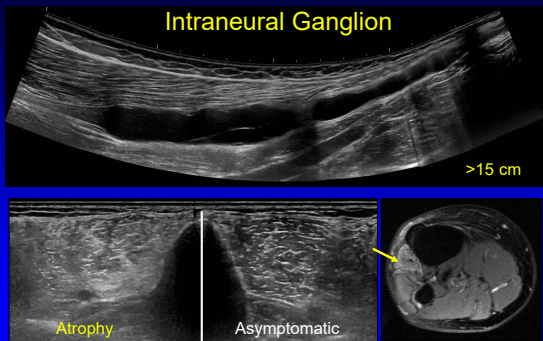
9

Peroneal Intraneural Ganglion



10

Intraneural Ganglion

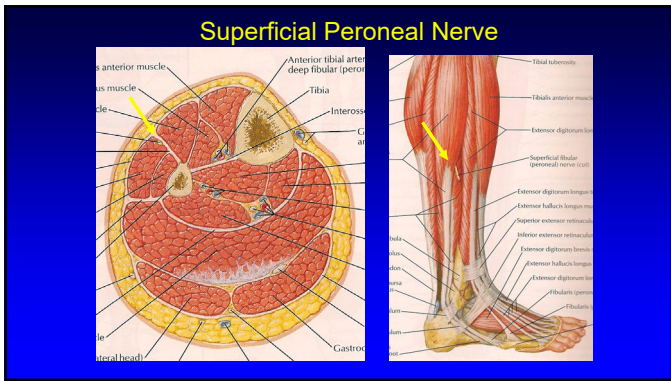


11

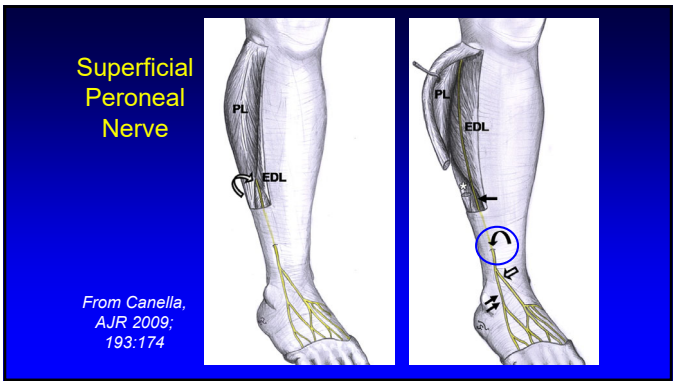
Nerve Entrapment Syndromes

- Peroneal:
 - Common peroneal
 - Superficial peroneal
- Tibial
- Interdigital (Morton neuroma)

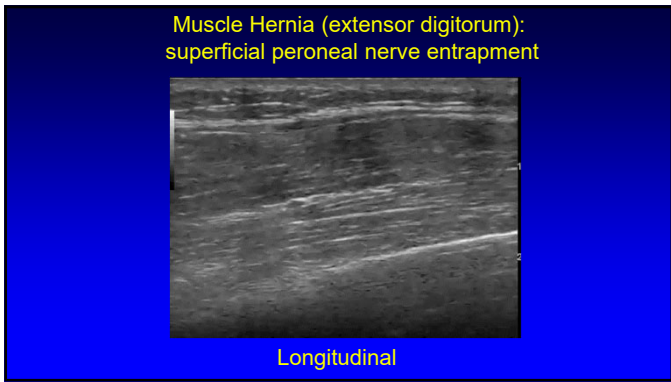
12



13



14



15

Nerve Entrapment Syndromes

- Peroneal:
 - Common peroneal
 - Superficial peroneal
- Tibial
- Interdigital (Morton neuroma)

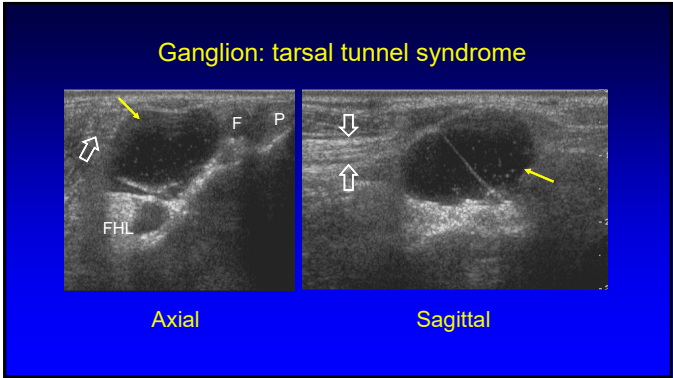
16

Tarsal Tunnel Syndrome

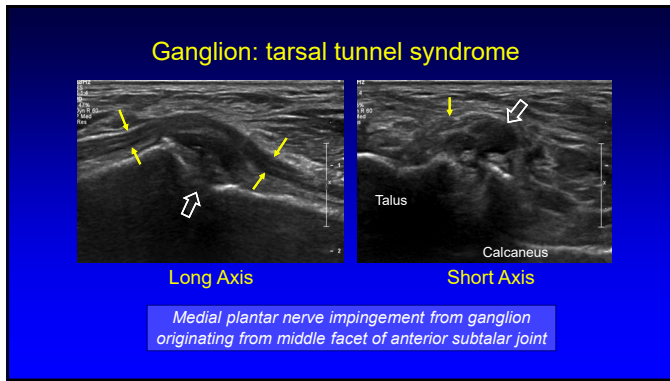
- Entrapment of tibial nerve
 - Ganglion: most common
 - Varicose veins, tenosynovitis
 - Trauma, deformity, coalition, idiopathic
- Tibial nerve:
 - May appear normal
 - May be hypoechoic and swollen

Nagaoka, J Ultrasound Med 2005;24:1035

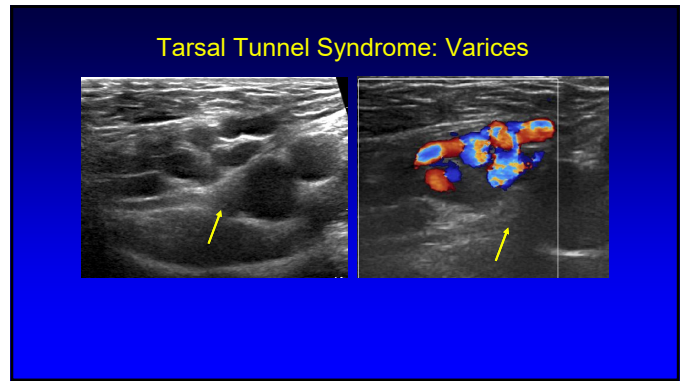
17



18



19



20

- ### Nerve Entrapment Syndromes
- Peroneal:
 - Common peroneal
 - Superficial peroneal
 - Tibial
 - Interdigital (Morton neuroma)

21

- ### Morton Neuroma:
- Interdigital nerve entrapment
 - Edema, fibrosis, necrosis
 - 3rd intermetatarsal space > 2nd
 - Sharp, burning pain from metatarsal head to toes
 - Females: pliable foot, high-heeled narrow-toed shoes
-
- From: Martinoli, RadioGraphics 2000; 20:S199

22

- ### Technique:
- Interdigital space
 - Transducer:
 - Plantar
 - Dorsal
 - Normal digital nerve difficult to visualize
 - Correlate with symptoms
-

23

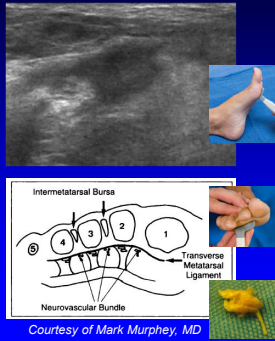
- ### Morton Neuroma
- Hypoechoic 5 mm mass
 - Sensitivity: 100% ; Specificity: 83%
 - Digital nerve continuity*
 - Excludes other causes for mass
 - Compression:
 - Produces symptoms
 - Bursa (compressible) vs. neuroma (not compressible)
-
- Redd et al. Radiology 1989; 171:415
Quinn et al. AJR 2000; 174:1723

24

Dynamic Evaluation

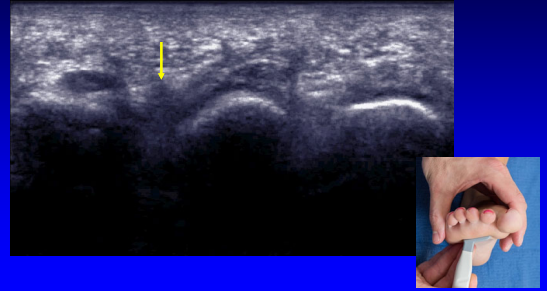
- Compression
 - Between transducer and palpation
 - Bursae (dorsal) compress, neuromas (plantar) do not
- Sonographic Mulder Sign
 - Scan plantar: coronal plane
 - Neuroma displaces: plantar
 - Palpable click

Torriani M et al. AJR 2003; 180:1121
Zanetti M et al. Radiology 1997; 203:516



25

Dynamic imaging: Mulder's Maneuver



26

Take-home Points

- Nerve evaluation: short axis
- Entrapment:
 - Characteristic locations
 - Hypoechoic, enlarged proximal
- Muscle denervation: hyperechoic
- Dynamic evaluation:
 - Morton neuroma

27

Thank you!



Syllabus on line and other educational material:
www.jacobsonmuskus.com

Twitter handle: @jjacobsn

28