

Ultrasound Evaluation of Ankle and Foot Pathology

Jon A. Jacobson, MD FACR
FSRU, FAIUM, RMSK

Professor of Radiology
Lenox Hill Radiology, NYC
University of California, San Diego

1

Disclosures

- Consultant: Bioclinica
- Advisor: Philips
- Book Royalties: Elsevier
- Not relevant to this lecture

*Note: all images from the textbook
Fundamentals of Musculoskeletal Ultrasound are
copyrighted by Elsevier Inc.*

See www.jacobsonmskus.com for syllabus other educational material

2

Outline:

- Tendon Pathology
- Ligament Pathology
- Inflammation
- Masses

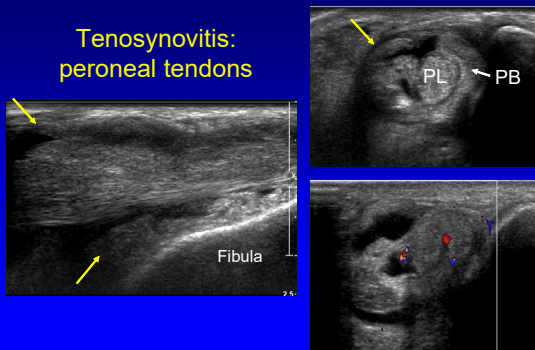
3

Tenosynovitis: US

- Fluid distending tendon sheath
 - Anechoic or hypoechoic
 - May be heterogeneous, complex
- Synovial proliferation:
 - Hypoechoic
 - May be isoechoic to tendon
 - Variable flow on color Doppler imaging

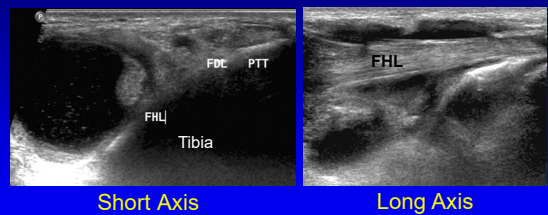
4

Tenosynovitis: peroneal tendons

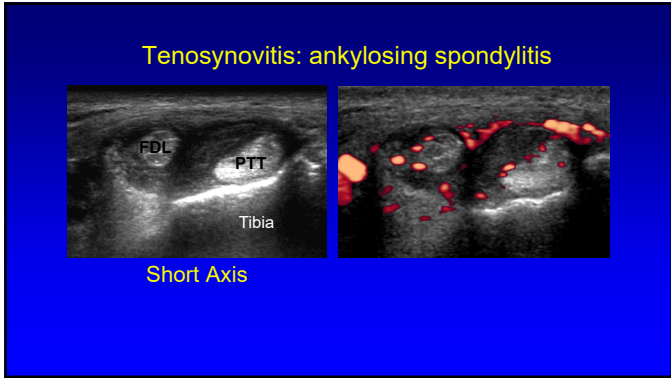


5

Tenosynovitis: flexor hallucis longus



6

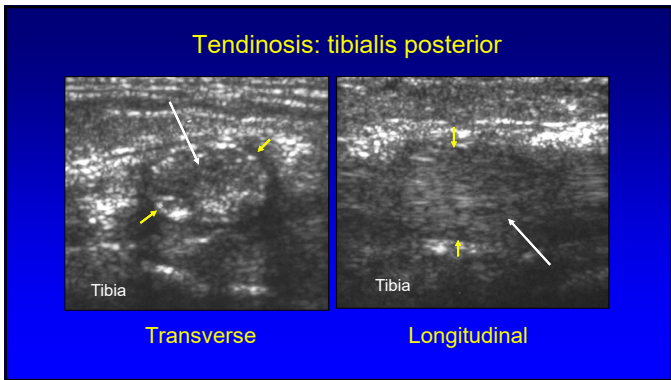


7

Tendinosis

- Tendon degeneration
- Not tendinitis: no acute inflammation
- Swollen, hypoechoic tendon
- Unlike tear:
 - Tendon fibers still continuous
 - No defined clefts

8



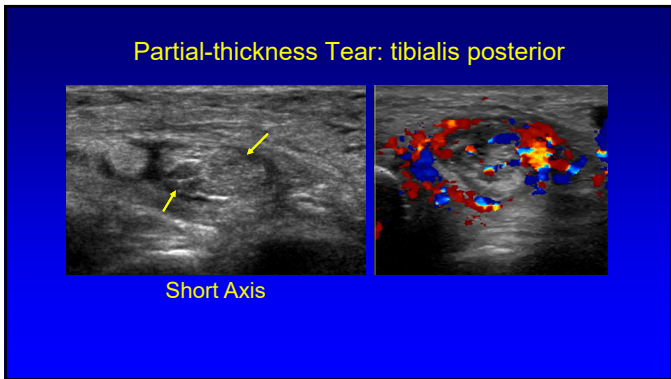
9

Partial Tear

- Anechoic / hypoechoic clefts
- Surface irregularity
- Longitudinal split
- Possible tenosynovitis
- Specific locations:
 - Where tendons curve around bone
 - Achilles: 2 - 6 cm proximal to calcaneus

FDL PTT Tibia Tibia

10

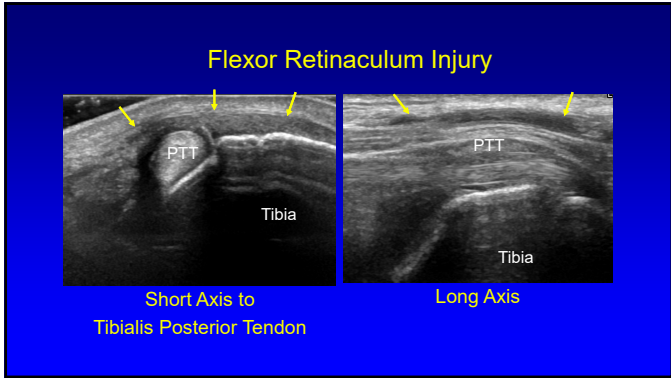


11

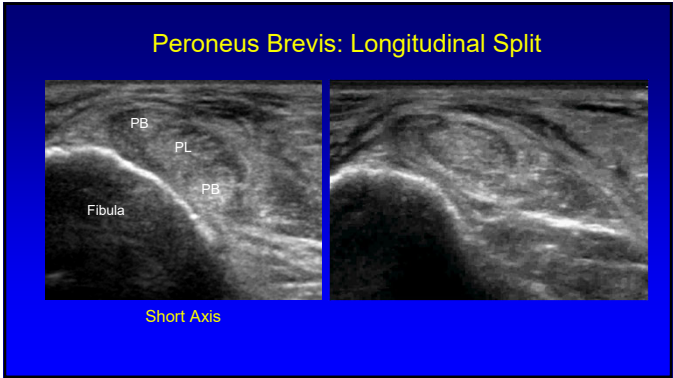
Full-thickness Tear

- Complete disruption of tendon fibers
- Hypoechoic or anechoic
- Transverse:
 - Absent tendon fibers
- Long axis imaging:
 - Tendon retraction (dynamic imaging)

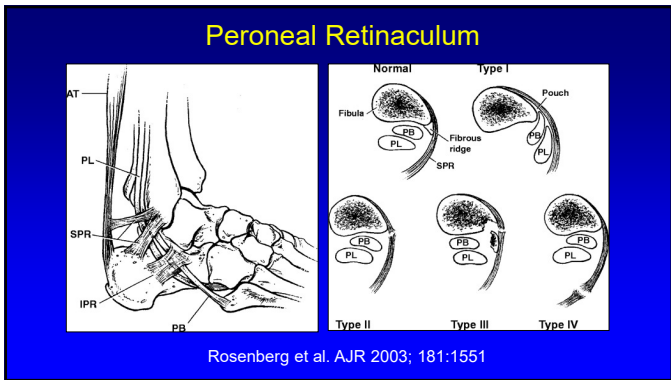
12



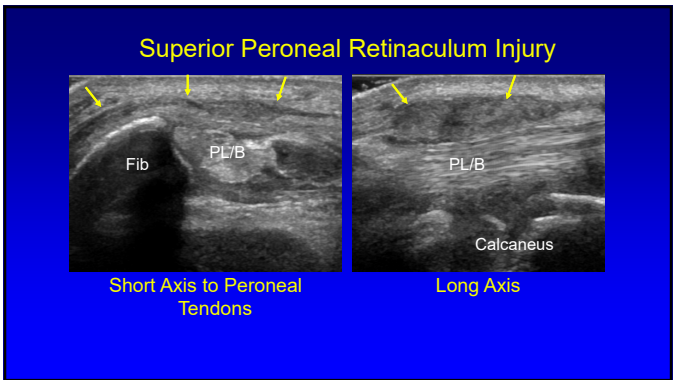
13



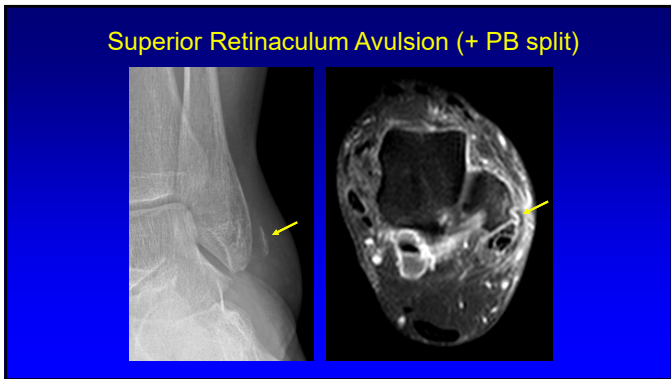
14



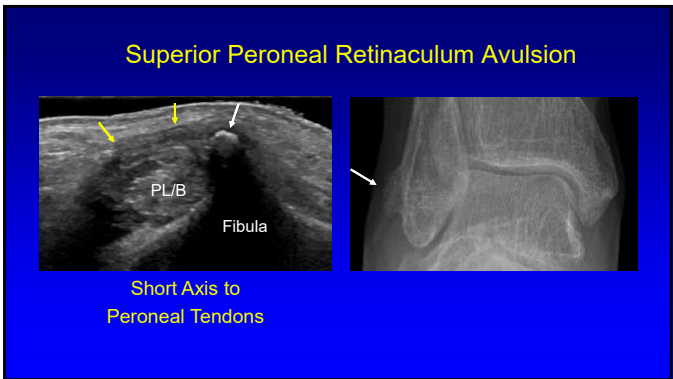
15



16



17



18

Peroneal Tendon: *dynamic imaging*

Subluxation: Type 1 pouch Dislocation and tendon tear

19

Intrasheath Peroneal Subluxation

- Abnormal snapping: peroneal tendons
- No lateral displacement, intact retinaculum
- Type A: no tear; B: tendon tear
- Associations:
 - Convex posterior fibula in 92%
 - Tendon tear in 86%
 - Low lying peroneus brevis muscle in 71%

J Bone Joint Surg Am 2008; 90:992
J Foot Ankle Surg 2009; 48:323

20

Os Peroneum Fracture:

- Interval fragmentation or fracture
- Contraction + compression on cuboid
- Separation: > 6 mm (unlike bipartite)
- Associated: peroneus longus tear

Kalume-Brigido et al. 2007; Radiology 2005; 237:235.

21

Os Peroneum Fracture

Sagittal T2w

22

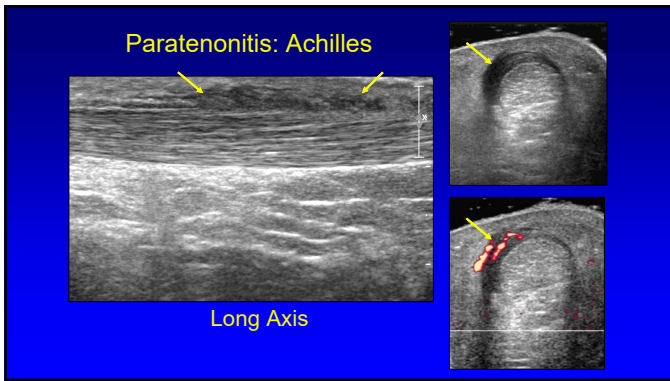
Avulsion: peroneus brevis / aponeurosis

23

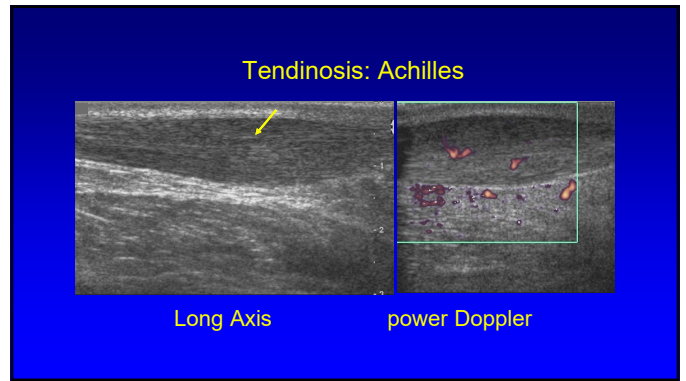
Achilles Tendon:

- 2 – 6 cm proximal to insertion
 - Tendinosis
 - Full-thickness tear
- Calcaneal attachment
 - Tendinosis, tear
 - Haglund Syndrome

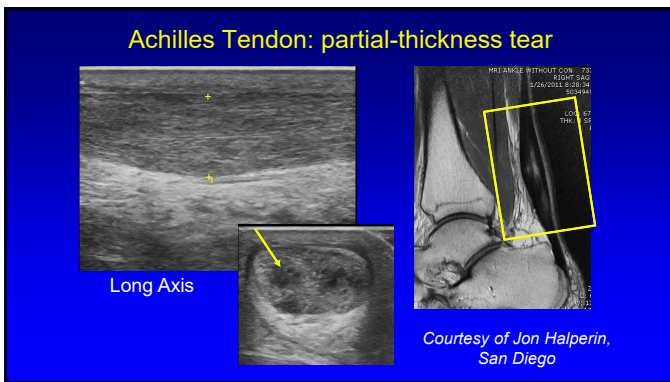
24



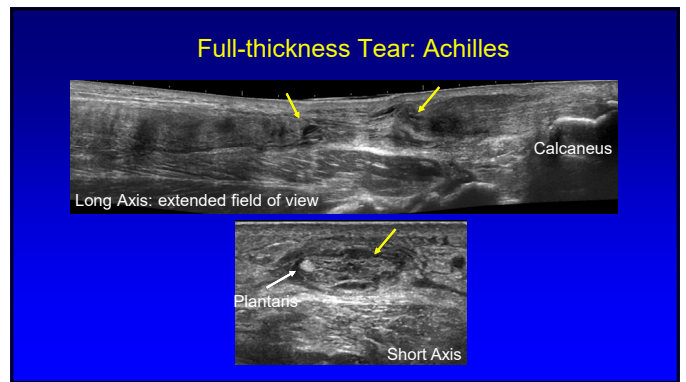
25



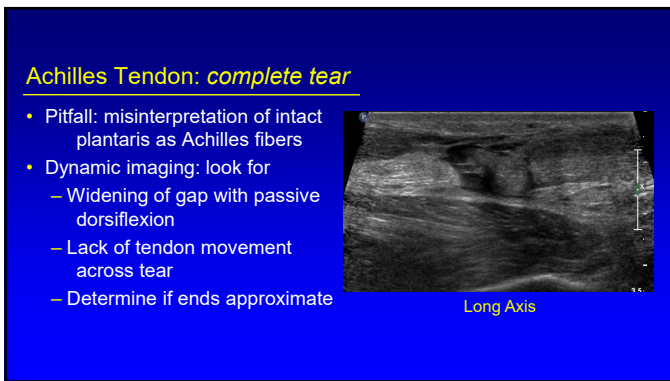26



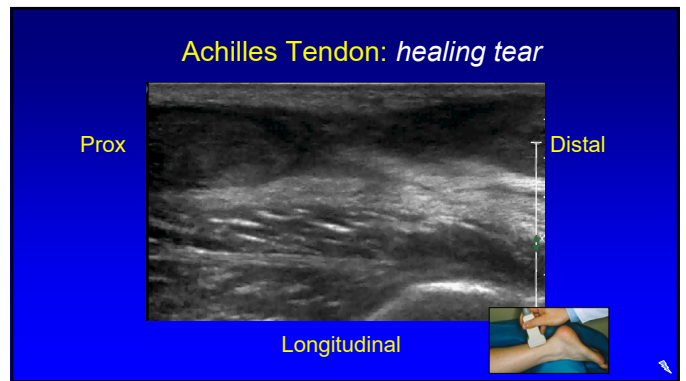27



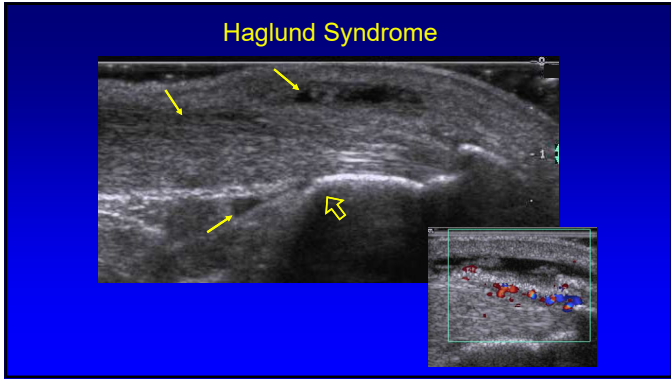
28



29



30



31

Plantar Fascia

- Fasciopathy
 - Central cord, proximal
 - Degenerative, tendinosis-like, tear
- US:
 - Hypoechoic, thickened > 4 mm
 - Painful with transducer pressure

Cardinal, E. et al. Radiology 1996; 201:257

32

Outline:

- Tendon Pathology
- Ligament Pathology
- Inflammation
- Masses

33

Technique: lateral

- Anterior talofibular
- Calcaneofibular
- Posterior talofibular
- Anterior tibiofibular
- Posterior tibiofibular

From: Netter's Atlas of Human Anatomy

34

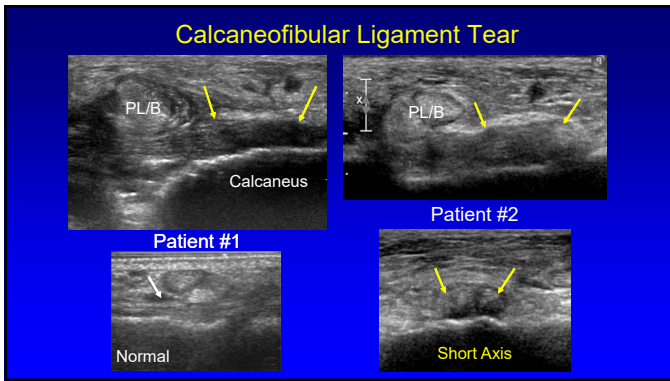
Ligament Tear:

- Hypoechoic & thickened
- Acute: anechoic fluid tracking through defect indicates full-thickness tear
- Cortical avulsion: hyperechoic

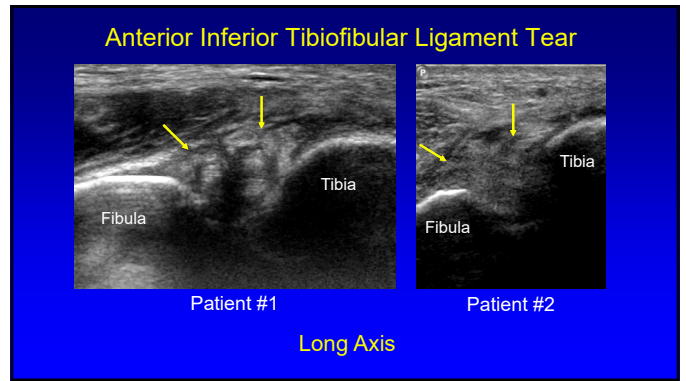
35

Anterior Talofibular Ligament Tear

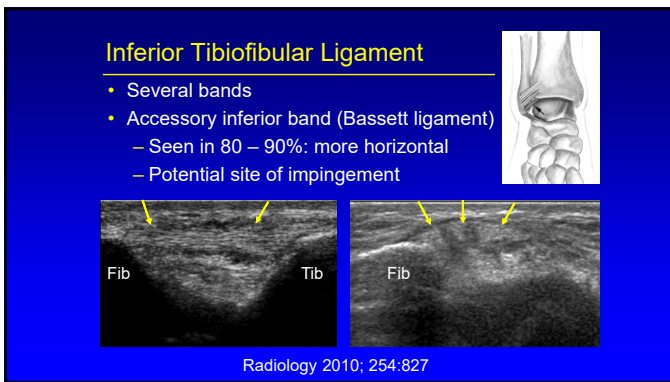
36



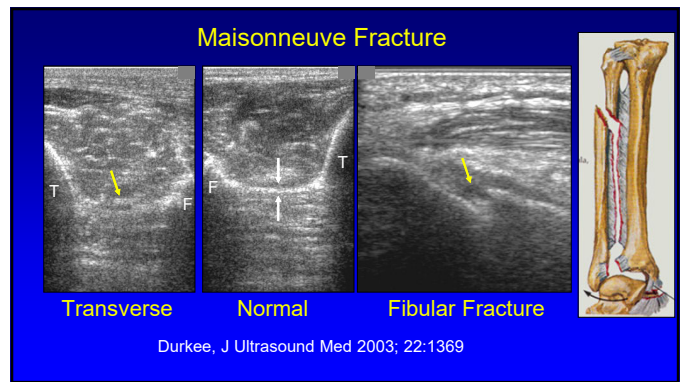
37



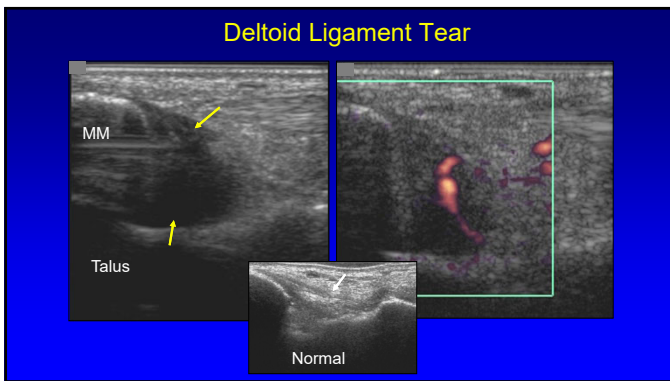
38



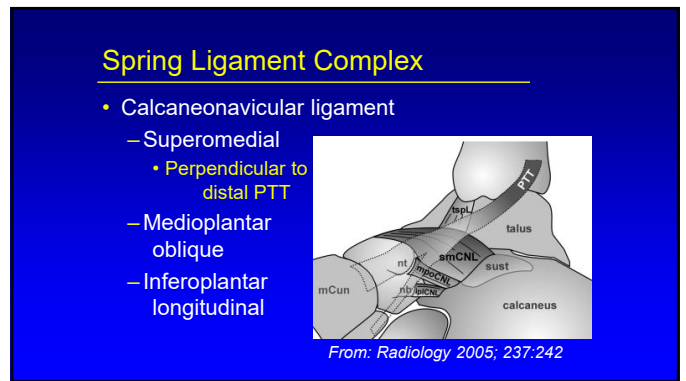
39



40



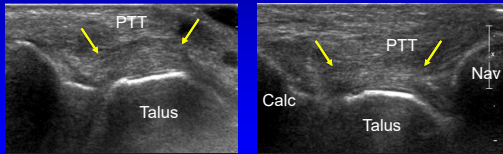
41



42

Spring Ligament Complex:

- Superomedial component
- Normal: hyperechoic, 2.8 – 3.4 mm thick

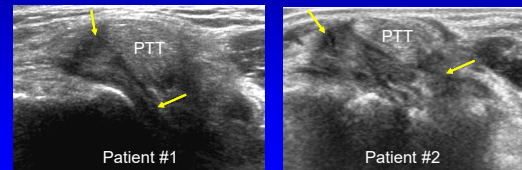


Harish, Skeletal Radiol 2007; 36:221

43

Superomedial Calcaneonavicular Ligament

- Associated with PTT dysfunction
- Abnormal: hypoechoic, thick > 4 mm, thinned or disrupted



Harish, J Ultrasound Med 2008; 27:1145

44

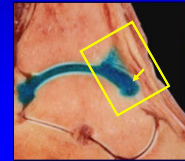
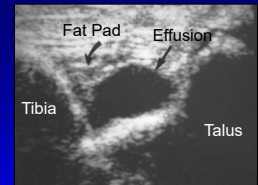
Outline:

- Tendon Pathology
- Ligament Pathology
- Inflammation
- Masses

45

Tibiotalar Joint: *effusion*

- Anterior evaluation most sensitive
- Plantar flexion
- Hyperechoic fat pad displaced by anechoic or hypoechoic fluid
- Sensitivity: MRI > US > PF



Jacobson, JA et al. AJR 1998; 170:1231

46

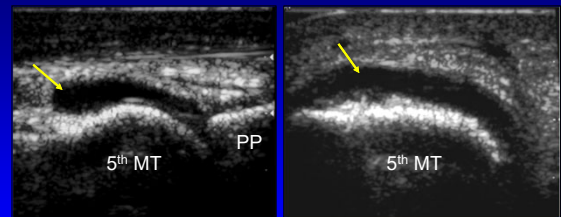
Septic Joint:

- Anechoic or hypoechoic distention of joint recesses
- May be hyperechoic if complicated
 - Possible synovitis
- US or color Doppler cannot distinguish between septic and aseptic effusion*

*Strouse et al. Radiology 1998; 206:731

47

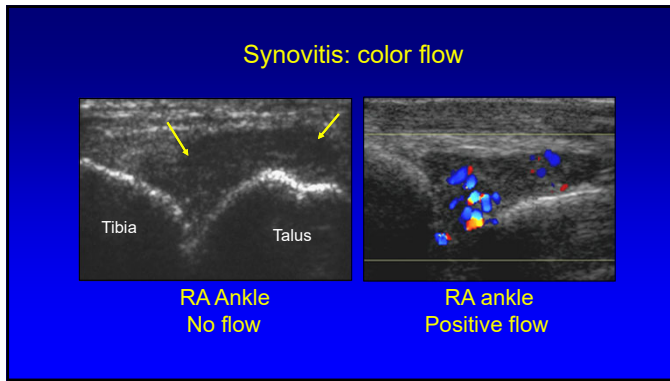
5th Metatarsal Phalangeal Joint: septic



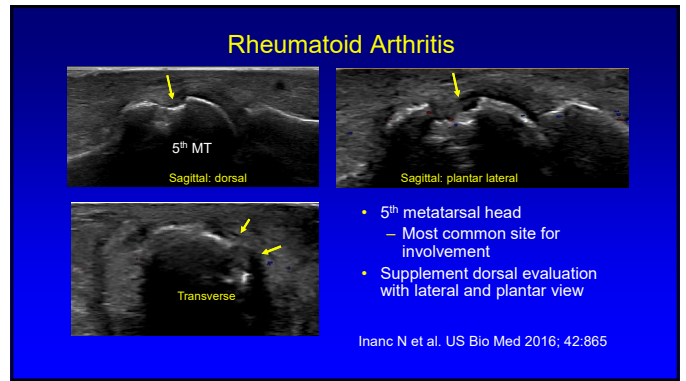
Sagittal

Coronal

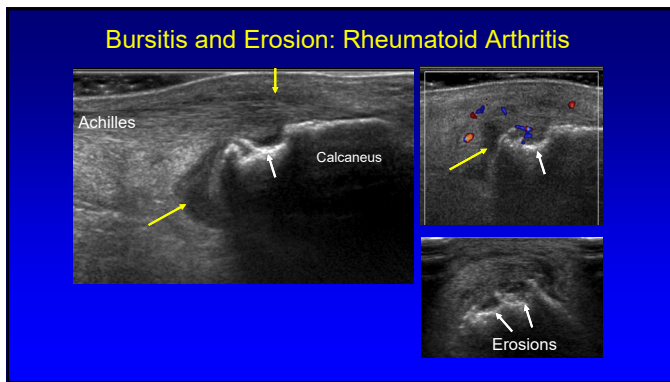
48



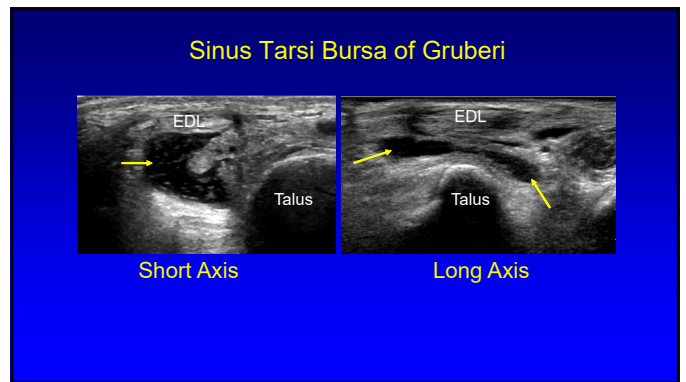
49



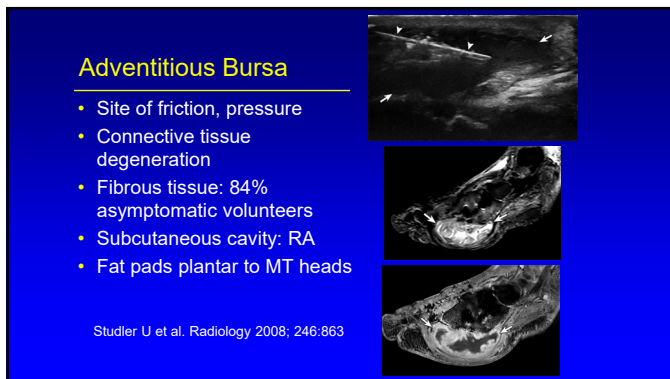
50



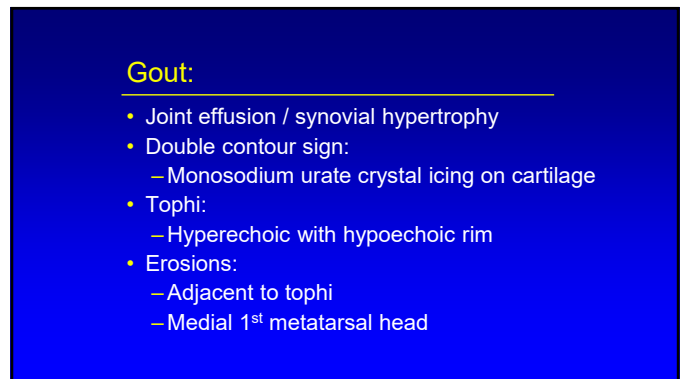
51



52



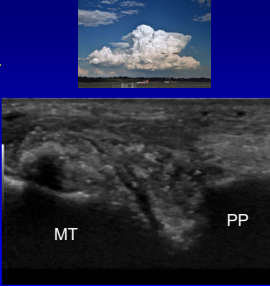
53



54

Tophi

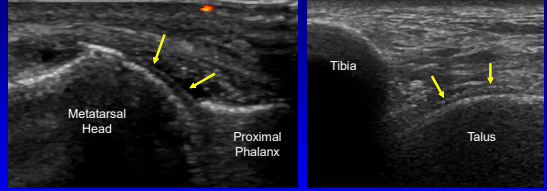
- Hyperechoic heterogeneous with hypoechoic rim
- Tiny internal speckles*
- "wet clump of sugar" appearance
- Variable shadowing: even without calcification



Fernandes et al. Skeletal Radiol 2011; 40:309

55

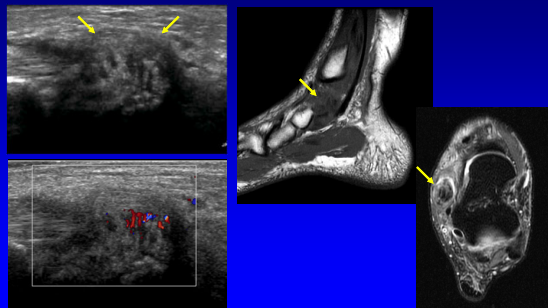
Gout: Double Contour Sign



1st MTP Joint Ankle Joint

56

Gout: tibialis posterior tendon



57

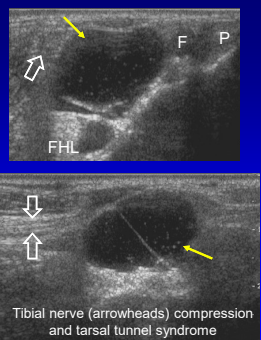
Outline:

- Tendon Pathology
- Ligament Pathology
- Inflammation
- Masses

58

Soft Tissue Ganglion

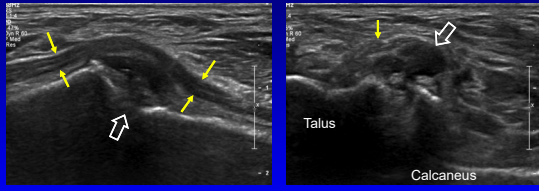
- Hypoechoic or anechoic
- Multilocular
- Non-compressible
- Possible increased through-transmission
- Joint or tendon sheath communication



Ortega et al. AJR 2002; 178:1445

59

Ganglion: tarsal tunnel syndrome



Long Axis Short Axis

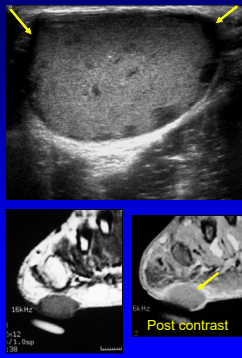
Medial plantar nerve impingement from ganglion cyst originating from middle facet of anterior subtalar joint

60

Epidermal Inclusion Cyst

- Etiology: implantation of epithelium, congenital, squamous metaplasia, hair follicle obstruction
- US findings:
 - Low level echoes and hypoechoic halo
 - Through transmission
 - **Hypoechoic clefts**
 - Periscope sign: extension to skin

Kim et al. Skeletal Radiol 2011; 40:1415

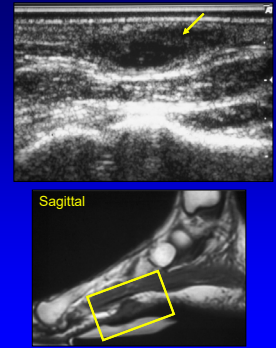


61

Plantar Fibromatosis

- Benign fibrous proliferation
- Multiple: 33%, bilateral: 20 – 50%
- Hypoechoic mass or masses
- Plantar aponeurosis
- Variable vascularity

Griffith JF et al. AJR 2002; 179:1167



62

Take Home Points

- Tendons:
 - Tenosynovitis, tendinosis, partial tear, longitudinal split, complete tear
- If concern for infection: aspirate
- Gout: specific findings
- **Dynamic imaging**
 - Peroneal subluxation
 - Achilles tear

63


Thank you!



NYC



Ann Arbor



San Diego

Syllabus on line and other educational material:
www.jacobsonmskus.com



64