

Ultrasound Evaluation of the Forefoot

Jon A. Jacobson, MD FACR

Professor of Radiology
Lenox Hill Radiology, NYC
University of San Diego, California



Syllabus

1

Disclosures

- Consultant: Bioclinica
- Book Royalties: Elsevier
- Not relevant to this lecture

2

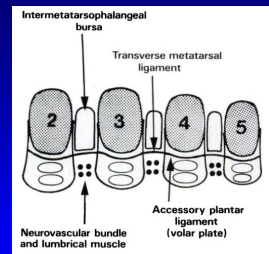
Outline

- Interdigital neuroma
- Plantar plate
- Fracture
- Infection and Inflammation
- Tumors and Tumor-like Abnormalities

3

Anatomy

- At level of metatarsal heads:
 - Transverse metatarsal ligament
 - Attaches to plantar plates
 - Intermetatarsal bursa: dorsal
 - Neurovascular bundle: plantar



Zanetti M et al. Radiology 2014; 203:516

4

Interdigital Neuroma

- Common plantar digital nerve entrapment
- Edema, fibrosis, necrosis
- 3rd intermetatarsal space > 2nd
- Sharp, burning pain to toes
- Females: pliable foot, high-heeled, narrow-toed shoes
- Asymptomatic neuromas in up to 33%
- Neuromas < 5 mm mediolateral: **often asymptomatic**



Zanetti M et al. Radiology 1997; 203:516

5

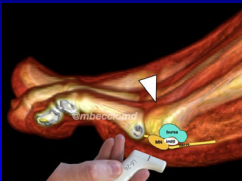
Neuromas: eponyms

- Medial to first metatarsal: Joplin
- 1st webspace: Heuter
- 2nd webspace: Hauser
- 3rd webspace: **Morton**
- 4th webspace: Iselin

6

Interdigital Neuroma

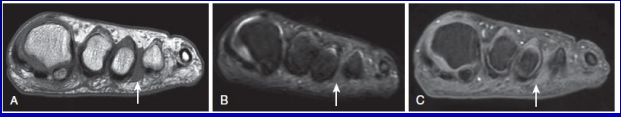

- Pathophysiology:
 - Neuroma forms where common plantar digital nerve passes distal around transverse metatarsal ligament at distal metatarsal heads
 - Note: intermetatarsal bursa is more dorsal and more proximal at level of transverse metatarsal ligament



From: youtube @mbecciomd

7

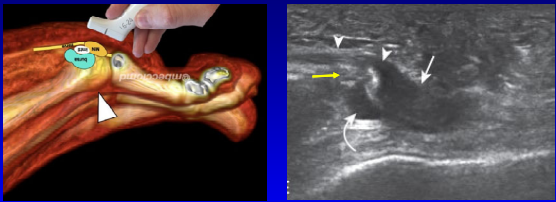
Interdigital Neuroma

Note: location of neuroma located plantar extending beyond metatarsal heads

8

Interdigital Neuroma




Note: neuroma is at distal edge of transverse metatarsal ligament
 White arrow: neuroma
 Arrowheads: common plantar digital nerve
 Curved arrow: intermetatarsal bursa
 Yellow arrow: transverse metatarsal ligament

9

Ultrasound Evaluation

- #1: plantar, short axis
 - With dorsal compression
- #2: plantar, long axis
 - With dorsal compression
- #3: Mulder maneuver
 - With side-to-side compression

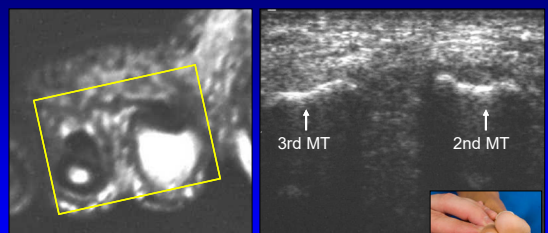


*Neuroma of 5 mm or larger: 100% sensitivity, 83% specificity

Redd et al. Radiology 1989; 171:415
 Quinn et al. AJR 2000; 174:1723

10

Interdigital Space: normal

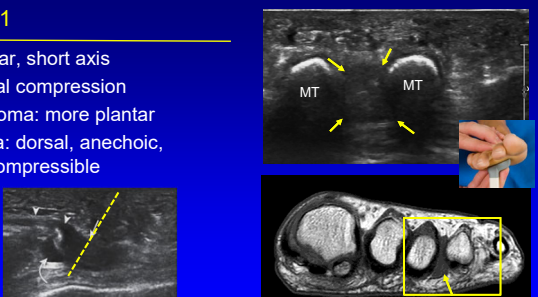


Short Axis to Metatarsals

11

Step #1

- Plantar, short axis
- Dorsal compression
- Neuroma: more plantar
- Bursa: dorsal, anechoic, compressible



Note: coronal-oblique plane moving distal to metatarsal heads

12

Step #2

- Plantar, long axis
 - Follow MT head curvature
- Dorsal compression
 - Move finger distal, proximal
 - See neuroma sliding over transverse metatarsal ligament
- Neuroma: plantar, distal
- Bursa: curved arrow
 - Dorsal, proximal
 - Anechoic, compressible

MRI flipped upside down to simulate US

13

Neuroma: nerve continuity (white open arrow)

Proximal Distal

Transverse metatarsal ligament

Bursa

Long Axis

Courtesy of Mark Murphey, MD

14

Step #3: Mulder's maneuver

- Transducer: plantar, short axis
- Squeeze foot side-to-side
- Neuroma moves plantar
 - Palpable click, elicits symptoms
 - Important to document
 - Improved accuracy, measurements
- Make sure to perform distal to intermetatarsal ligament
- Bursa: remains dorsal

Torriani M et al. AJR 2003; 180:1121

15

Dynamic: Interdigital Neuroma + Bursa

Dorsal Mulder's Maneuver

16

Differential Diagnosis

- Pericapsular fibrosis
- Associated with capsule injury
- Hypoechoic
- Eccentric
- Not truly intermetatarsal
- Negative Mulder's maneuver

Umans H et al. Skeletal Radiol 2014

17

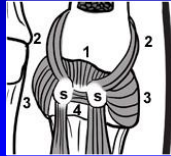
Outline

- Interdigital neuroma
- Plantar plate
- Fracture
- Infection and Inflammation
- Tumors and Tumor-like Abnormalities

18

1st MTP joint: Capsuloligamentous Complex

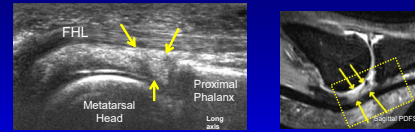
- Fibrocartilaginous pad (not a plantar plate): #1
- Sesamoid phalangeal ligaments: #2
- Metatarsosesamoid ligaments: #3
- Intersesamoid ligament: #4
- Hallux sesamoids (s)
- Collateral ligaments



Hallinan J, et al. RadioGraphics 2020; 40:1107.

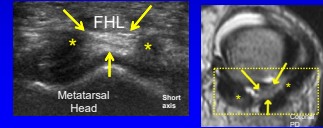
19

FHL and Fibrocartilaginous Pad: long and short axis



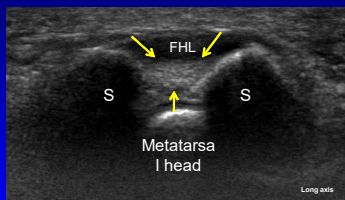
Yellow arrows = fibrocartilaginous pad

* = Sesamoid phalangeal ligaments in short axis (hypoechoic from anisotropy)

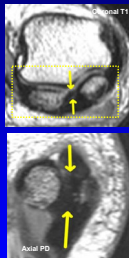


20

Intersesamoid Ligament: long axis

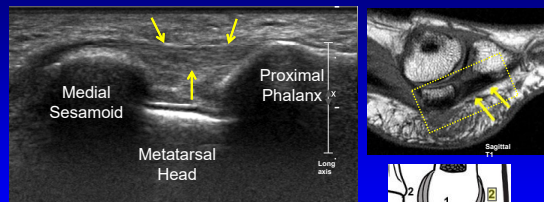


Yellow arrows = Intersesamoid ligament
Note: FHL is hypoechoic due to anisotropy
S = sesamoid bones

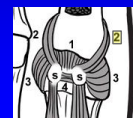


21

Sesamoid Phalangeal Ligament: long axis

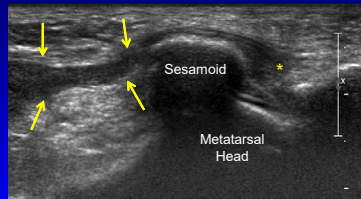


Yellow arrows = sesamoid phalangeal ligament



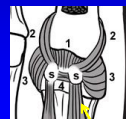
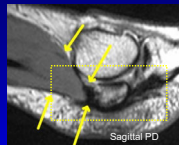
22

Medial Flexor Hallucis Brevis: Long Axis



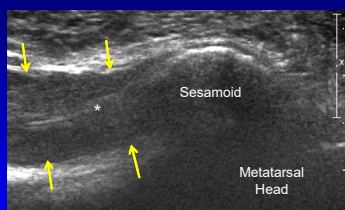
Yellow arrows = medial FHB
* = sesamoid phalangeal ligament

Origin: medial plantar cuboid and 3rd cuneiform
Insertion: medial sesamoid



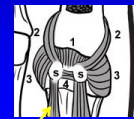
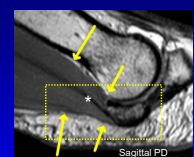
23

Lateral Flexor Hallucis Brevis: Long Axis



Yellow arrows = lateral FHB
• = echogenic central tendon

Origin: medial plantar cuboid and 3rd cuneiform
Insertion: lateral sesamoid



24

Metatarsosesamoid Ligament: Long Axis

Yellow arrows = medial metatarsosesamoid ligament
 Note: dorsally hypoechoic due to anisotropy (white arrow)

* = medial collateral ligament (short axis)
 S = medial sesamoid

25

Plantar Plate Injury

- US: hypoechoic defect
- At proximal phalanx
- Partial tear: articular surface
- Full-thickness tear: complete detachment
- May be asymptomatic finding in 47% (MTP 2 – 4)

From: Gregg JM et al. AJR 2006; 186:984
 Gregg JM et al. Eur Radiol 2006; 16:2661

26

Plantar Plate Injury and Pericapsular Fibrosis

27

Outline

- Interdigital neuroma
- Plantar plate
- Fracture
- Infection and Inflammation
- Tumors and Tumor-like Abnormalities

28

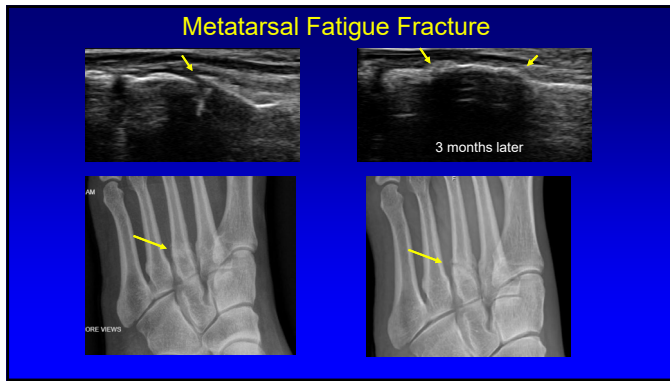
Fracture

- Stress fracture:
 - Insufficiency: normal stress, abnormal bone
 - Fatigue: abnormal stress, normal bone
- Acute fracture
- Point tenderness
- Ultrasound:
 - Periostitis and soft tissue hypoechoogenicity
 - Cortical step-off deformity
 - Irregular callus

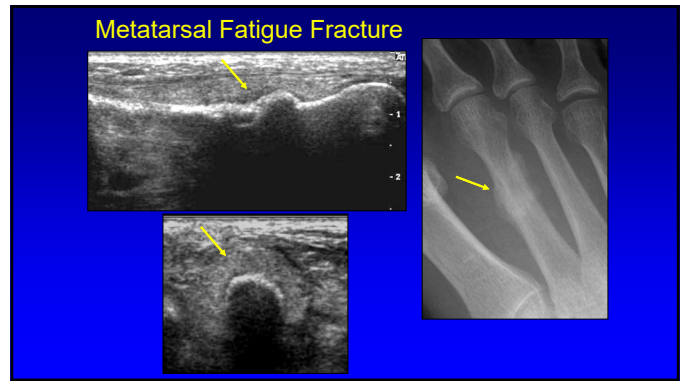
29

Metatarsal Fatigue Fracture

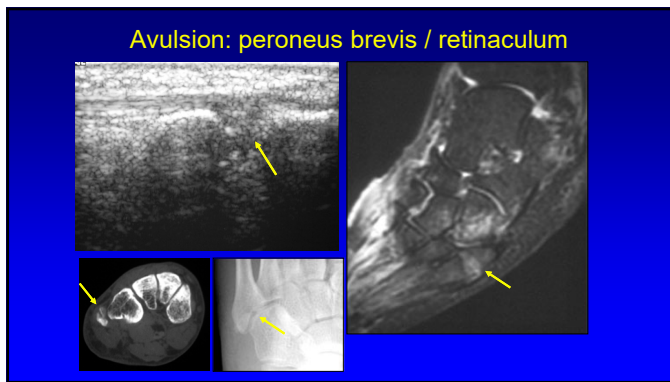
30



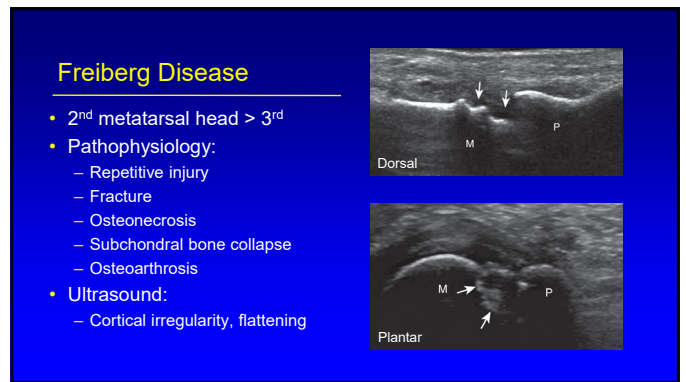
31



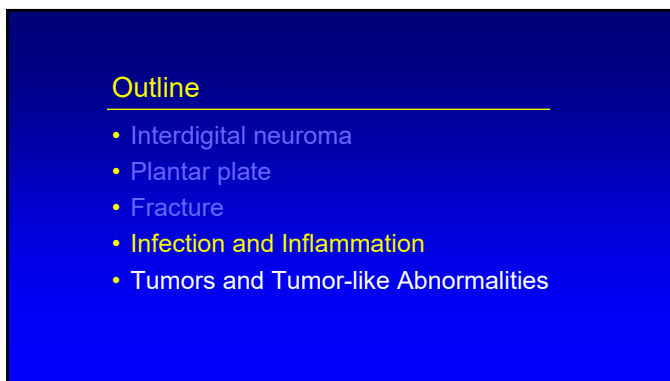
32



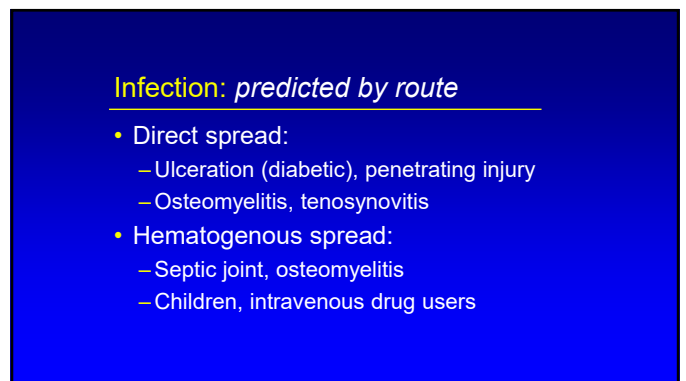
33



34



35



36

Cellulitis: acute

- Thickened and hyperechoic subcutaneous fat
- Skin erythema

Cellulitis

Normal Fat

J Ultrasound Med 2000; 19:743

37

Cellulitis: chronic

- Anechoic channels
- Distended lymphatics
- May appear similar to simple edema
- Not defined like an abscess
- Lower leg: look for popliteal cyst rupture

38

Abscess: forefoot

Sagittal T1w

Coronal post-gado

39

Septic Joint

- Anechoic or hypoechoic distention of joint recesses
- May be hyperechoic if complicated
 - Possible synovitis
- US or color Doppler cannot distinguish between septic and aseptic effusion*

*Strouse et al. Radiology 1998; 206:731

40

5th Metatarsal Phalangeal Joint: septic

5th MT PP

Sagittal

5th MT

Coronal

41

Osteomyelitis: 5th metatarsal

5th MT PP

Sagittal T1w

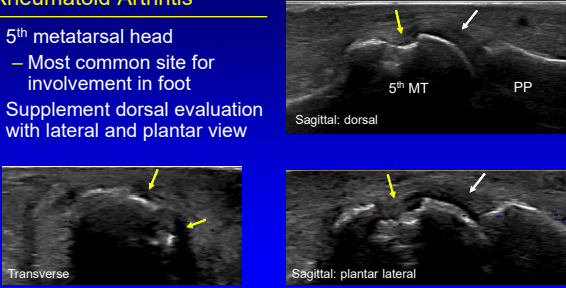
Coronal

Sagittal T2w

42

Rheumatoid Arthritis

- 5th metatarsal head
 - Most common site for involvement in foot
- Supplement dorsal evaluation with lateral and plantar view




Inanc N et al. US Bio Med 2016; 42:865

43

Gout

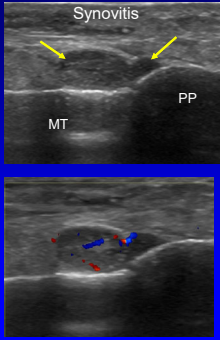
- Monosodium urate crystals:
 - Negative birefringence
- Stages:
 - Asymptomatic hyperuricemia
 - Acute gouty arthritis
 - Interval asymptomatic phase
 - Chronic tophaceous gout



44

Gout

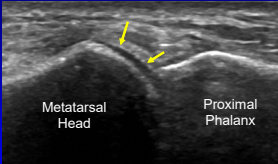
- Joint effusion / synovial hypertrophy
- Double contour sign:
 - Monosodium urate crystal icing on cartilage
- Tophi:
 - Hyperechoic with hypoechoic rim
- Erosions:
 - Adjacent to tophi
 - Medial 1st metatarsal head



45

Gout

- Double contour sign:
 - Hyperechoic foci on surface of hyaline cartilage
 - Does not demonstrate anisotropy
 - Unlike normal cartilage interface
 - Disappears with serum urate < 6 ml/dl

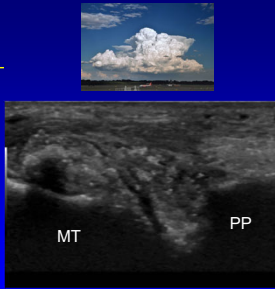


Thiele RG, Rheumatol Int 2010; 30:495

46

Tophi

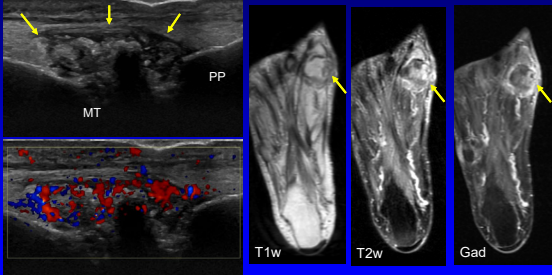
- Hyperechoic heterogeneous with hypoechoic rim
- Tiny internal speckles*
- “wet clump of sugar” appearance
- Variable shadowing: even without calcification



Fernandes et al. Skeletal Radiol 2011; 40:309

47

Gout: tophus



1st Metatarsophalangeal Joint

48

Outline

- Interdigital neuroma
- Plantar plate
- Fracture
- Infection and Inflammation
- **Tumors and Tumor-like Abnormalities**

49

Ganglion Cyst

- Multilocular
- Hypochoic
- Non-compressible
- Joint or tendon sheath communication

50

Plantar Fibromatosis

- Benign fibrous proliferation
- Multiple: 33%, bilateral: 20 – 50%
- Hypochoic mass or masses
- Plantar aponeurosis
- Variable vascularity
- "Comb" sign

Cohen BE et al. J Ultrasound Med 2018; 2725
Griffith JF et al. AJR 2002; 179:1167

51

Plantar Fibroma

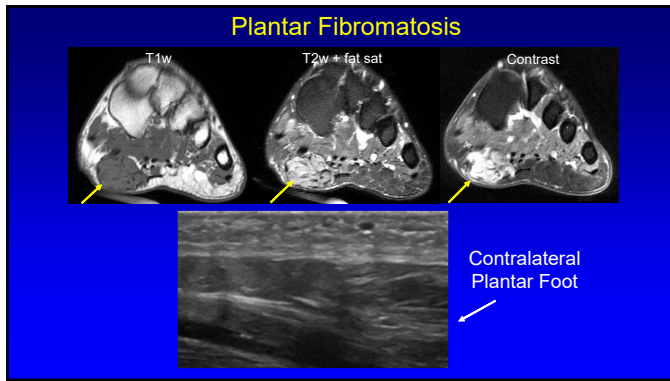
52

Plantar Fibromatosis

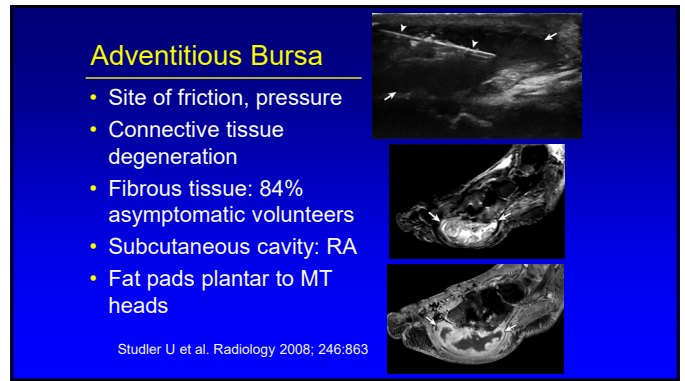
53

Plantar Fibromatosis

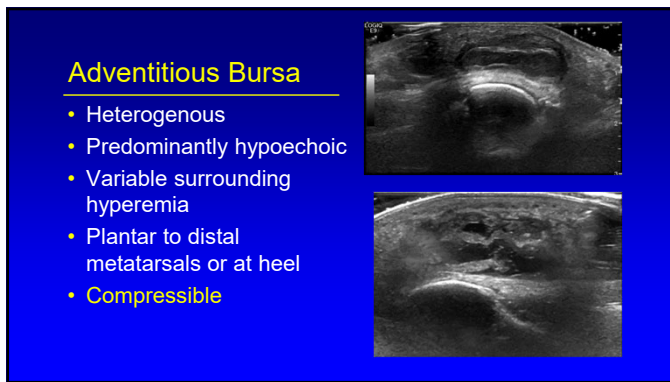
54



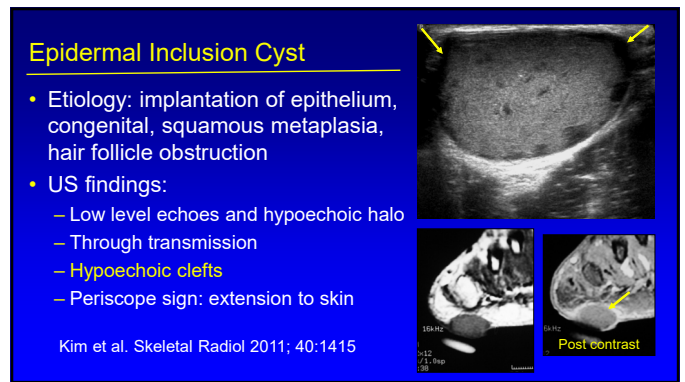
55



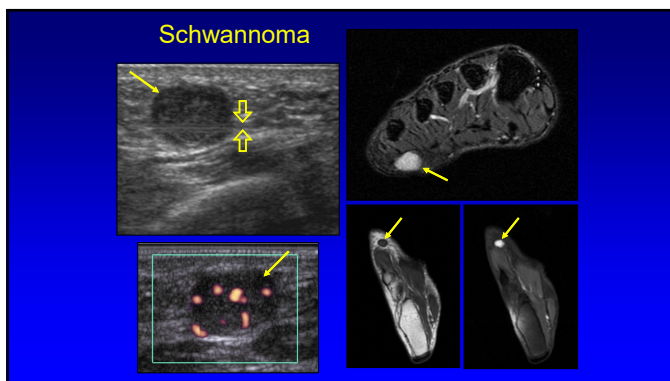
56



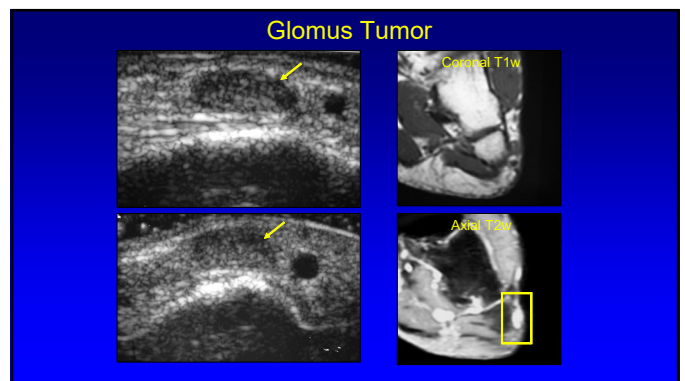
57



58



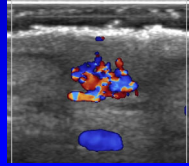
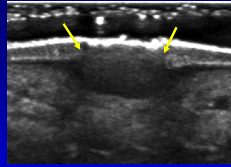
59



60

Plantar Wart

- Fusiform, hypoechoic
- Epidermis and dermis
- Inward growth: subcutaneous
- Focal intense dermal arterial flow in 77%



Wortsman X JUM 2009; 28:787

Thank you!



Syllabus on line and other educational material:
www.jacobsonmskus.com



61

62