

Trochanteric Pain Syndrome

Jon A. Jacobson, M.D.

FACR, FAIUM, FSRU, RMSK

1

Disclosures

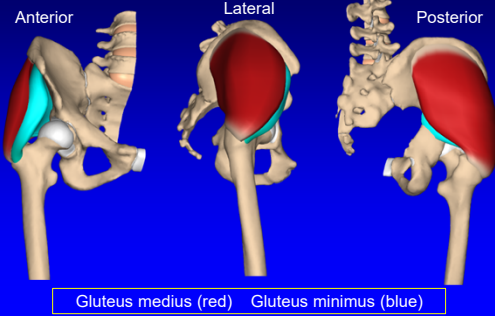
- Consultant: Bioclinica
- Contractor: POCUS PRO
- Advisory Board: Philips
- Book Royalties: Elsevier
- Not relevant to this lecture

*Note: all images from the textbook
Fundamentals of Musculoskeletal Ultrasound
are copyrighted by Elsevier Inc.*

See www.jacobsonmskus.com for syllabus other educational material

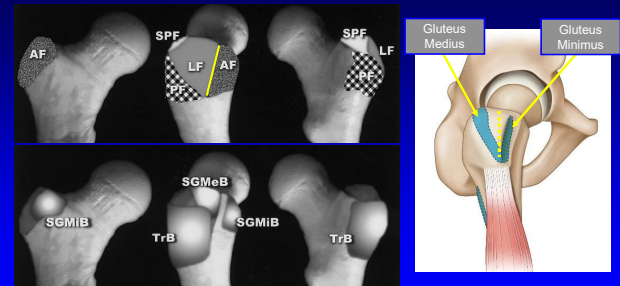
2

Greater Trochanter: gluteal tendons



3

Greater Trochanter

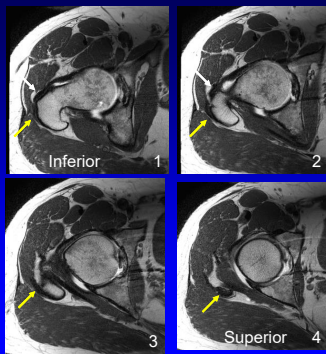


FACETS: AF = anterior; LF = lateral; SPF = superoposterior; PF = posterior
Pfirrmann et al. Radiology 2001; 221:469

4

Greater Trochanter

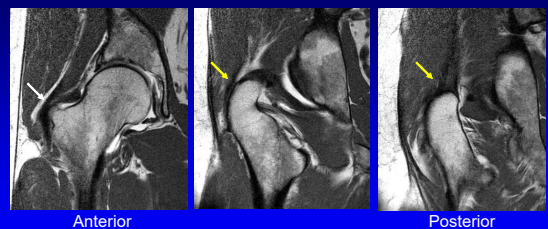
Yellow arrow =
gluteus medius
White arrow =
gluteus minimus



Axial MRI

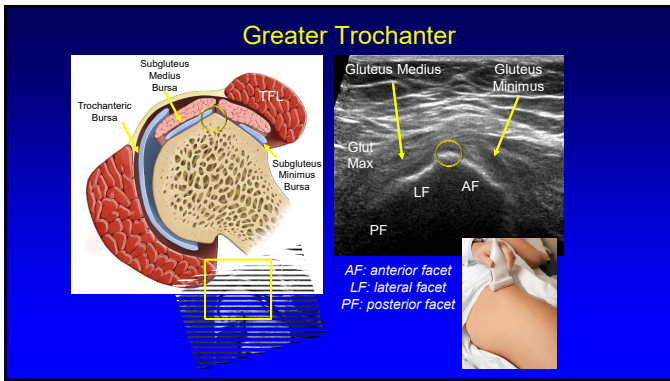
5

Greater Trochanter

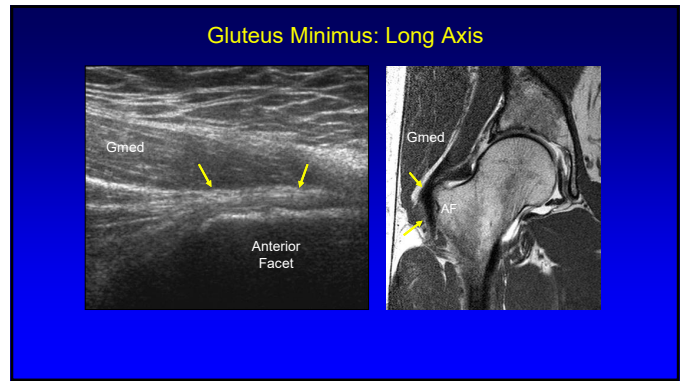


Yellow arrow = gluteus medius
White arrow = gluteus minimus

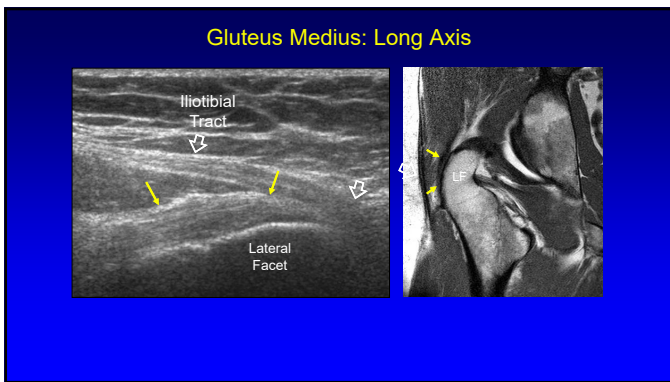
6



7



8



9

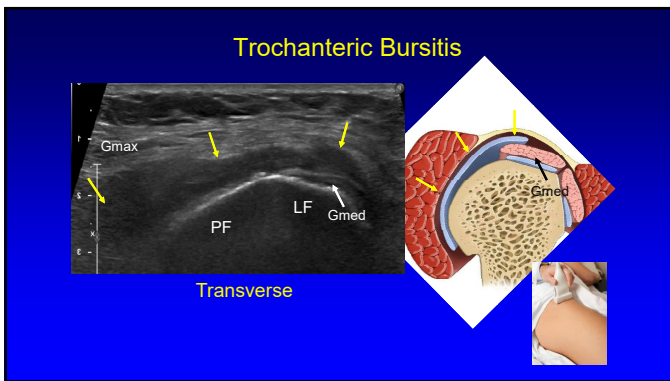
Trochanteric Pain Syndrome:

- Most commonly caused by gluteus minimus and medius tendon abnormalities¹
- Trochanteric bursitis: uncommon
 - 20% of symptomatic patients²
 - Not actually inflamed³
 - Not associated with pain⁴

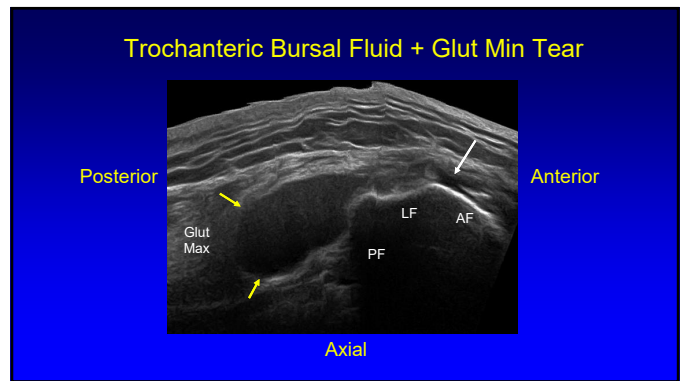
IT'S NOT BURISITIS

¹Kong A et al. Eur Rad 2007; 17:1772
²Long SS et al. AJR 2013; 201:1083
³Sylva F et al. Clin Rheumatol 2008; 14:82
⁴Blankenbaker DG et al. Skeletal Radiol 2008; 37:903

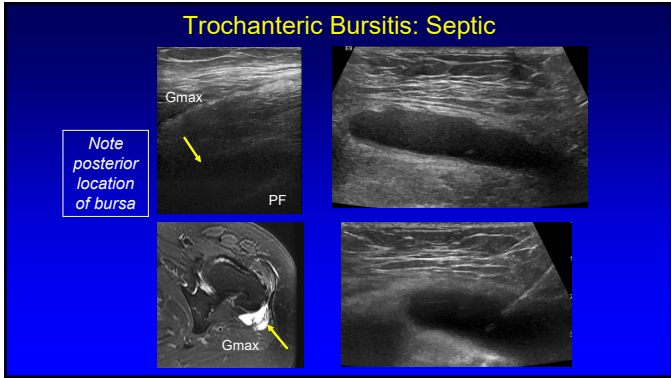
10



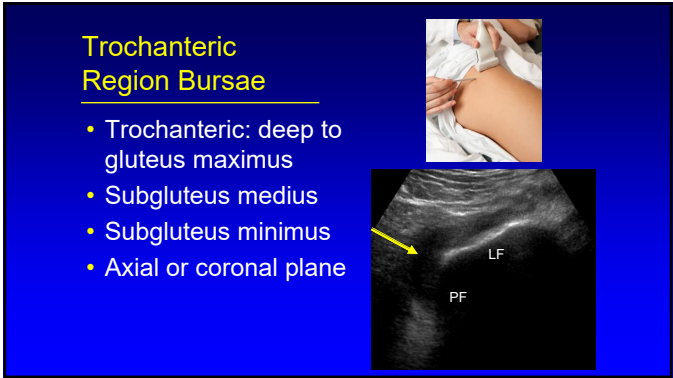
11



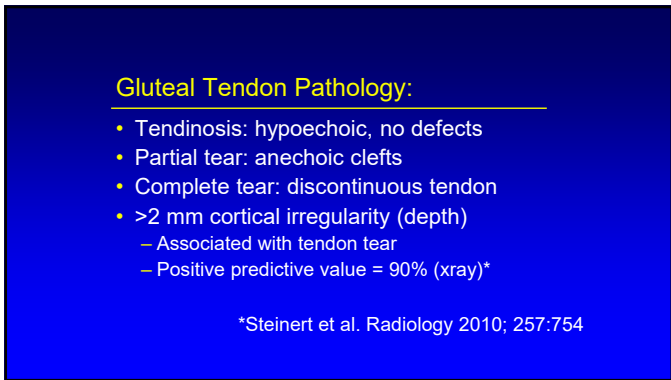
12



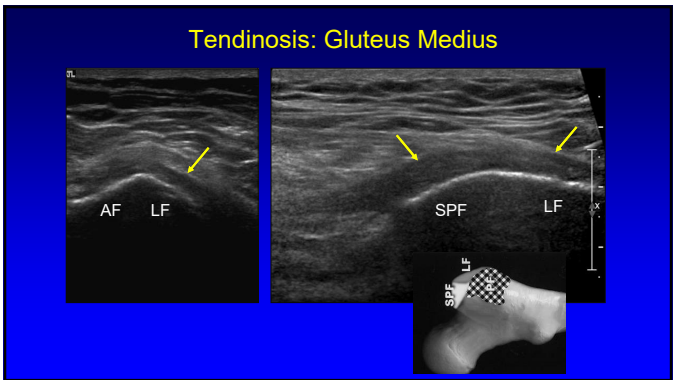
13



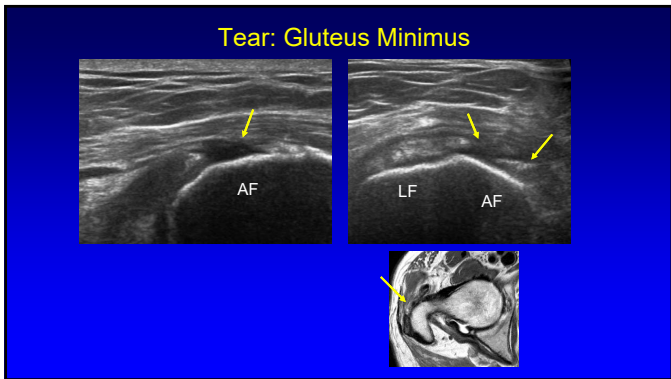
14



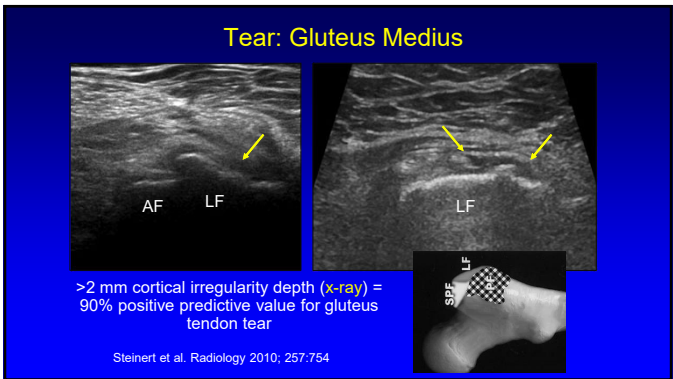
15



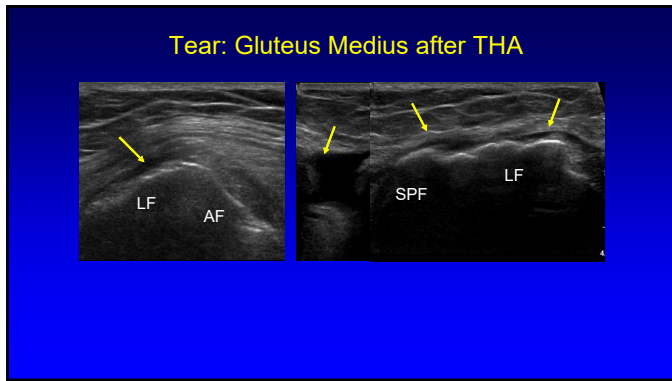
16



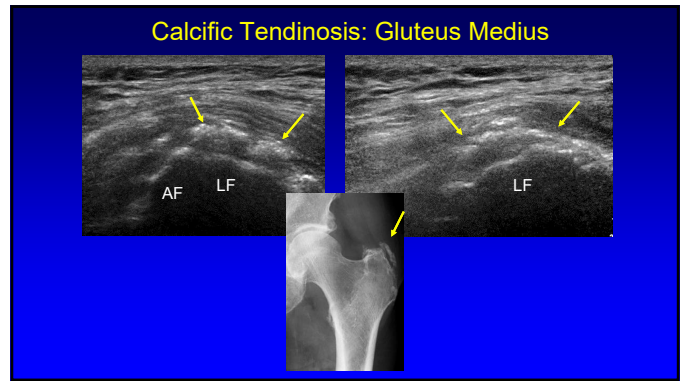
17



18



19



20

Potential Treatment Algorithm:

- If bursa: aspirate, inject steroids
- If tendinosis:
 - Inject steroids superficial to tendon
 - 72% of patients significantly improved (short term)¹
 - Tenotomy or fenestration
- If tendon tear: platelet-rich plasma injection?

¹Labrosse, et al. 2010 AJR 2010; 194:202

21

Snapping Hip: lateral

- Transverse over greater trochanter
- Hip external rotation / flexion
- Abrupt motion of iliotibial tract or gluteus maximus over greater trochanter

22

Snapping Gluteus Maximus / Iliotibial Band

23

Snapping Hip Syndrome: iliotibial tract

24

Take-home points:

- Trochanteric anatomy
- Bursitis: rare
- Gluteal tendons abnormalities: frequent
- Snapping hip: dynamic

25

Thank you!

Syllabus on line and other educational material:
www.jacobsonmskus.com

Twitter handle: @jjacobsn

26