

Hip Anatomy and Ultrasound Scanning Technique

Jon A. Jacobson, MD FACR

Professor of Radiology
Section Chief, Musculoskeletal Imaging



1

Disclosures

- Consultant: Bioclinica
- Book Royalties: Elsevier
- Contractor: POCUS PRO
- Advisory Board: Philips
- Not relevant to this talk

Syllabus and other educational material can be found at www.jacobsonmskus.com

Note: all images from the textbook *Fundamentals of Musculoskeletal Ultrasound* are copyrighted by Elsevier Inc.

2

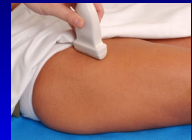Sonographic Technique: *hip and thigh*

- Hip:
 - Anterior: hip joint, musculature, iliopsoas bursa
 - Lateral: gluteal tendons, bursae
 - Posterior: external rotators
 - Other: symphysis pubis, inguinal hernia
- Thigh:
 - Anterior: quadriceps femoris
 - Medial: abductors
 - Posterior: hamstring

3

Sonographic Technique: Hip

- **Anterior**
 - Hip joint
 - Anterior musculature
 - Snapping iliopsoas
 - Iliopsoas bursa
 - Lateral femoral cutaneous nerve
- Transducers:
 - 10 – 12 MHz linear
 - <10 MHz curvilinear if needed

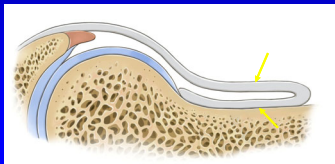


4

Hip: anterior recess

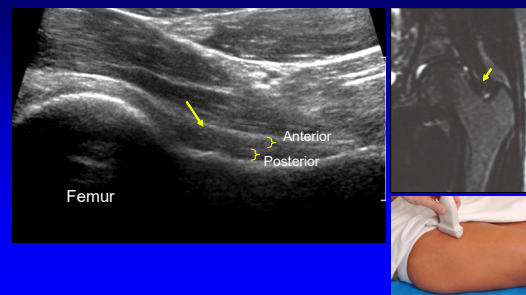
- Anterior and posterior layers
 - Fibrous tissue + minute layer of synovium
 - Hyperechoic
 - Each 2 - 4 mm thick

Radiology
1999; 210:499

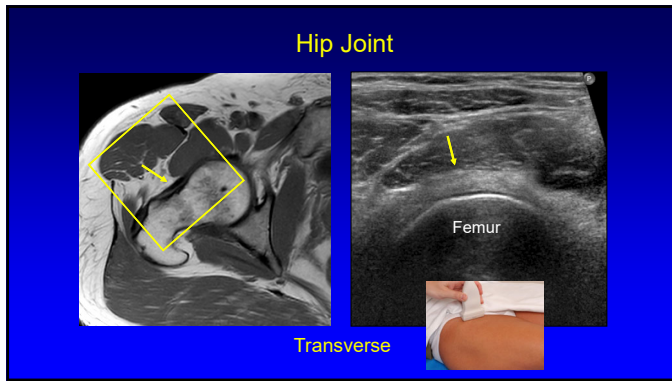


5

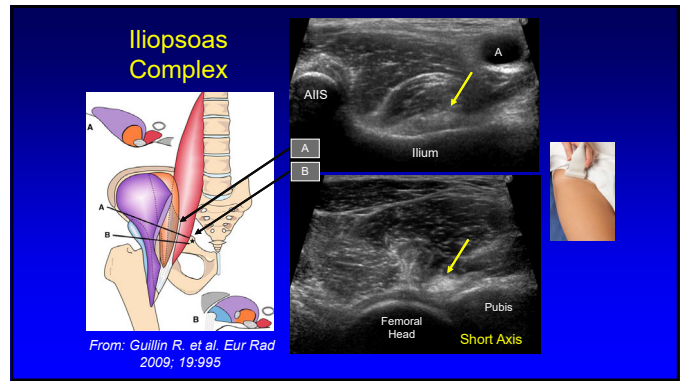
Hip: anterior recess



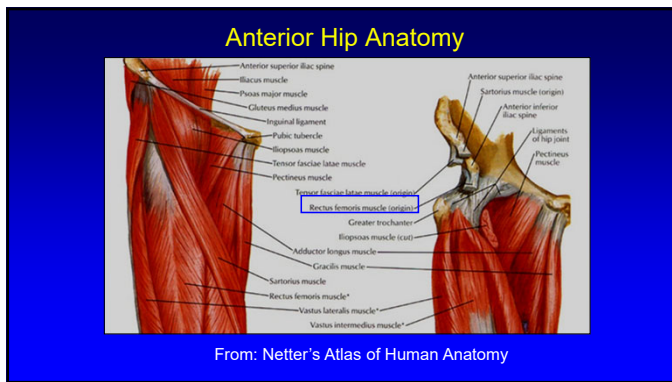
6



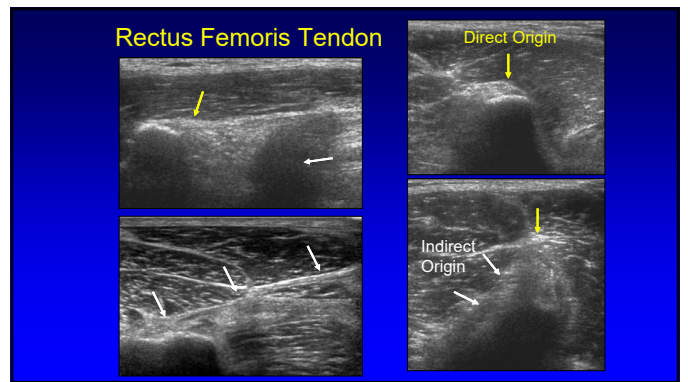
7



8



9



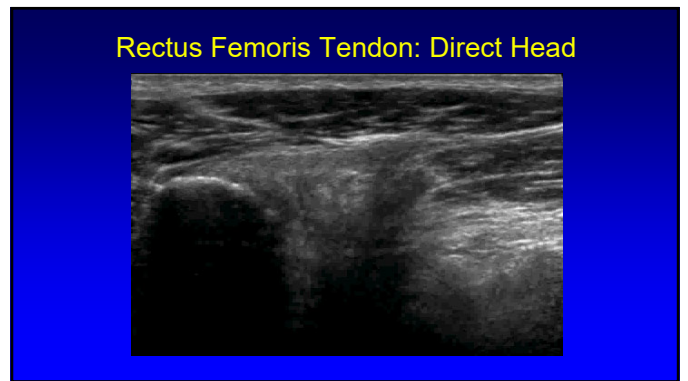
10

Rectus Femoris Origin: Indirect Head

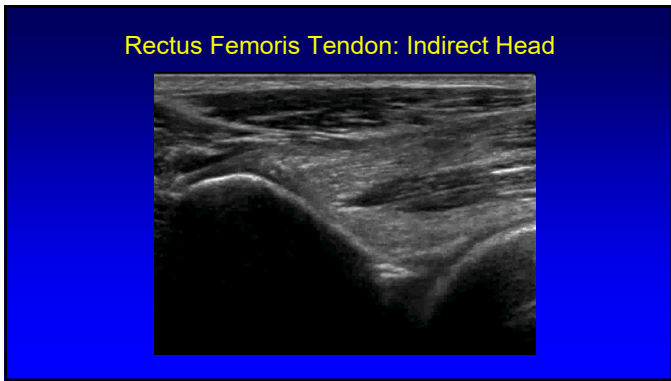
- Indirect or reflected head
- Anterolateral hip:
 - Superior acetabular ridge
 - Hip joint capsule
 - Forms central aponeurosis
- Oblique axial plane: 30°
 - 34 (l) x 10 (w) x 4 (thick) mm
- Injury more common than direct head

From: Moraux A et al. 2015 Eur Radiol 25:3614

11



12



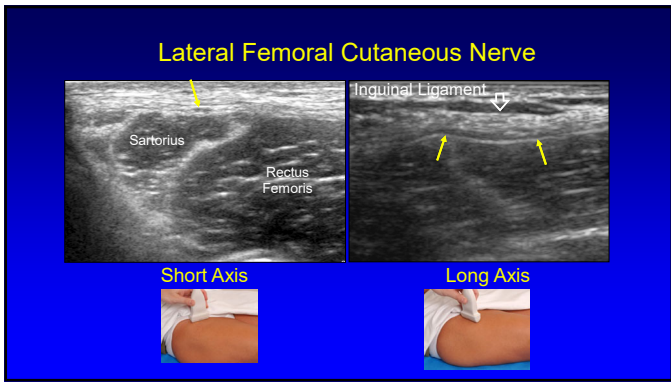
13

Lateral Femoral Cutaneous Nerve

- Sensory: anterolateral thigh
- Variable course:
 - 62% medial, 27% superficial, 11% lateral to ASIS
- Variable branching
- Superficial to sartorius
 - Lateral fat triangle

Rudin D et al. JBJS 2016; 98:561

14

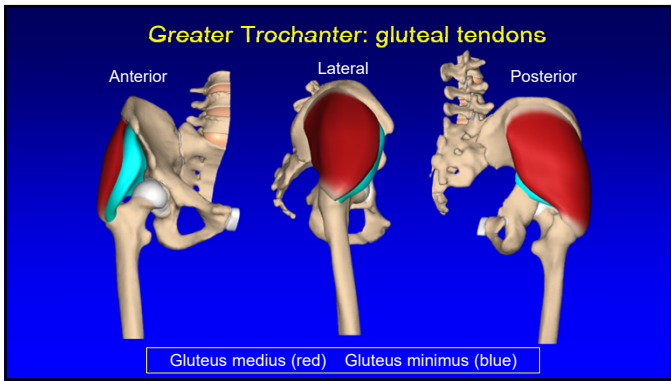


15

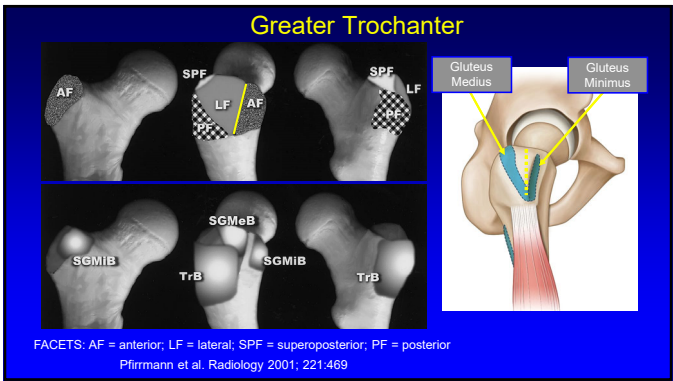
Sonographic Technique: Hip

- Lateral
 - Greater trochanter
 - Gluteal tendons
 - Bursae
 - Snapping hip
- Transducers:
 - 10 – 12 MHz linear
 - <10 MHz curvilinear if needed

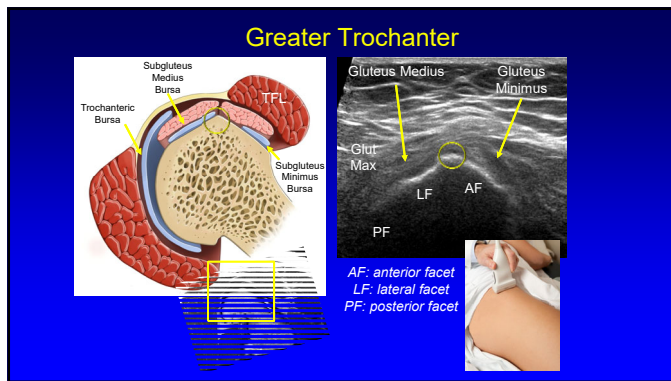
16



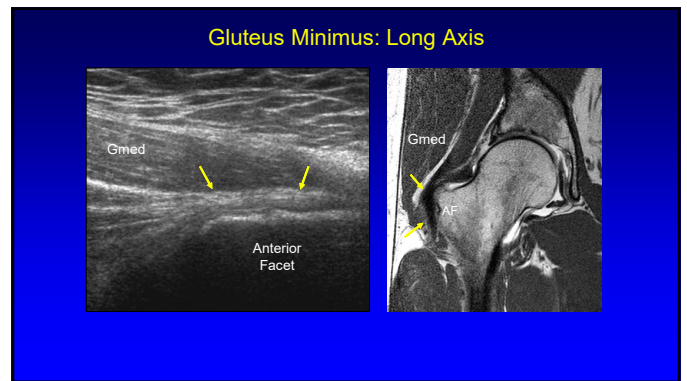
17



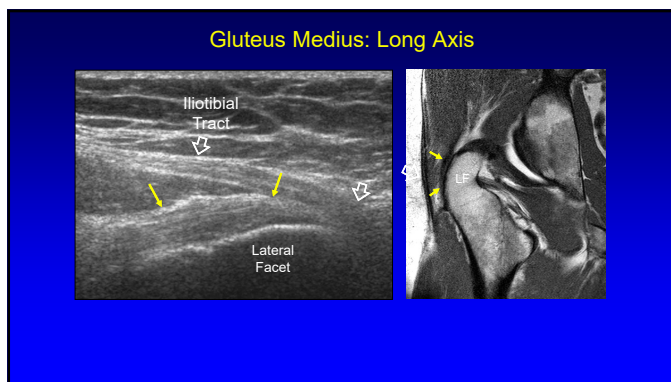
18



19



20



21

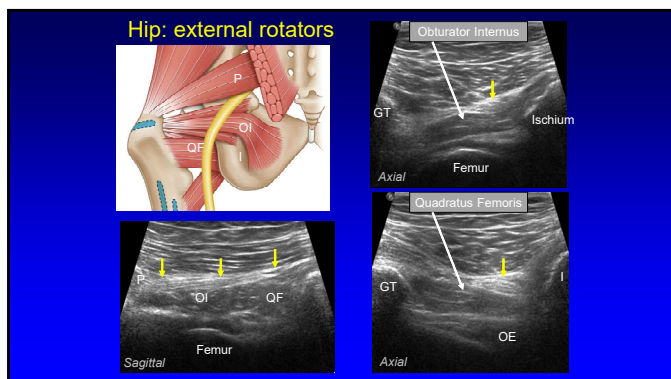
Sonographic Technique: Hip

- **Posterior**
 - Piriformis
 - Superior gemellus
 - Obturator internus
 - Inferior gemellus
 - Obturator externus
 - Quadratus femoris
 - Sciatic nerve

Gluteus maximus (cut)
Gluteus medius (cut, gluteal)
Gluteus minimus
Gluteus medius (insertional footprint)
Vastus Tubercle
Gluteus maximus (cut)
Adductor brevis (insertional footprint)
Pectineus
Biceps
Obturator externus
Obturator internus
Piriformis
Quadratus femoris (gluteus to ischio- and iliopectineus)

From: Philippon et al. Orth J Sports Med 2014

22



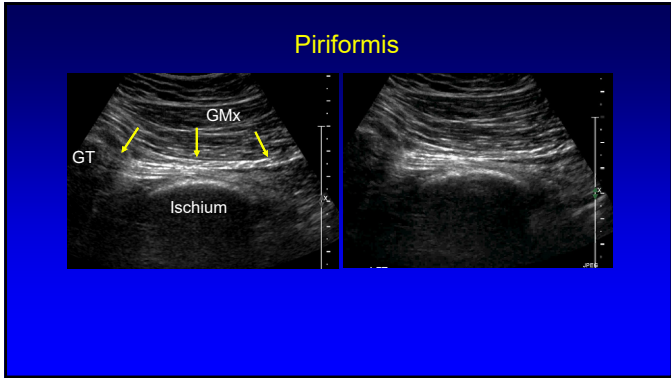
23

Piriformis

- **Technique:**
 - Low frequency **curvilinear** transducer
 - Axial plane
 - Move transducer inferior to SI joint
 - Angle transducer: inferior and lateral
 - Rotate hip internally: movement of tendon

Finoff JT et al. J Ultrasound Med 2008; 27:1157

24



25

Sonographic Technique: thigh

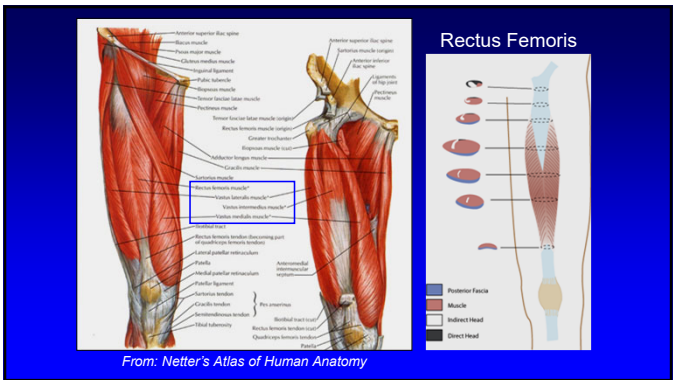
- Standardized sequence
 - Anterior: quadriceps femoris
 - Medial: adductors
 - Posterior: hamstrings
- Focused examination
- Transducers:
 - 5 MHz curvilinear (*ensure global evaluation!*)
 - 10 MHz linear

26

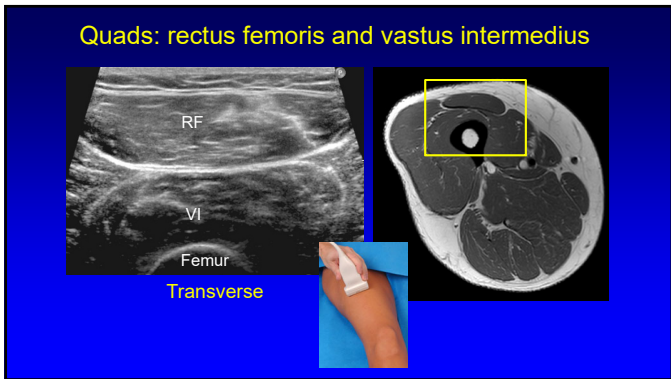
Sonographic technique: thigh

- **Anterior**
 - Rectus femoris
 - Vastus intermedius
 - Vastus lateralis
 - Vastus medialis
- Transducers:
 - 10 – 12 MHz linear
 - <10 MHz curvilinear if needed

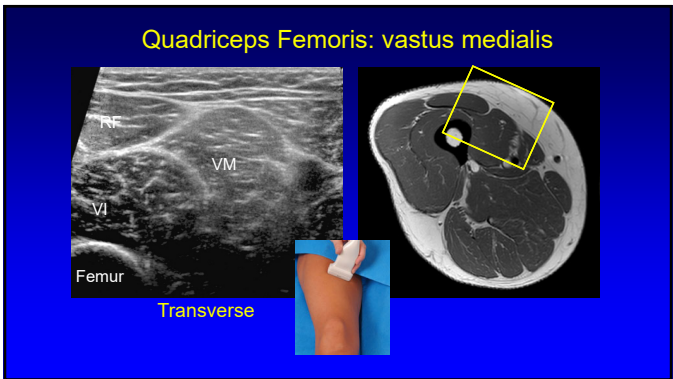
27



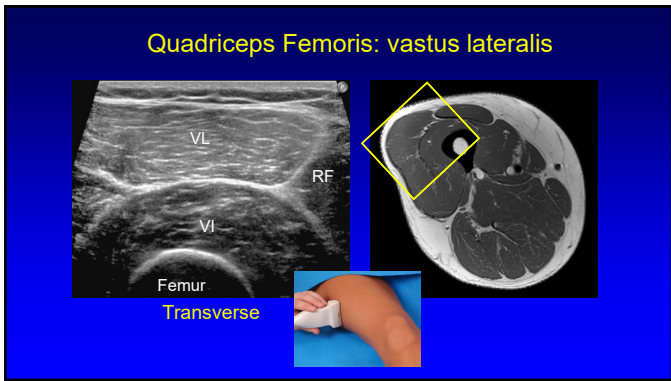
28



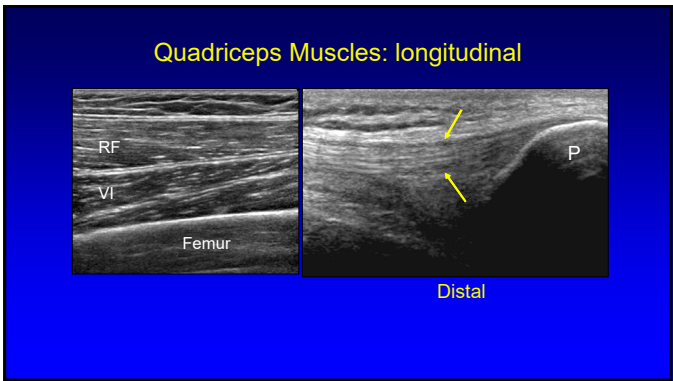
29



30



31

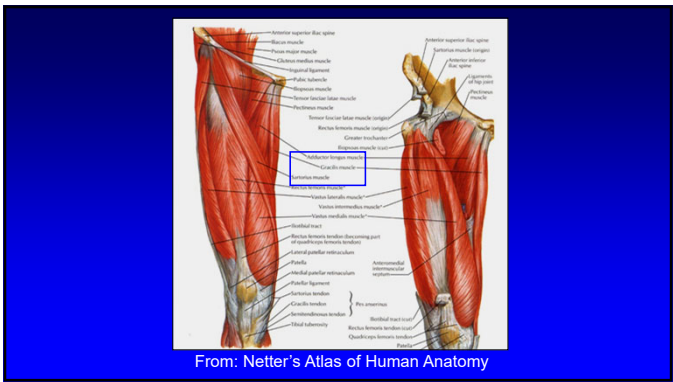


32

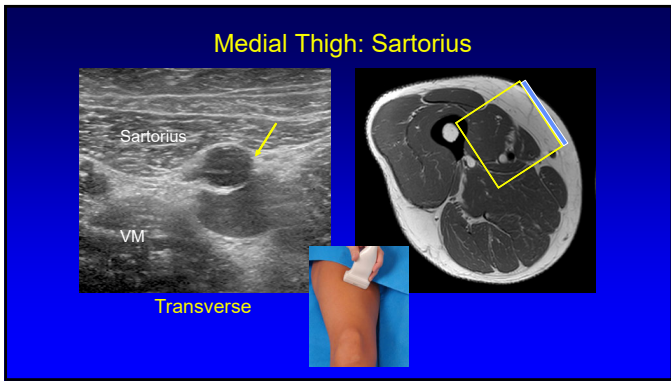
Sonographic technique: thigh

- **Medial**
 - Adductors
 - Sartorius
 - Gracilis
- **Transducers:**
 - 10 – 12 MHz linear
 - <10 MHz curvilinear if needed

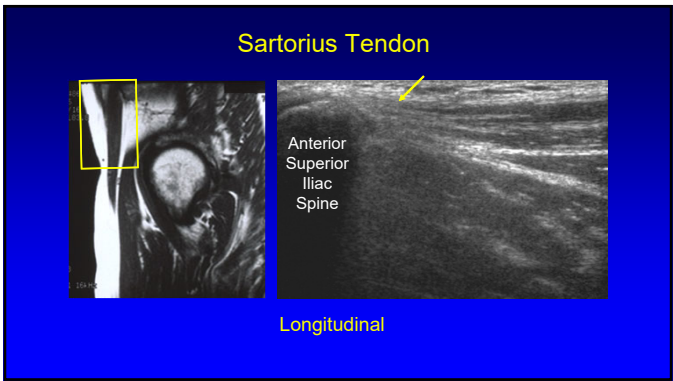
33



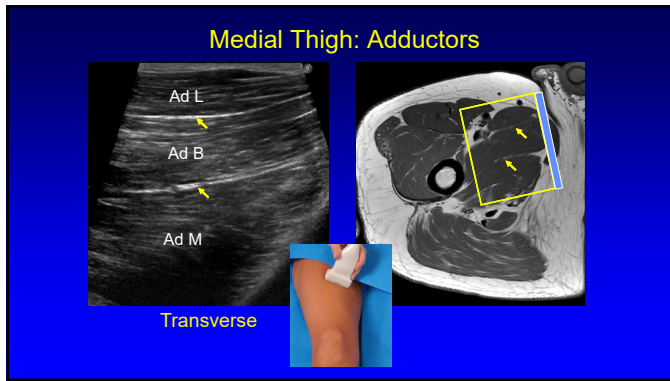
34



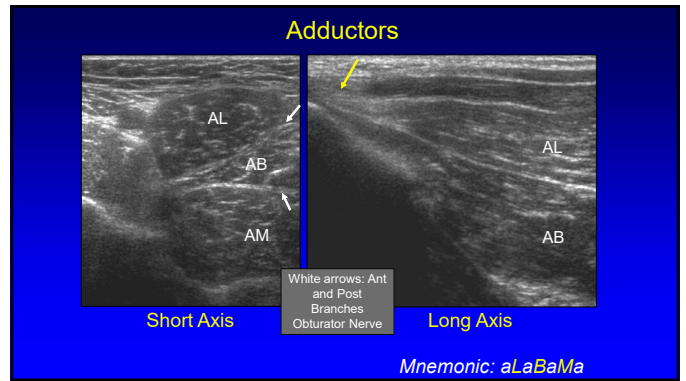
35



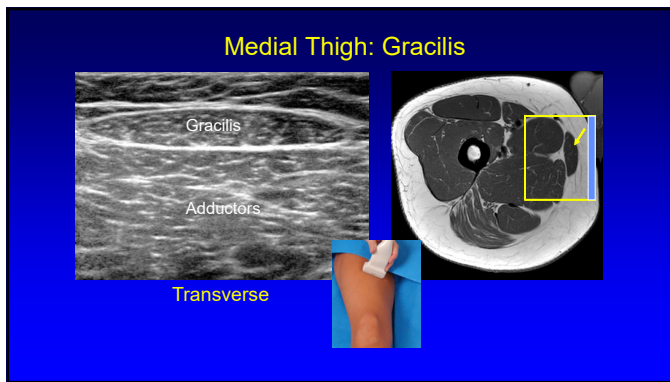
36



37



38



39

Saphenous Nerve

- Largest cutaneous branch of the femoral nerve
- Travels beneath sartorius:
 - Moves anterior to posterior
 - Over gracilis tendon
- Infrapatellar branch: thru sartorius
- Subcutaneous: great saphenous vein

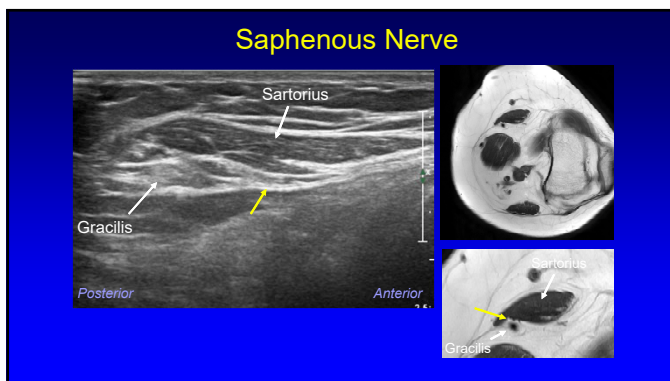
Gracilis Sartorius

Adductor Magnus Vastus Medialis

Posterior Anterior

Gr. Saphenous Vein

40

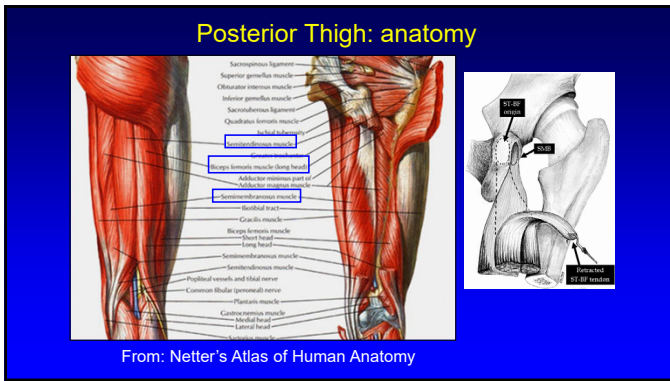


41

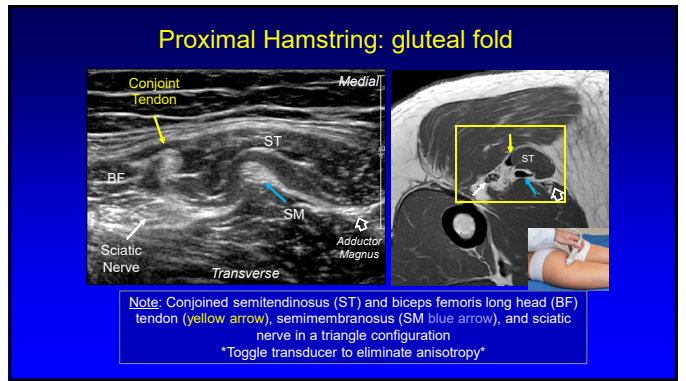
Sonographic Technique: Thigh

- Posterior:
 - Semimembranosus
 - Semitendinosus
 - Biceps femoris
 - Long and short heads
 - Sciatic nerve
- Transducers:
 - 10 – 12 MHz linear
 - <10 MHz curvilinear if needed

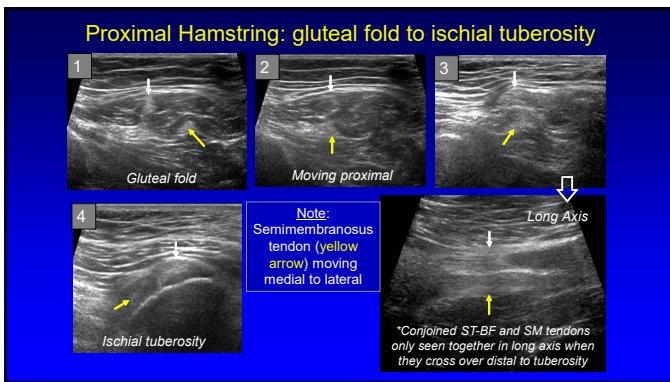
42



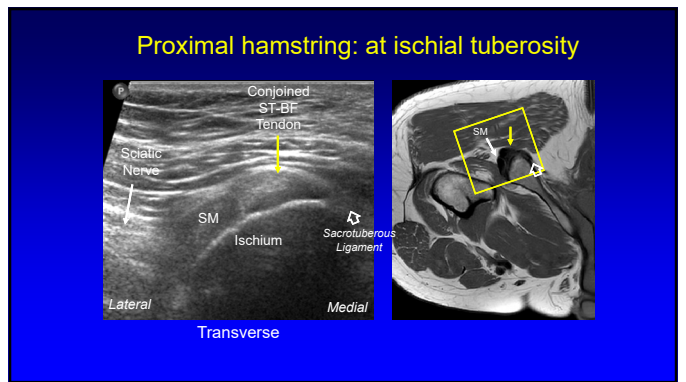
43



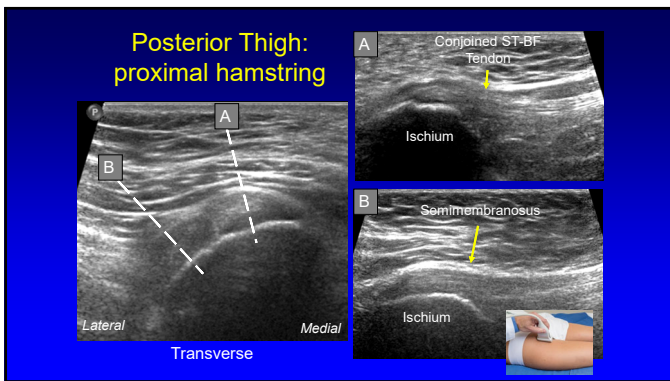
44



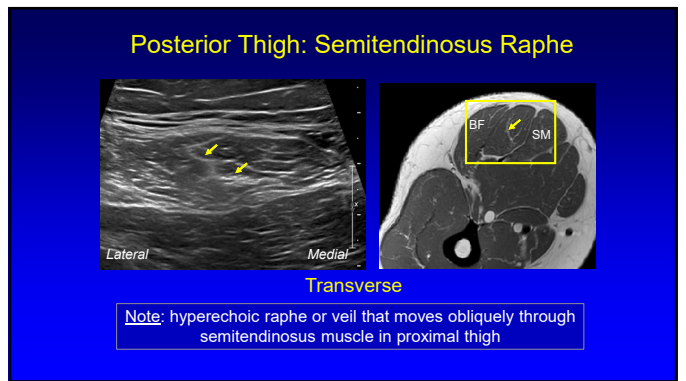
45



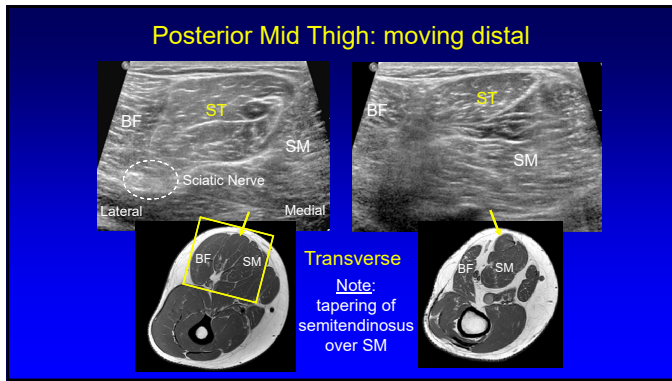
46



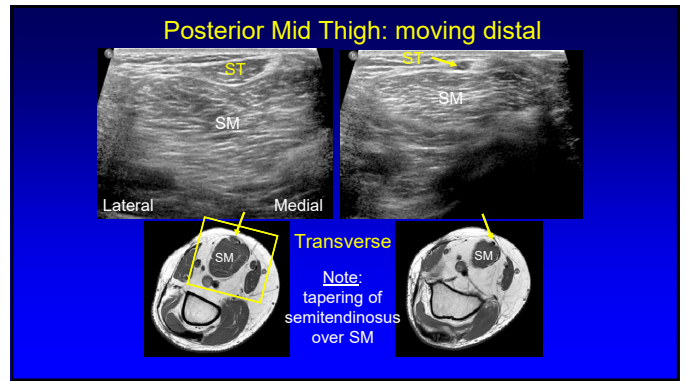
47



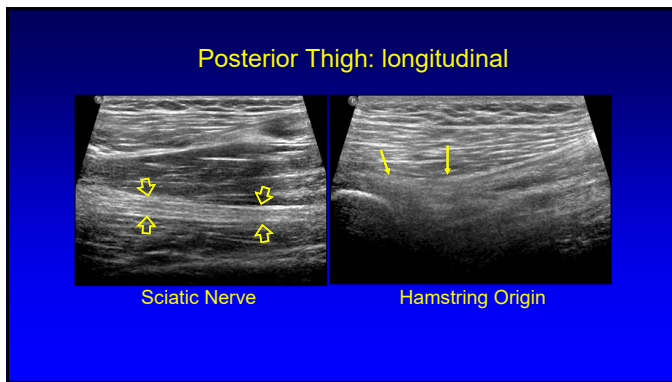
48



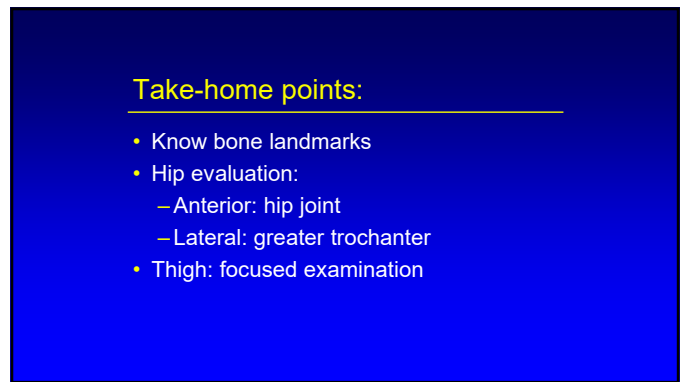
49



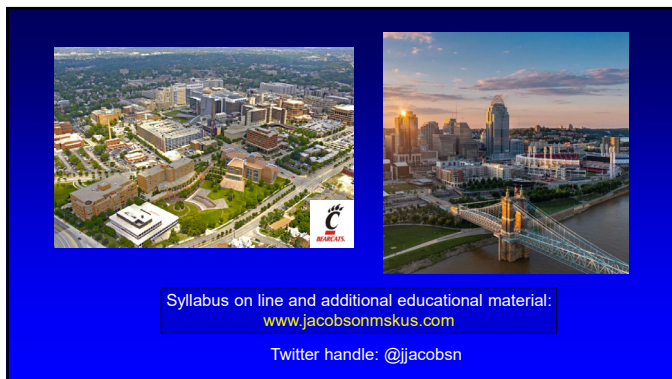50



51



52



53