

# Ultraound of Common Knee Pathology

**Jon A. Jacobson, MD**  
 FACR, FSRU, FAIUM, RMSK  
 Professor of Radiology  
 Lenox Hill Radiology, NYC  
 University of California, San Diego



1

## Disclosures

- Consultant: Bioclinica
- Contractor: POCUS PRO
- Advisory Board: Philips
- Book Royalties: Elsevier
- Not relevant to this lecture

*Note: all images from the textbook  
 Fundamentals of Musculoskeletal Ultrasound are  
 copyrighted by Elsevier Inc.*

See [www.jacobsonmskus.com](http://www.jacobsonmskus.com) for syllabus other educational material

2

## Outline

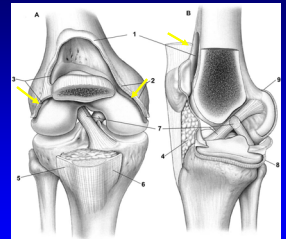
- Joint effusion
- Extensor mechanism
- Baker cyst and other bursa

3

## Joint Effusion

- Suprapatellar recess: superior
  - Prefemoral & quadriceps fat pad separation
  - Distends with partial knee flexion
- Medial and lateral recesses
  - Adjacent to patella
  - Distends with knee extension
  - Transducer pressure displaces joint effusion

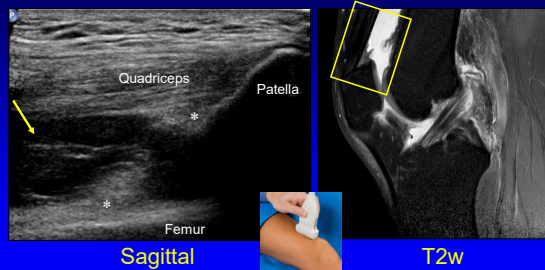
### Suprapatellar Recess and Gutters



*From: Miller PJ et al. Am J Sports Med  
 2001;29:822.*

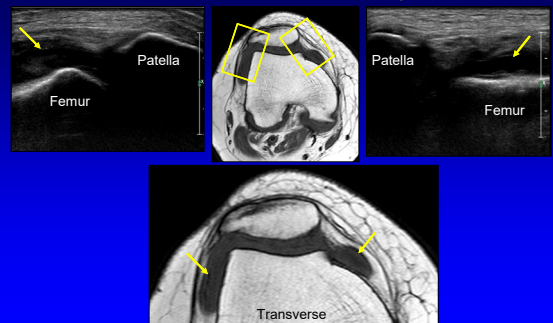
4

## Joint Effusion: sagittal plane

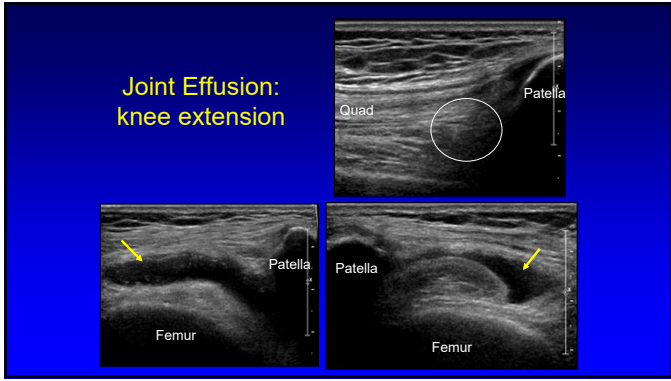


5

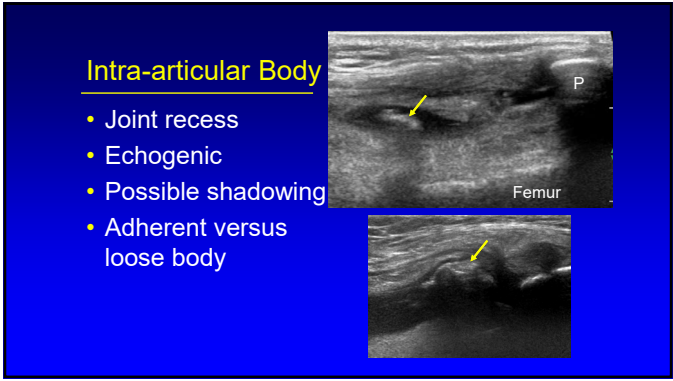
## Joint Effusion: transverse plane



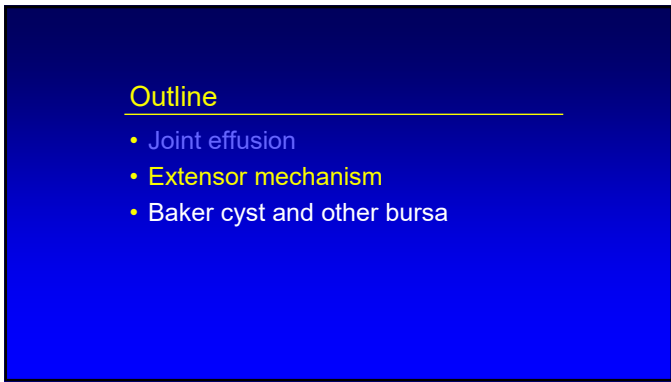
6



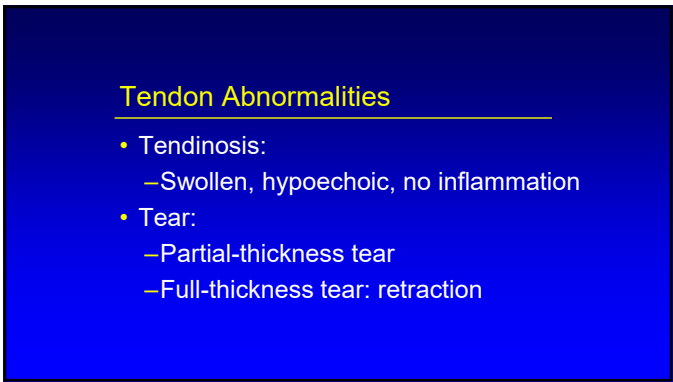
7



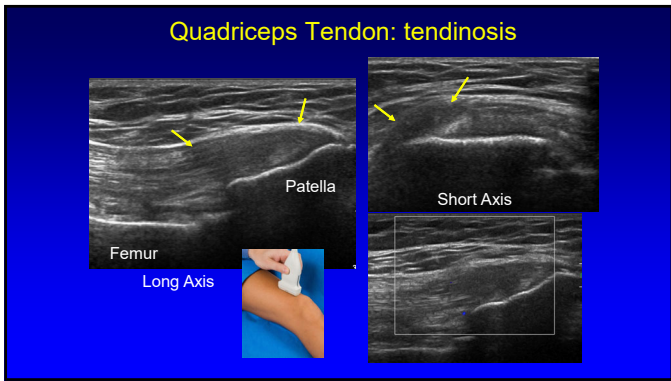
8



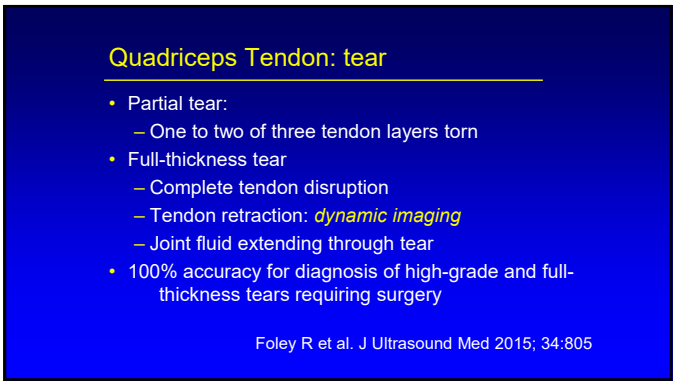
9



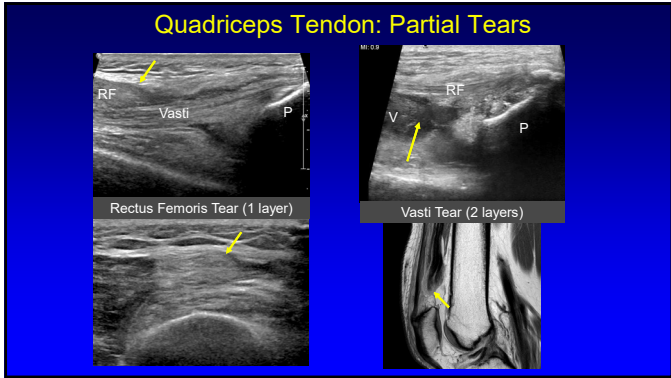
10



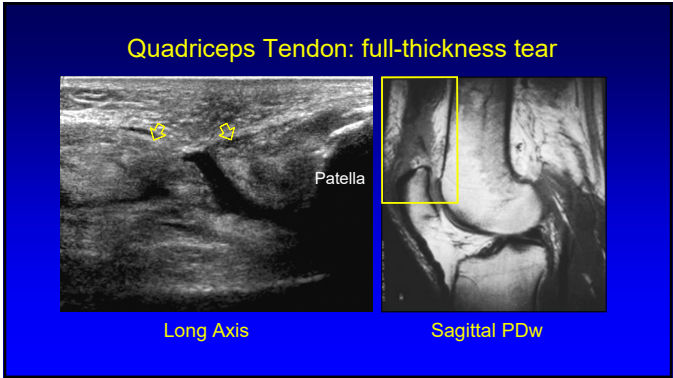
11



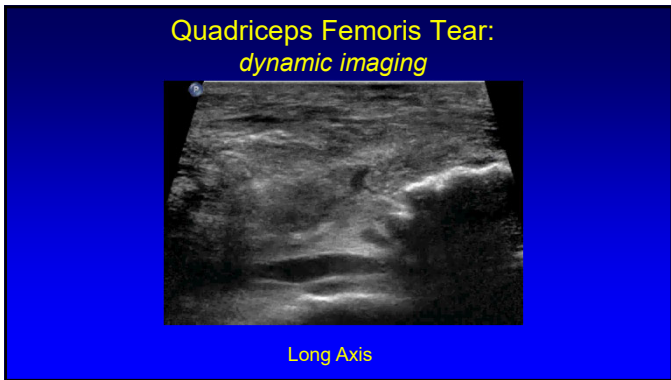
12



13



14



15

### Patellar Tendinosis

- Jumper's knee
- Mucoïd degeneration
- No inflammatory cells
- Possible partial thickness tear
- Proximal
- Hypoechoic, swollen
- Hyperemia: neovascularity

Radiology 1996; 200:821

16

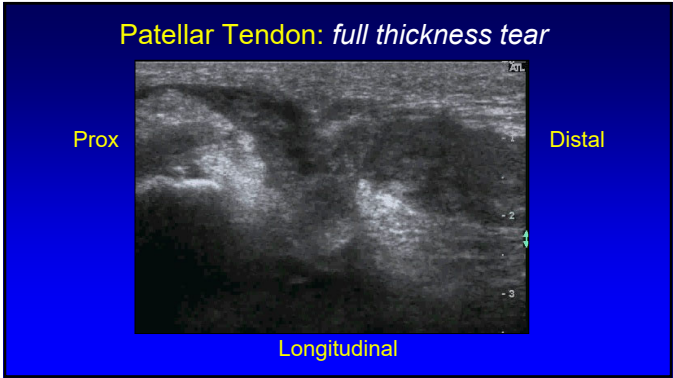
### Patellar Tendon Tear

- Full-thickness tear
  - Hypoechoic
  - Posterior shadowing at ends of torn tendon
  - Tendon retraction
  - Patellar alta

AJR 2001; 176:1535

*\*Different Patients*

17



18

### Osgood-Schlatter Disease

- Painful condition
- Distal patellar tendon insertion on tibia
- Young male athletes
- Tendon swelling and tibial tuberosity irregularity

19

### Outline

- Joint effusion
- Extensor mechanism
- Baker cyst and other bursa

20

### Knee Bursae

21

### Baker Cyst

- Semimembranosus-medial gastrocnemius bursa
- 50% over age of 50 have communication with knee joint
- Cyst communication to posterior knee between SM-MG tendons required

Ward EE et al. AJR 2001; 176:373

22

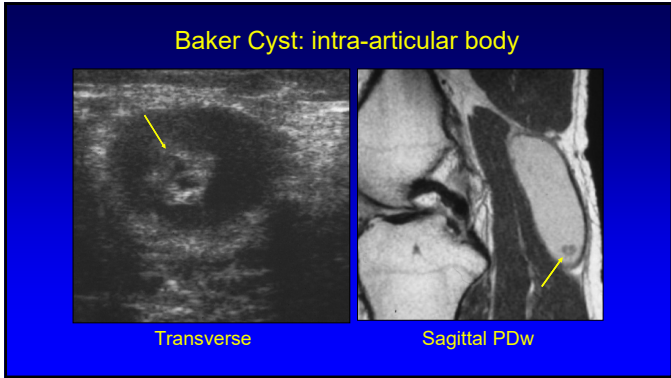
### Baker Cyst Evaluation: pitfall

23

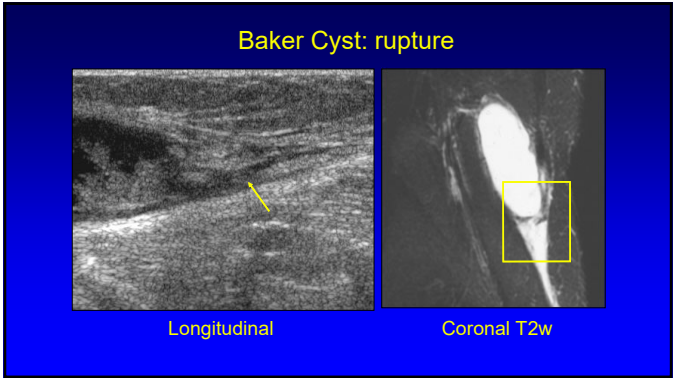
### Baker Cyst: hemorrhage

Longitudinal      Axial T1w

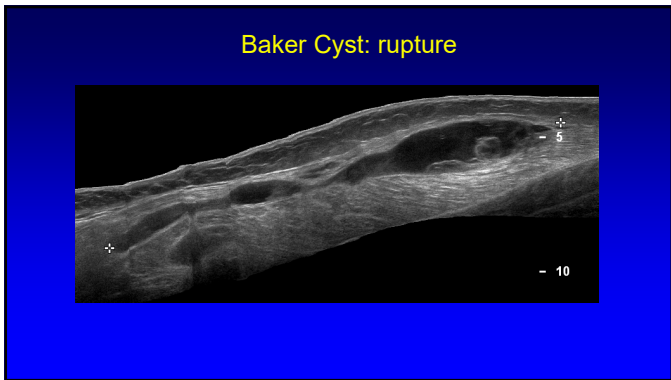24



25



26

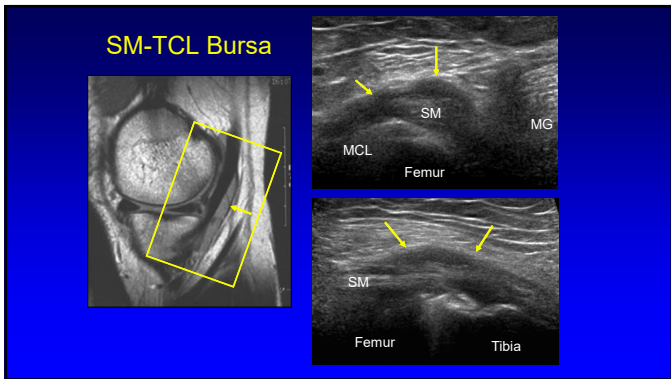


27

### Myxoid Liposarcoma:

- Hypoechoic
- May look like a cyst
- Not a ganglion:
  - Not multilocular
  - Not a good location
- Not a Baker cyst:
  - No neck

28



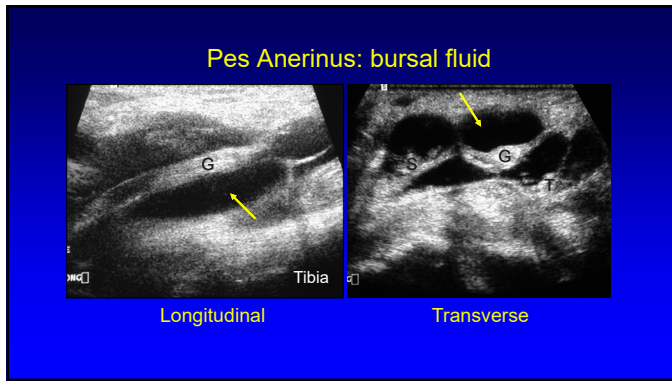
29

### Pes Anserinus

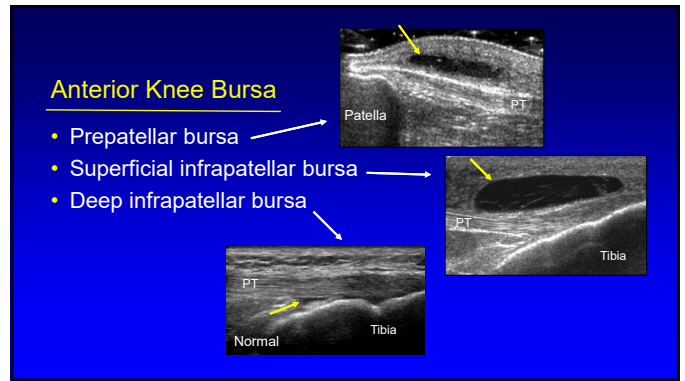
- Pes anserinus: "goose foot"
  - Sartorius
  - Gracilis
  - Semitendinosus
- Bursa:
  - Deep to conjoined tendon
  - Adjacent to proximal tibia
- Bursitis: rare

Radiology 1995; 194:525

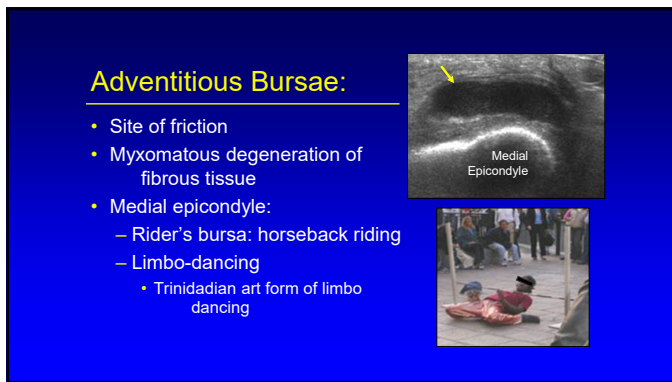
30



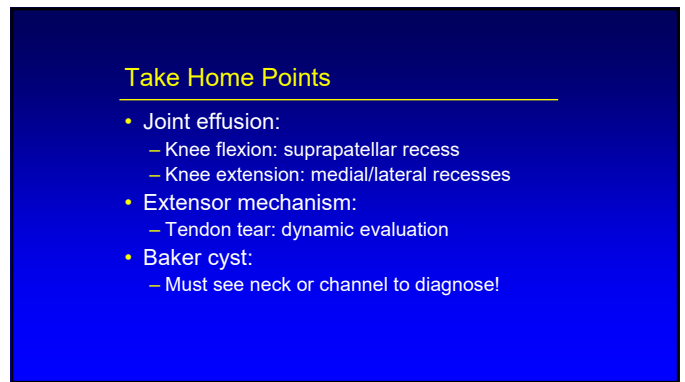
31



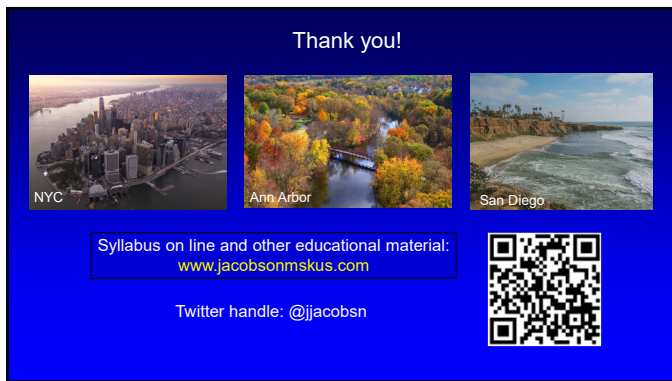
32



33



34



35