

Ultrasound of Knee Pathology and Intervention

Jon A. Jacobson, MD
 FACR, FSRJ, FAIUM, RMSK
 Professor of Radiology
 Lenox Hill Radiology, NYC
 University of California, San Diego



1

Outline

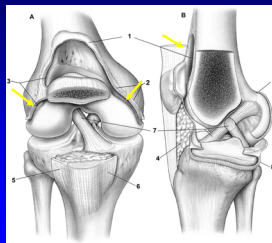
- Joint effusion
- Extensor mechanism
- Popliteal cyst and other bursa

2

Joint Effusion

- Suprapatellar recess: superior
 - Prefemoral & quadriceps fat pad separation
 - Distends with partial knee flexion
- Medial and lateral recesses
 - Adjacent to patella
 - Distends with knee extension
 - Transducer pressure displaces joint effusion

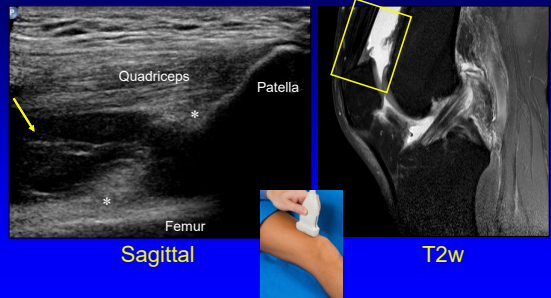
Suprapatellar Recess and Gutters



From: Miller PJ et al. Am J Sports Med 2001;29:822.

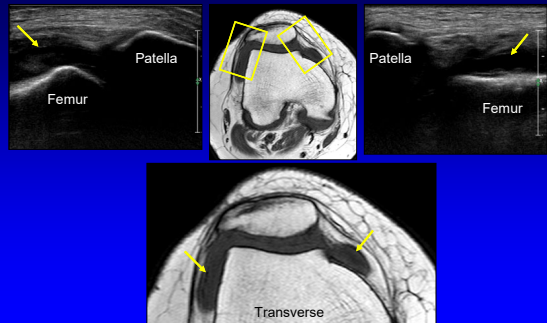
3

Joint Effusion: sagittal plane



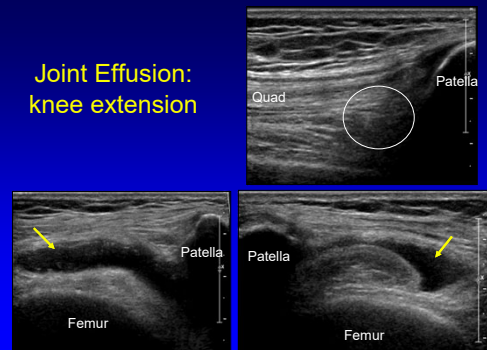
4

Joint Effusion: transverse plane



5

Joint Effusion: knee extension



6

Intra-articular Body

- Joint recess
- Echogenic
- Possible shadowing
- Adherent versus loose body

7

Knee Joint

- Suprapatellar recess or medial/lateral recesses
- In plane
- Transducer: axial
- Needle: lateral to medial

8

Outline

- Joint effusion
- Extensor mechanism
- Popliteal cyst and other bursa

9

Tendon Abnormalities

- Tendinosis:
 - Swollen, hypoechoic, no inflammation
- Tear:
 - Partial-thickness tear
 - Full-thickness tear: retraction

10

Quadriceps Tendon: tendinosis

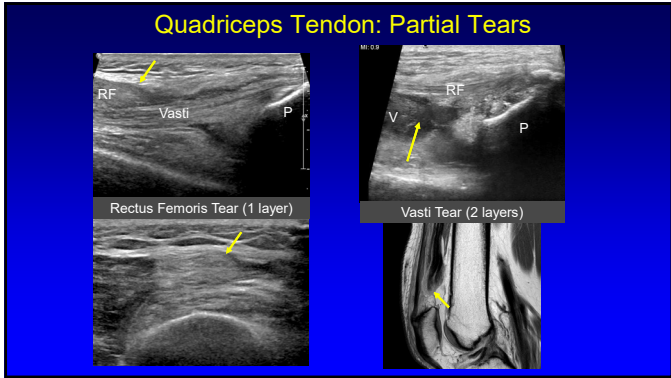
11

Quadriceps Tendon: tear

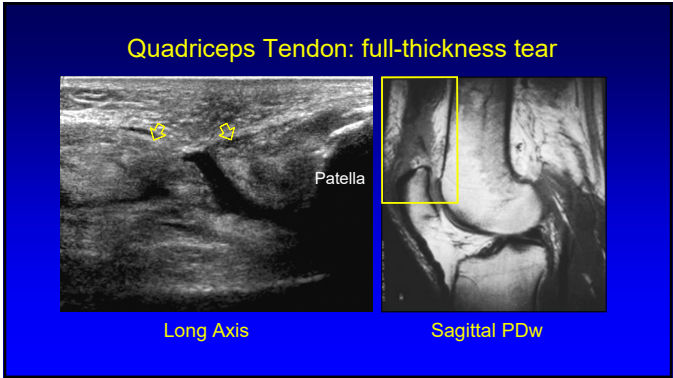
- Partial tear:
 - One to two of three tendon layers torn
- Full-thickness tear
 - Complete tendon disruption
 - Tendon retraction: *dynamic imaging*
 - Joint fluid extending through tear
- 100% accuracy for diagnosis of high-grade and full-thickness tears requiring surgery

Foley R et al. J Ultrasound Med 2015; 34:805

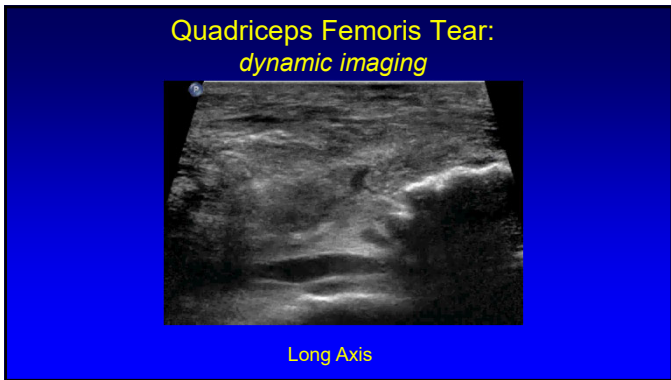
12



13



14



15

Patellar Tendinosis

- Jumper's knee
- Mucoïd degeneration
- No inflammatory cells
- Possible partial thickness tear
- Proximal
- Hypoechoic, swollen
- Hyperemia: neovascularity

Radiology 1996; 200:821

16

Patellar Tendon Tear

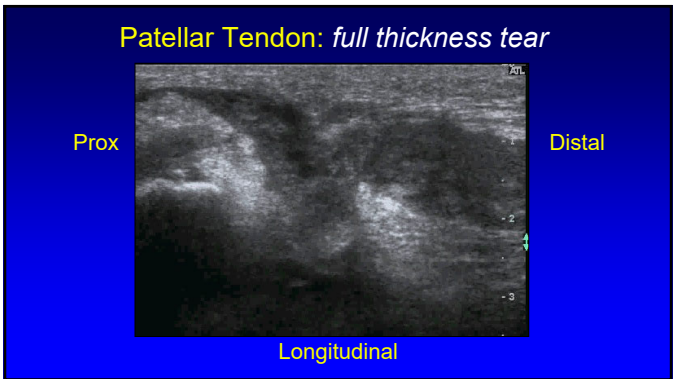
- Full-thickness tear
 - Hypoechoic
 - Posterior shadowing at ends of torn tendon
 - Tendon retraction
 - Patellar alta

AJR 2001; 176:1535

*Different Patients

Patella

17



18

Osgood-Schlatter Disease

- Painful condition
- Distal patellar tendon insertion on tibia
- Young male athletes
- Tendon swelling and tibial tuberosity irregularity

19

Patellar Tendon: fenestration

20

Outline

- Joint effusion
- Extensor mechanism
- **Popliteal cyst and other bursa**

21

Knee Bursae

22

Popliteal (Baker) Cyst

- Semimembranosus-medial gastrocnemius bursa
- 50% over age of 50 have communication with knee joint
- Cyst communication to posterior knee between SM-MG tendons required

Note: femoral condyle bone landmark

Ward EE et al. AJR 2001; 176:373

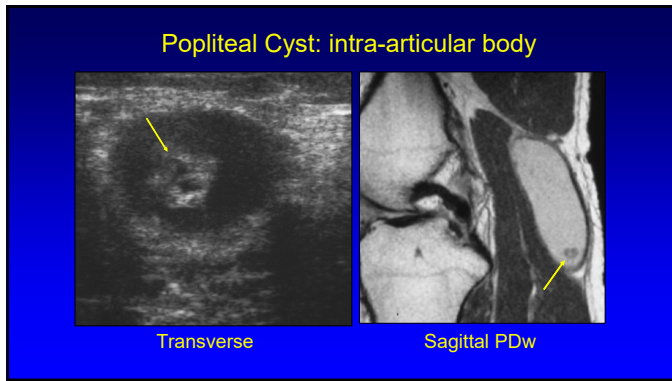
23

Popliteal Cyst: hemorrhage

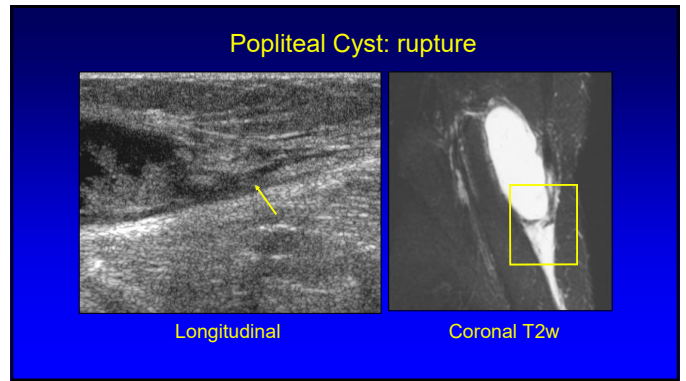
Longitudinal

Axial T1w

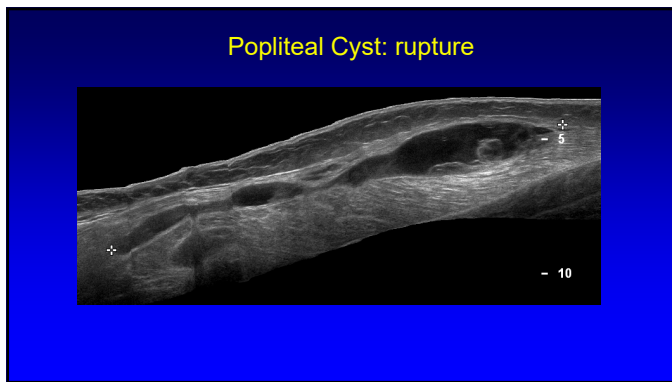
24



25



26



27

Popliteal Cyst

- Aspiration
 - Inferior to superior
 - Medial to lateral
- Aspirate joint effusion first if present
- Steroid injection
 - Popliteal cyst injection works better than intra-articular injection!

*Banidelli F. et al. Clin Rheum 2012; 31:727

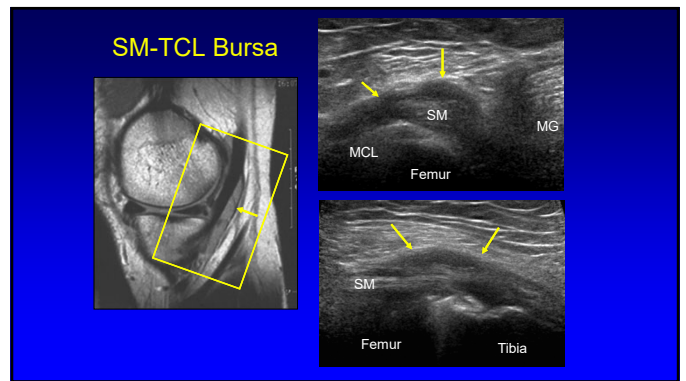
Inferior to superior

28

Myxoid Liposarcoma:

- Hypoechoic
- May look like a cyst
- Not a ganglion:
 - Not multilocular
 - Not a good location
- Not a Baker cyst:
 - No neck

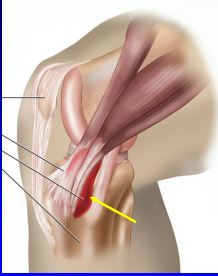
29



30

Pes Anserinus

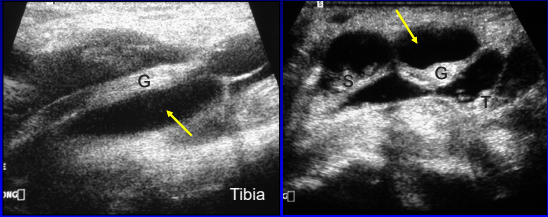
- Pes anserinus: "goose foot"
 - Sartorius
 - Gracilis
 - Semitendinosus
- Bursa:
 - Deep to conjoined tendon
 - Adjacent to proximal tibia
- Bursitis: rare



Radiology 1995; 194:525

31

Pes Anserinus: bursal fluid

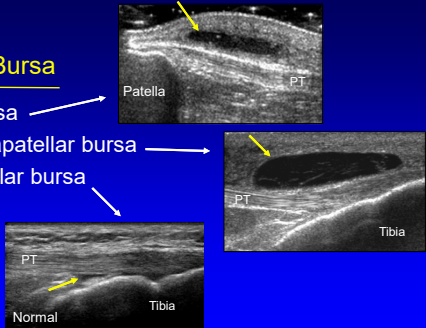


Longitudinal Transverse

32

Anterior Knee Bursa

- Prepatellar bursa
- Superficial infrapatellar bursa
- Deep infrapatellar bursa



Patella PT PT Tibia Normal Tibia


33

Take Home Points

- Joint effusion:
 - Knee flexion: suprapatellar recess
 - Knee extension: medial/lateral recesses
- Extensor mechanism:
 - Tendon tear: dynamic evaluation
- Popliteal cyst:
 - Must see neck or channel to diagnose!

34


Thank you!



NYC Ann Arbor San Diego

Syllabus on line and other educational material:
www.jacobsonmskus.com

Twitter handle: @jjacobsn



35