

Top 5 Can't Miss Diagnoses: Lower Extremity

Jon A. Jacobson, MD
FACR, FSRU, FAIM, RMSK

Professor of Radiology
Lenox Hill Radiology, NYC
University of California, San Diego

1

Disclosures

- Consultant: Bioclinica
- Contractor: POCUS PRO
- Advisory Board: Philips
- Book Royalties: Elsevier
- Not relevant to this lecture



Syllabus PDF

See www.jacobsonmskus.com for syllabus other educational material

2

Outline

- Greater trochanteric pain syndrome
- Baker cyst
- Achilles pathology
- Morton neuroma
- Gout

3

Greater Trochanteric Pain Syndrome

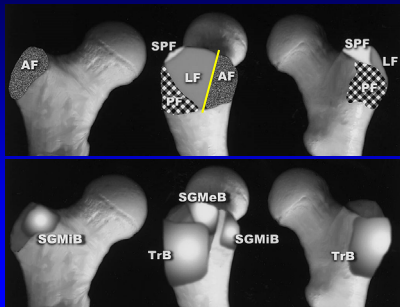
- Trochanteric bursitis: uncommon
 - 20% of symptomatic patients²
 - Not actually inflamed³
 - Not associated with pain⁴
- Most commonly caused by gluteus minimus and medius tendon abnormalities¹



¹Eur Rad 2007; 17:1772
²Long SS et al. AJR 2013; 201:1083
³Clin Rheumatol 2008; 14:82
⁴Skeletal Radiol 2008; 37:903

4

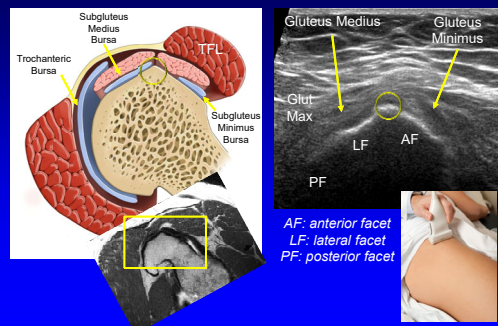
Greater Trochanter



Pfarrmann et al. Radiology 2001; 221:469

5

Greater Trochanter



AF: anterior facet
LF: lateral facet
PF: posterior facet

6

Gluteal Tendon Pathology:

- Tendinosis: hypoechoic, no defects
- Partial tear: anechoic clefts
- Complete tear: discontinuous tendon
- >2 mm cortical irregularity is associated with tendon tear
 - Positive predictive value = 90% (xray)*

*Steinert et al. Radiology 2010; 257:754

7

Gluteus Medius: tendinosis

8

Trochanteric Bursitis: Septic

Note posterior location of bursa

9

Artificial Intelligence Failure: #21

Labradoodle versus Fried Chicken

10

Outline

- Greater trochanteric pain syndrome
- Baker cyst
- Achilles pathology
- Morton neuroma
- Gout

11

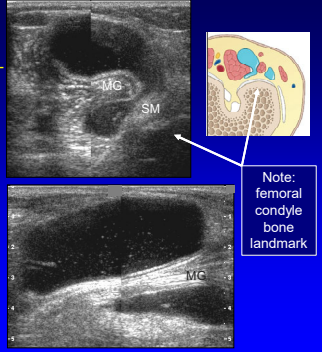
Knee Bursae

12

Baker Cyst

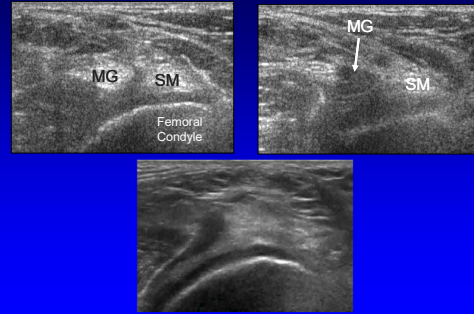
- Semimembranosus-medial gastrocnemius bursa
- 50% over age of 50 have communication with knee joint
- Cyst communication to posterior knee between SM-MG tendons required

Ward EE et al. AJR 2001; 176:373



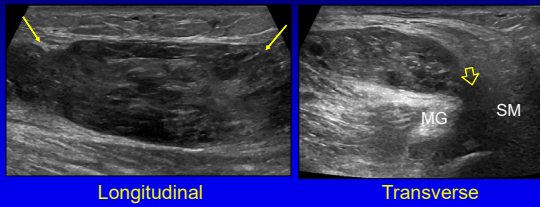
13

Baker Cyst Evaluation: pitfall



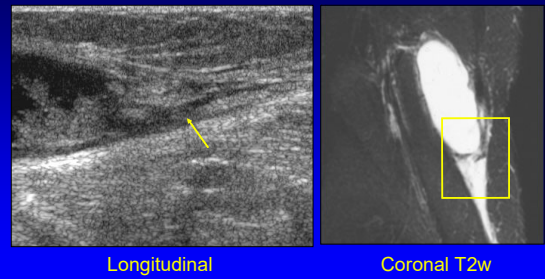
14

Baker Cyst: rupture + hemorrhage



15

Baker Cyst: rupture



16

Artificial Intelligence Failure: #43 Chihuahua versus Blueberry Muffin



17

Outline

- Greater trochanteric pain syndrome
- Baker cyst
- Achilles pathology
- Morton neuroma
- Gout

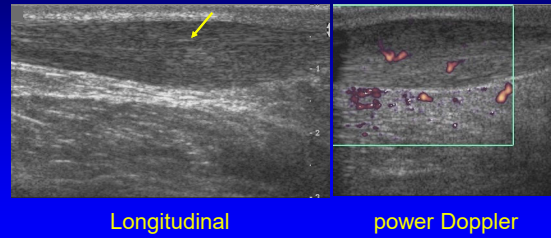
18

Achilles Tendon

- Locations:
 - 2 – 6 cm proximal to insertion
 - Calcaneal attachment: less common
 - Haglund syndrome
- Pathology:
 - Paratendinitis: no tendon sheath
 - Tendinosis: hypoechoic, enlarged
 - Partial tear: anechoic clefts
 - Full-thickness tear: retraction

19

Tendinosis: Achilles

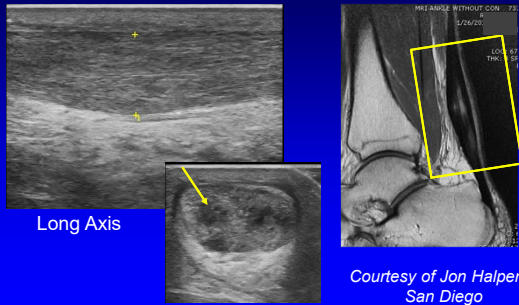


Longitudinal

power Doppler

20

Achilles Tendon: partial-thickness tear

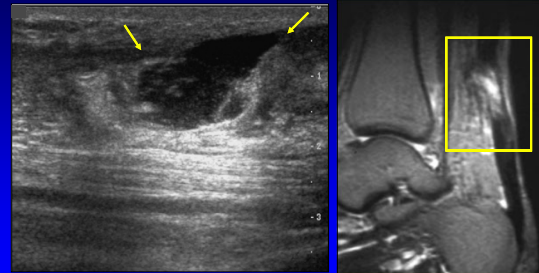


Long Axis

Courtesy of Jon Halperin, San Diego

21

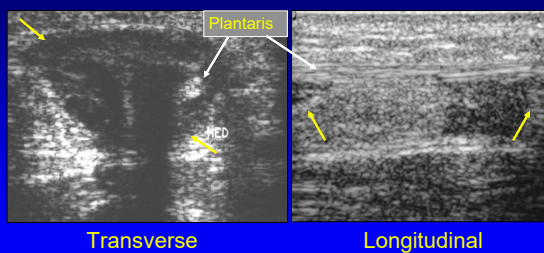
Achilles Tendon: full-thickness tear



Sagittal T2w

22

Achilles FTT + Intact Plantaris

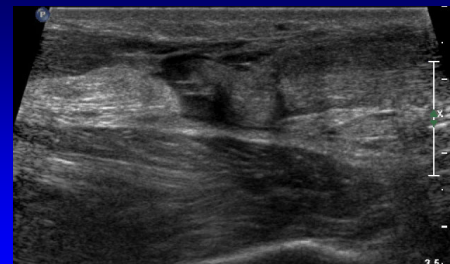

Transverse

Longitudinal

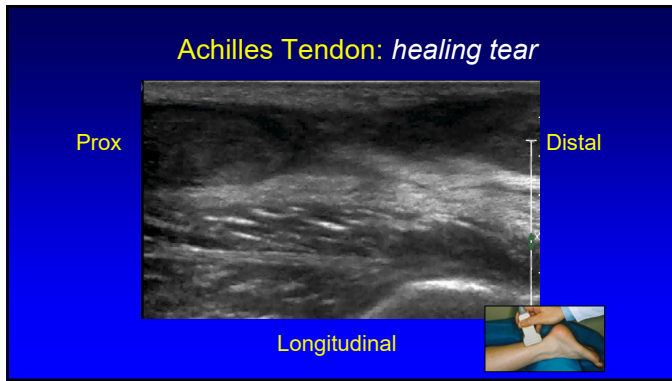23

Achilles Tendon: dynamic imaging

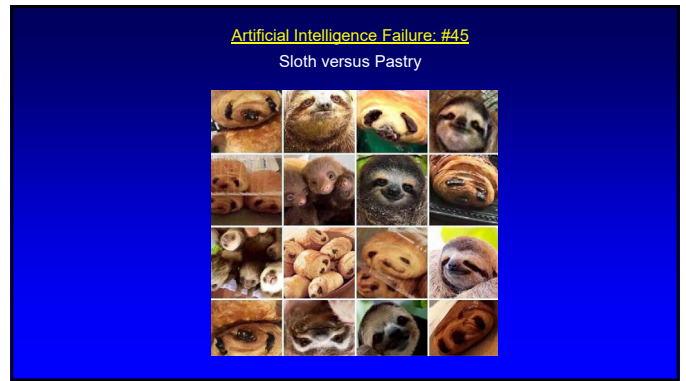

Long Axis

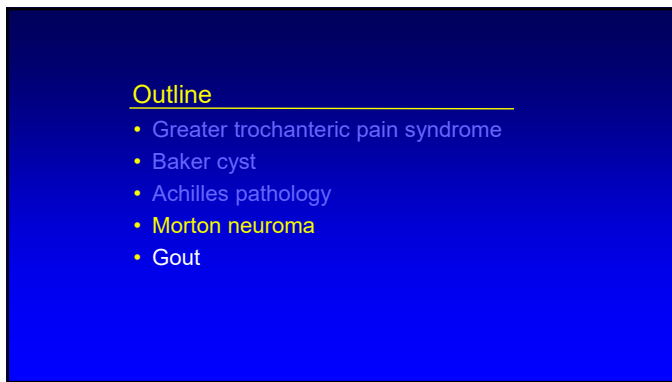
24



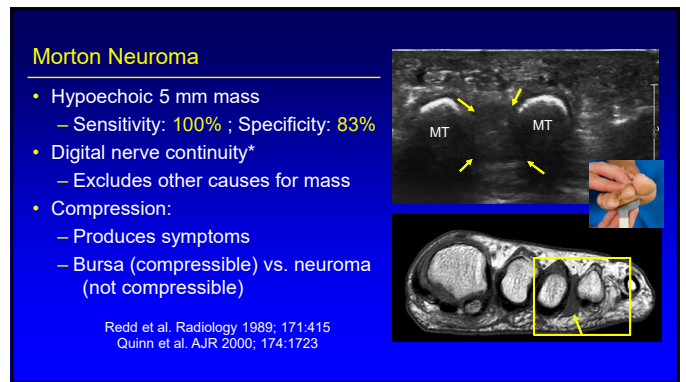
25



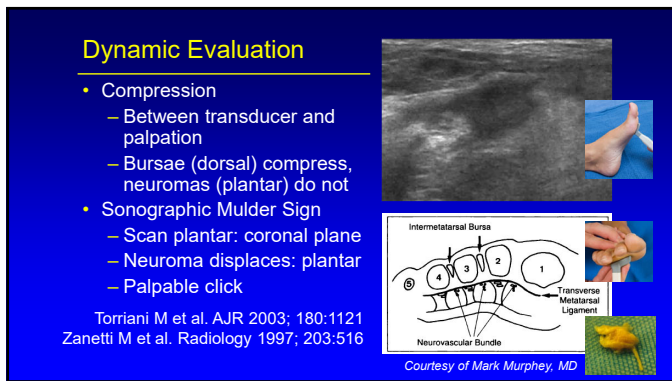
26



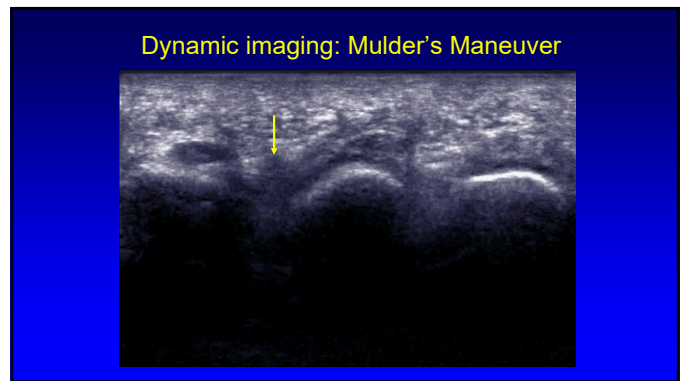
27



28



29



30



31

Outline

- Greater trochanteric pain syndrome
- Baker cyst
- Achilles pathology
- Morton neuroma
- **Gout**

32

Gout:

- Monosodium urate crystals:
 - Negative birefringence
- Stages:
 - Asymptomatic hyperuricemia
 - Acute gouty arthritis
 - Interval asymptomatic phase
 - Chronic tophaceous gout

33

Gout:

- Joint effusion / synovial hypertrophy
- Double contour sign:
 - Monosodium urate crystal icing on cartilage
- Tophi:
 - Hyperechoic with hypoechoic rim
- Erosions:
 - Adjacent to tophi
- Sites:
 - Foot: distal first metatarsal
 - Knee: popliteus, patellar tendon + bursa

34

Gout: Double Contour Sign

1st MTP Joint Ankle Joint

35

Tophi

- Hyperechoic heterogeneous with hypoechoic rim
- Tiny internal speckles*
- “wet clump of sugar” appearance
- Variable shadowing: even without calcification

MT PP

Fernandes et al. Skeletal Radiol 2011; 40:309

36

Take Home Points

- Greater trochanteric pain: it's not bursitis!
- Baker cyst: must see the neck
- Achilles tear: dynamic evaluation
- Morton neuroma: Mulder maneuver
- Gout: cumulus cloud + stars

37

Thank you!



Syllabus on line and other educational material:
www.jacobsonmskus.com

Twitter handle: @jjacobsn

38