

Wrist and Hand Ultrasound: Anatomy and Scanning Technique

Jon A. Jacobson, MD FACR

Professor of Radiology
Section Chief, Musculoskeletal Imaging



1

Disclosures

- Consultant: Bioclinica
- Book Royalties: Elsevier
- Contractor: POCUS PRO
- Advisory Board: Philips
- Not relevant to this talk

Syllabus and other educational material can be found at www.jacobsonmskus.com

Note: all images from the textbook
Fundamentals of Musculoskeletal Ultrasound are copyrighted by Elsevier Inc.

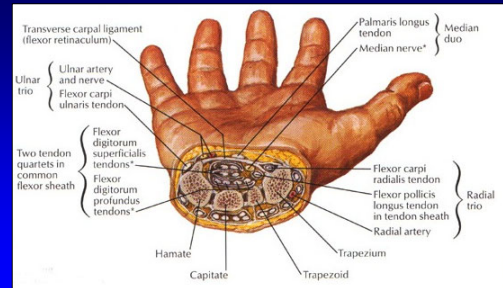
2

Introduction:

- Sonographic technique
 - Volar and dorsal: checklist of structures
 - Focused examination
 - Dynamic examination
- Transducers: 10 - 17 MHz linear

3

Volar Wrist

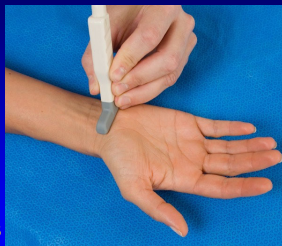

From: Netter's Atlas of Human Anatomy

4

Technique: volar

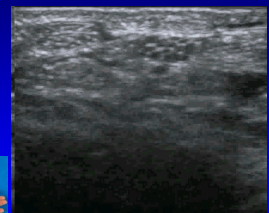
- Median nerve
- Flexor tendons
 - Flexor carpi radialis and radial artery
 - Occult ganglia
- Volar joint recesses



5

Normal Peripheral Nerve

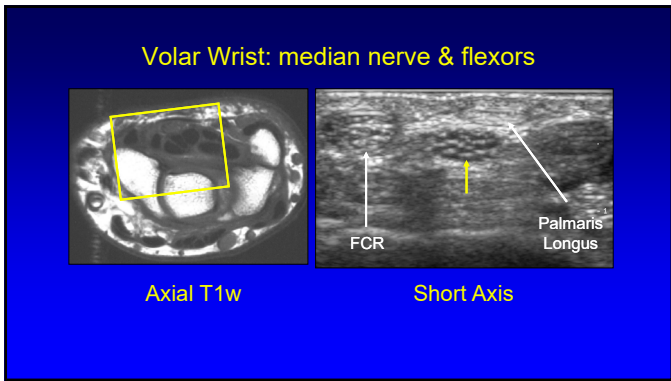
- Ultrasound appearance:
 - Hypochoic nerve fascicles
 - Hyperechoic connective tissue
- Transverse:
 - Honeycomb appearance



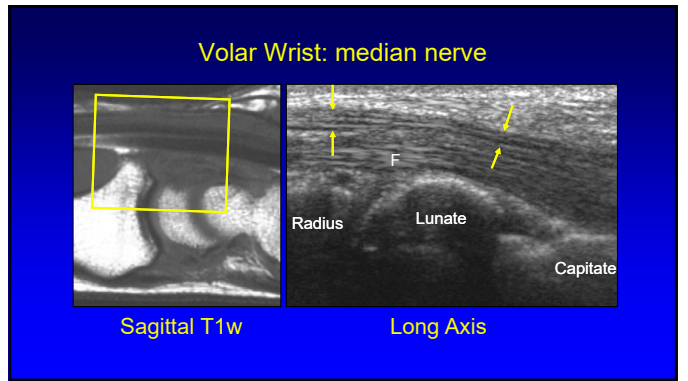
Median Nerve

Silvestri et al. Radiology 1995; 197:291

6



7



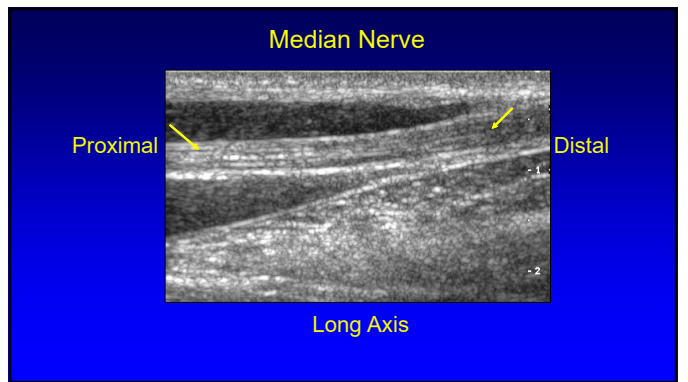
8

Median Nerve vs. Flexor Tendons

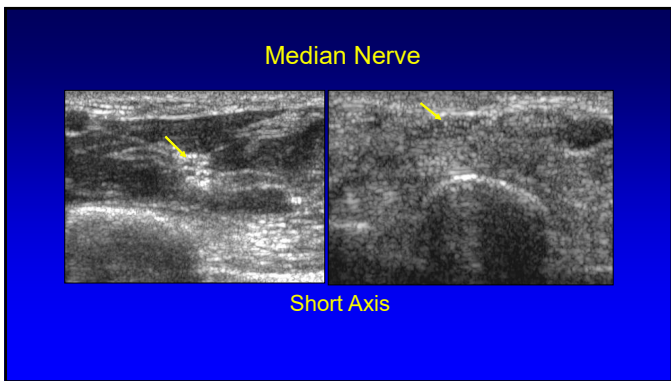
- Move transducer proximal in axial plane
- Median nerve:
 - Becomes relatively hyperechoic
 - Between flexor digitorum superficialis & profundus muscles
- Flexor tendons:
 - Become hypoechoic muscles

Silvestri et al. Radiology 1995; 197:291

9



10



11

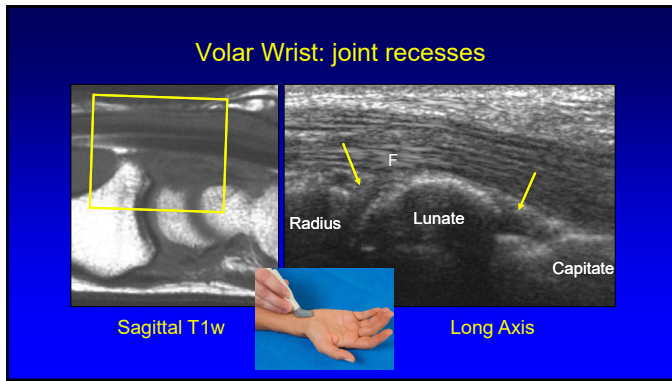
Median Nerve

- Palmar cutaneous branch
- Outside of carpal tunnel and retinaculum (white arrowheads)
- Adjacent to flexor carpi radialis

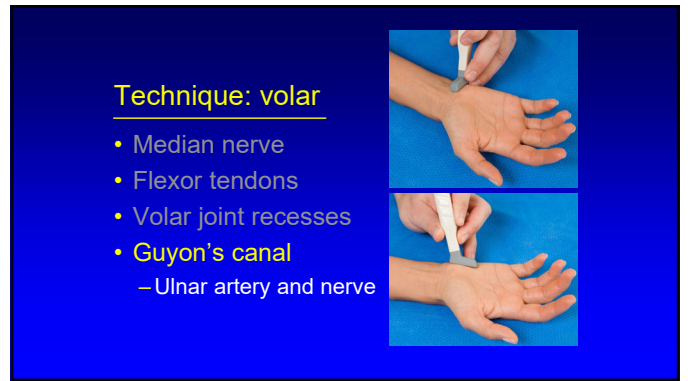
FCR MN

Tagliafico et al. AJR 2008; 197:107

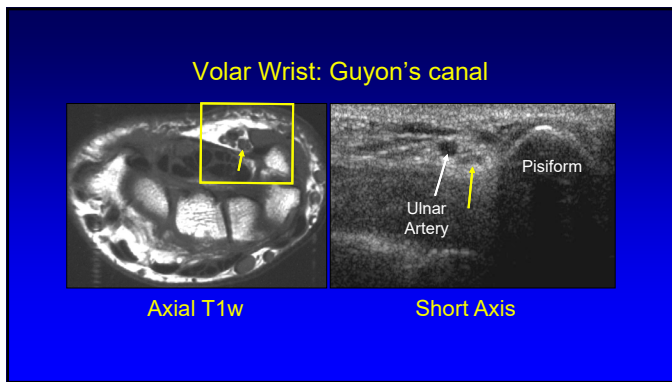
12



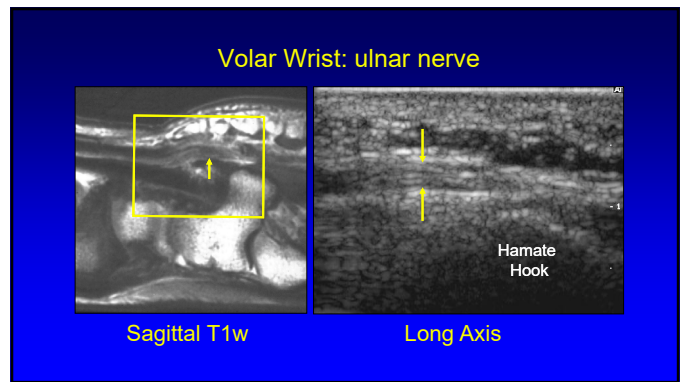
13



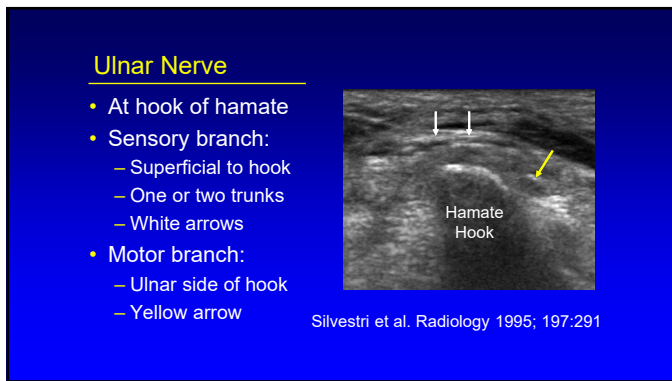
14



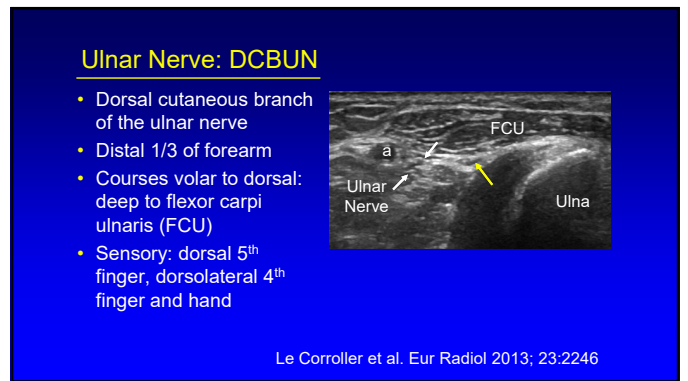
15



16



17



18

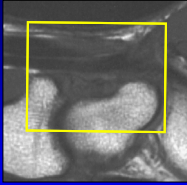
Technique: volar

- Median nerve
- Flexor tendons
- Volar joint recess
- Guyon's canal
- Scaphoid and flexor carpi radialis

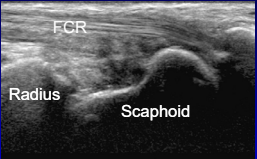


19

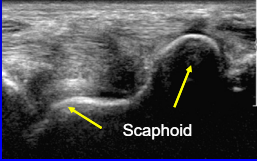
Volar Wrist: scaphoid and FCR




Sagittal T1w



FCR
Radius
Scaphoid



Scaphoid



20

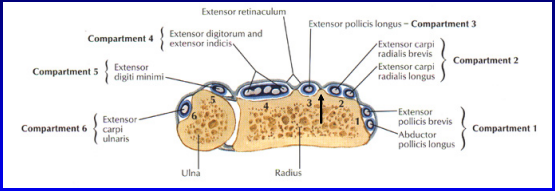
Technique: dorsal

- Extensor tendons



21

Dorsal Wrist



Extensor retinaculum

Compartment 4 { Extensor digitorum and extensor indicis }
 Compartment 5 { Extensor digiti minimi }
 Compartment 6 { Extensor carpi ulnaris }

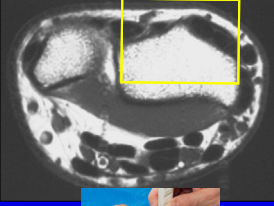
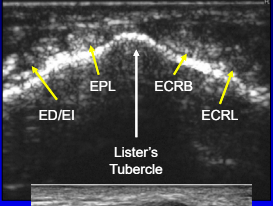
Extensor pollicis longus - Compartment 3
 Compartment 2 { Extensor carpi radialis brevis, Extensor carpi radialis longus }
 Compartment 1 { Extensor pollicis brevis, Abductor pollicis longus }

Ulna
Radius

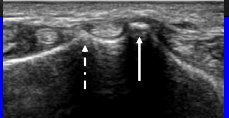

From: Netter's Atlas of Human Anatomy

22

Dorsal Wrist: extensor tendons

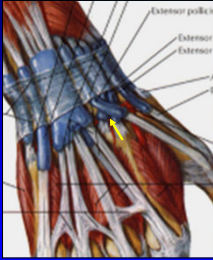




ED/EI
EPL
ECRB
ECRL
Lister's Tubercle

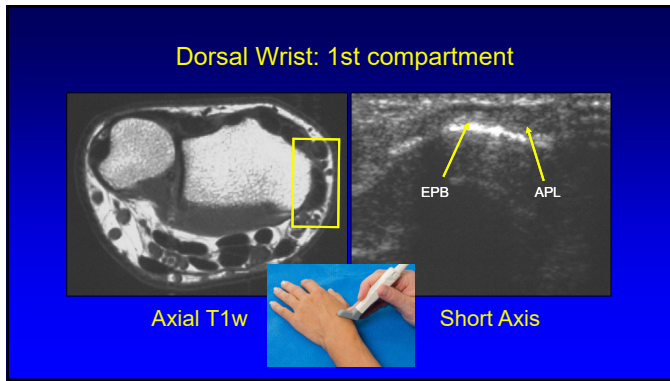
23

Dorsal Wrist: extensor pollicis longus

From: Netter's Atlas of Human Anatomy

24



25

Subcompartmentalization

- First extensor compartment
- Complete or incomplete
- 73% incidence²
- Septum:
 - US: 95% accurate¹
 - Hyperechoic
 - Anisotropy
- Indirect sign:
 - Osseous ridge¹

¹Rousset et al. Radiology 2010; 257:427
²Choi et al. Radiology 2011; 260:480

26

Multiple Tendon Fascicles

- Abductor pollicis longus
 - Incidence: 80%²
 - Up to 4 fascicles
 - US: 80% accuracy¹
- Extensor pollicis brevis
 - Incidence: 7%²
 - Up to 2 fascicles
 - US: 97% accuracy¹
- "Lotus Root Sign"²
 - Seen best distal to radius

¹Rousset et al. Radiology 2010; 257:427
²Choi et al. Radiology 2011; 260:480

27

Dorsal Wrist: 4th and 5th compartments

EDM **EDL** **EI**

Lister's Tubercle

EDM = extensor digiti minimi
Not Electronic Dance Music

28

Dorsal Wrist: 6th compartment

Axial T1w

Ulna

Note: normal hypoechoic cleft

29

Posterior Interosseous Nerve

- Dorsal surface of radius
- Deep to extensor digitorum

ED EPL ECRB/L

Lister's Tubercle

Smith J et al. J Ultrasound Med 2011; 30:1233

30

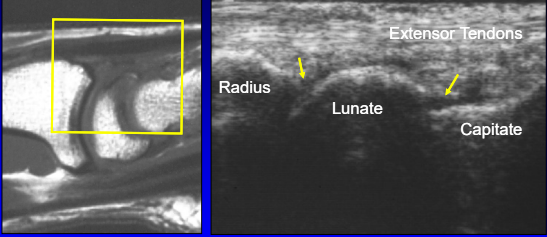
Technique: dorsal

- Extensor tendons
- Dorsal joint recesses



31

Dorsal Wrist: joint recesses




Sagittal T1w Longitudinal

32

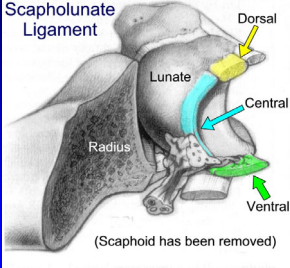
Technique: dorsal

- Extensor tendons
- Dorsal joint recesses
- Scapholunate ligament



33

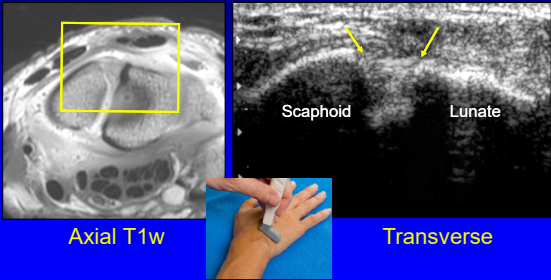
Scapholunate Ligament



From: Linkous MD, et al. Radiology 2000; 216:846

34

Dorsal Wrist: scapholunate ligament

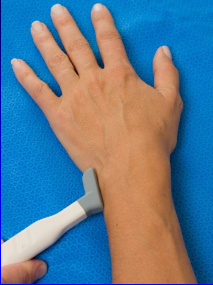


Axial T1w Transverse

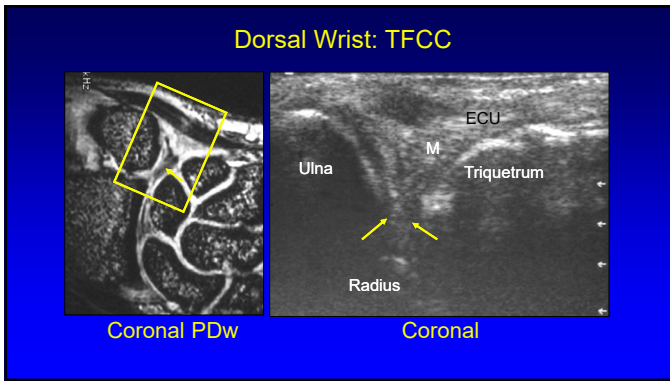
35

Technique: dorsal

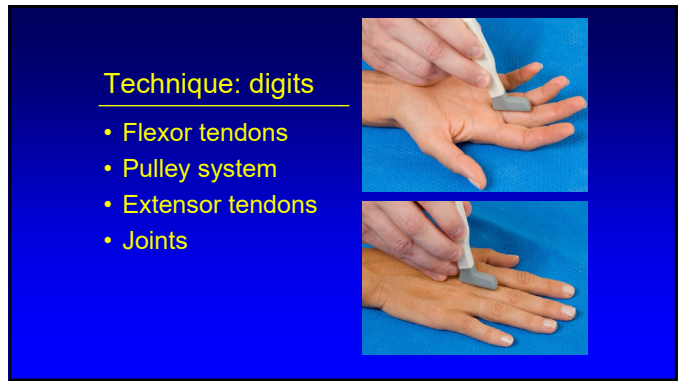- Extensor tendons
- Dorsal joint recesses
- Scapholunate ligament
- Triangular fibrocartilage complex



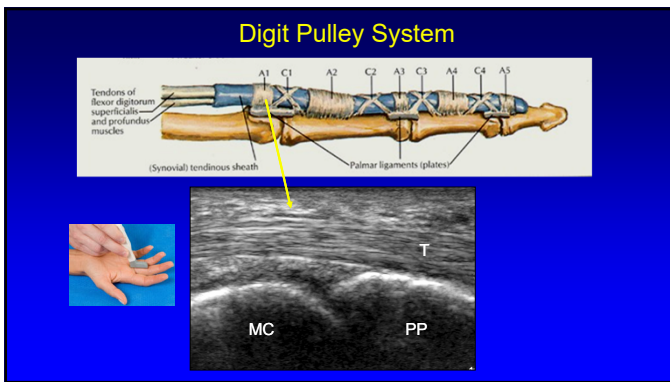
36



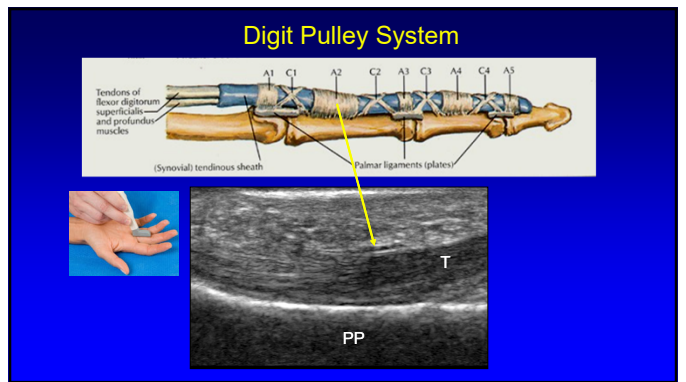
37



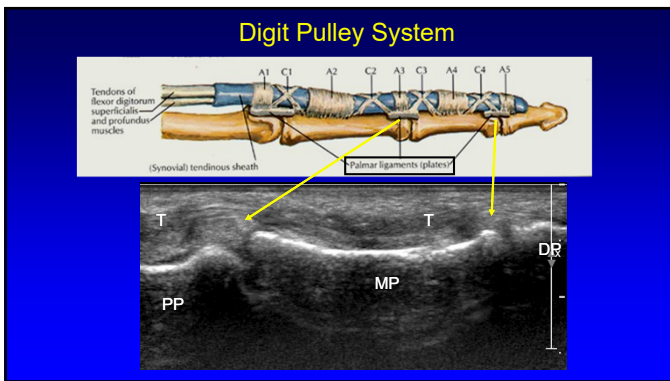
38



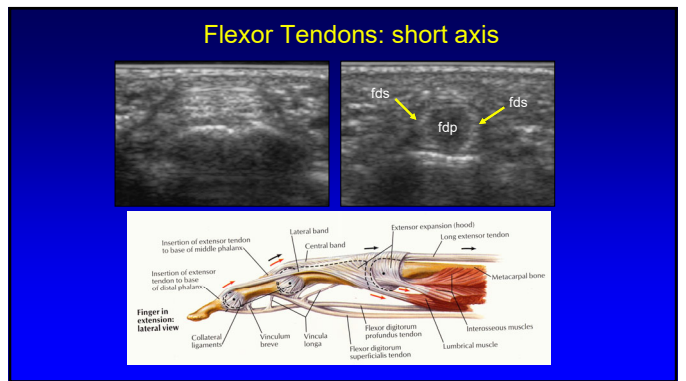
39



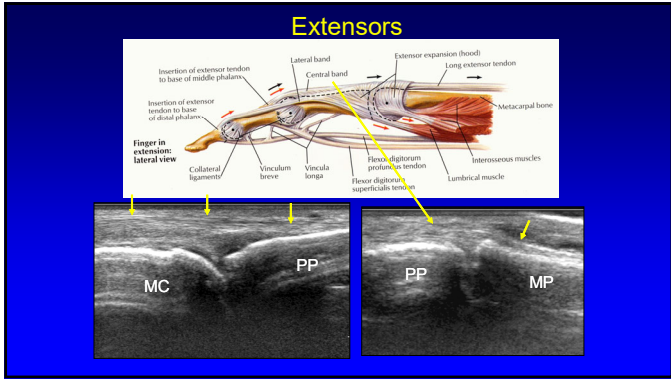
40



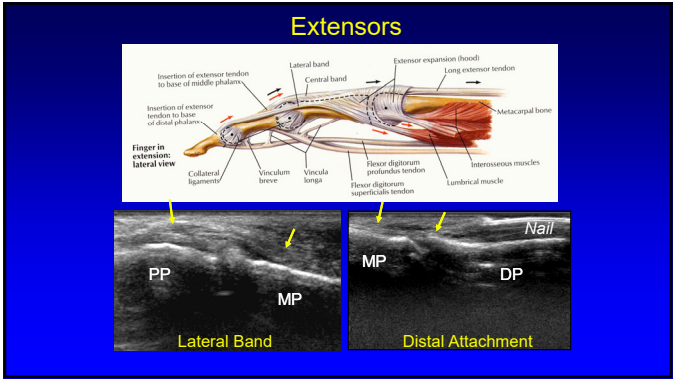
41



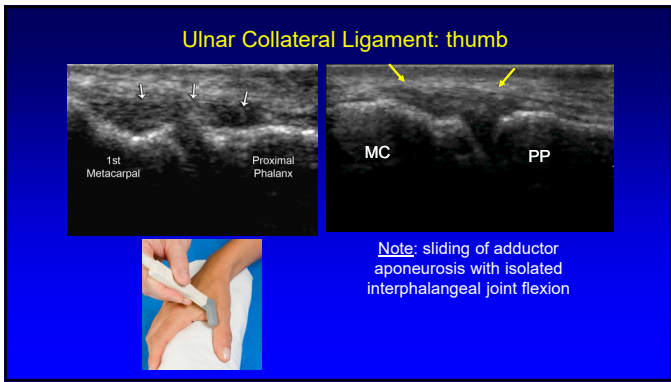
42



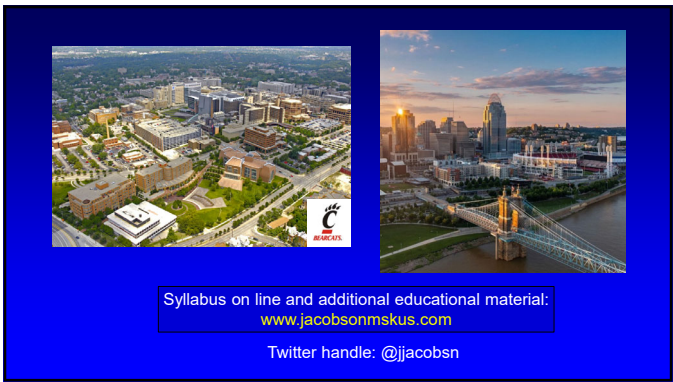43



44



45



46