

An Algorithmic Approach to Imaging of Musculoskeletal Pathology

Jon A. Jacobson, MD
FACR, FSRU, FAIUM, RMSK

Musculoskeletal Radiologist
Lenox Hill Radiology, NYC
University of California, San Diego



Syllabus PDF

1

Disclosures

- Consultant: Bioclinica
- Contractor: POCUS PRO
- Advisory Board: Philips
- Book Royalties: Elsevier
- Not relevant to this lecture

*Note: all images from the textbook
Fundamentals of Musculoskeletal Ultrasound
are copyrighted by Elsevier Inc.*

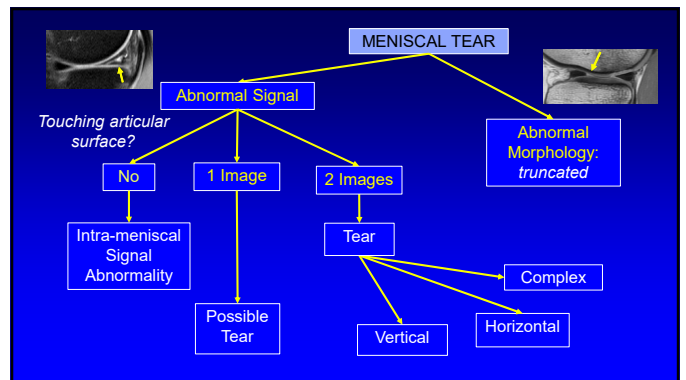
See www.jacobsonmskus.com for syllabus other educational material

2

Outline

- Meniscal tear
- Osteomyelitis
- Arthritis
- Mass
- "Cyst" on MRI
- Periostitis
- Bone marrow

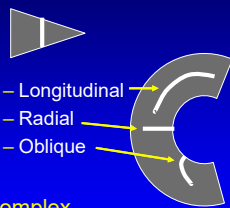
3



4

Meniscus Tear: MRI Classification

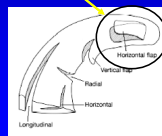
Vertical



Complex



Horizontal

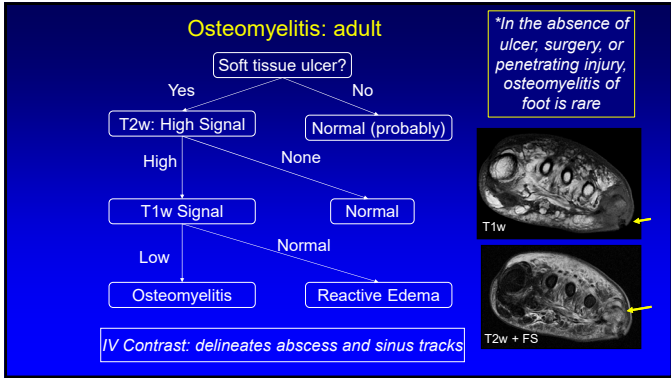


8

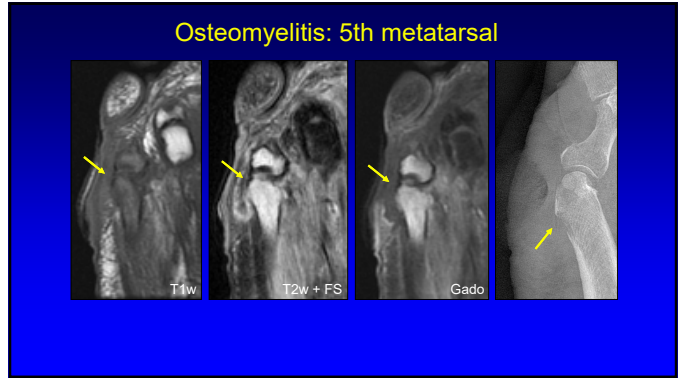
Outline

- Meniscal tear
- **Osteomyelitis**
- Arthritis
- Mass
- "Cyst" on MRI
- Periostitis
- Bone marrow

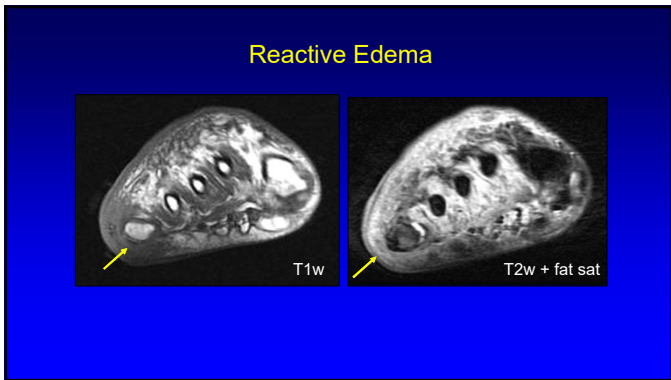
19



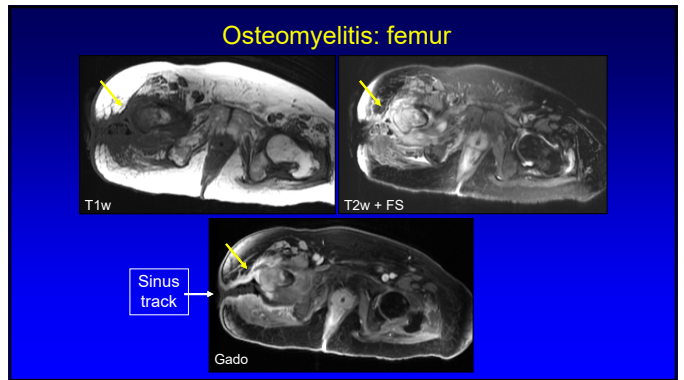
20



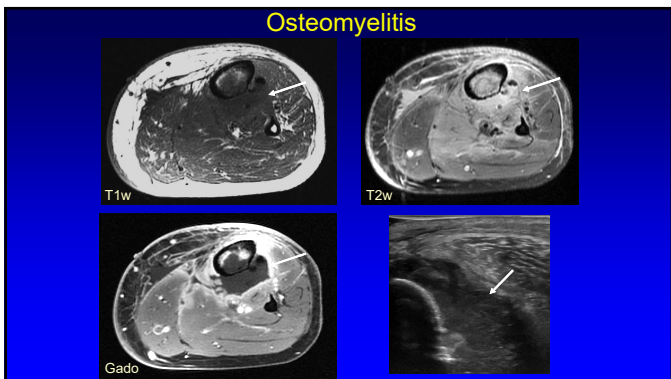
21



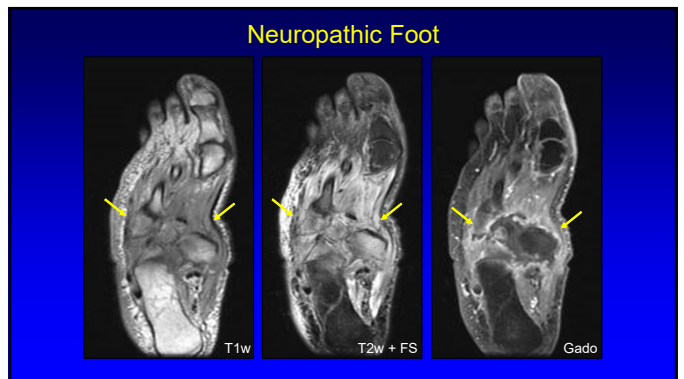
22



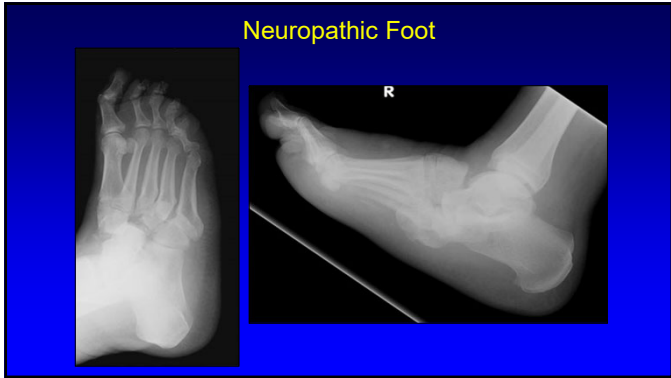
23



24



25

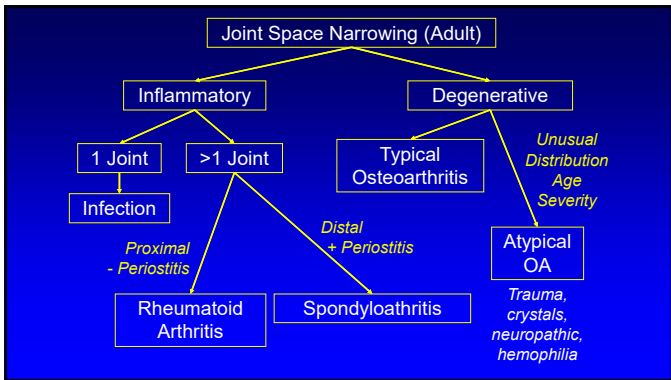


28

Outline

- Meniscal tear
- Osteomyelitis
- **Arthritis**
- Mass
- "Cyst" on MRI
- Periostitis
- Bone marrow

29



30

Inflammatory Arthritis

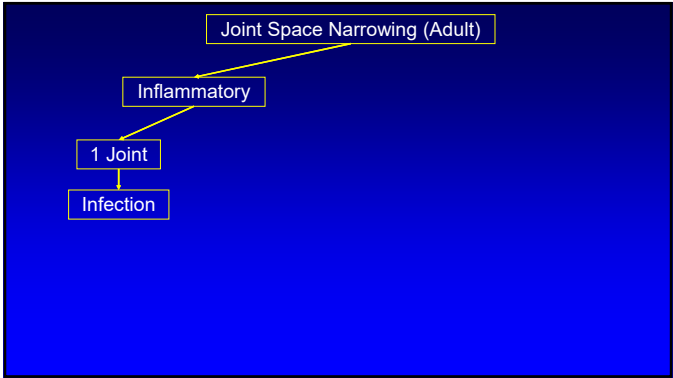
- Periarticular osteopenia
- Soft tissue swelling
- **Erosions:**
 - Initially marginal
 - Cortex discontinuous
- Joint space narrowing: **uniform**

32

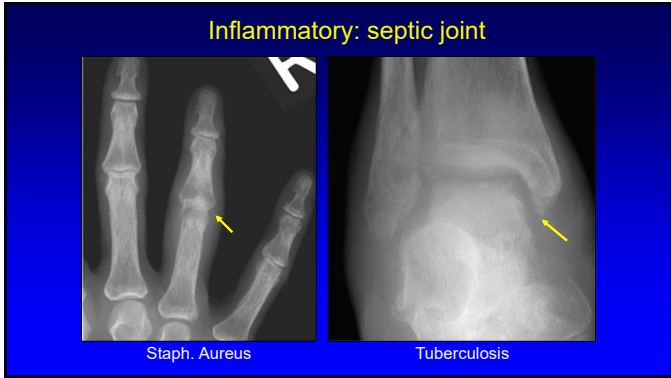
Degenerative Arthritis:

- Joint space narrowing: not uniform
- Normal mineralization
- Osteophytes
- Sclerosis and eburnation

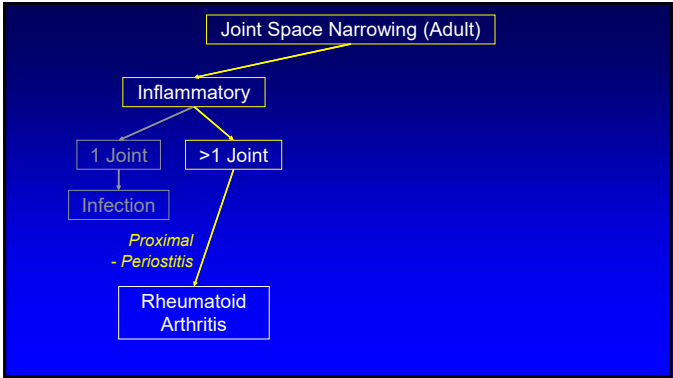
34



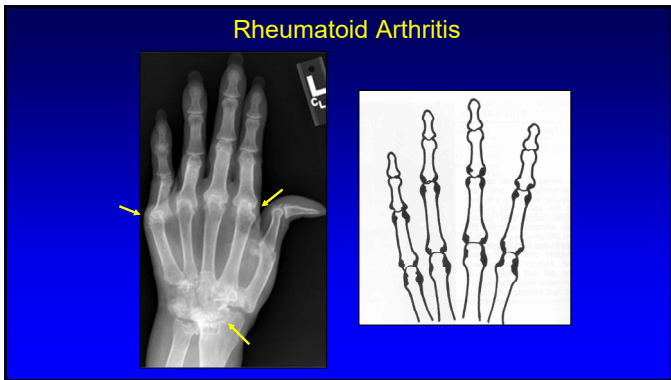
35



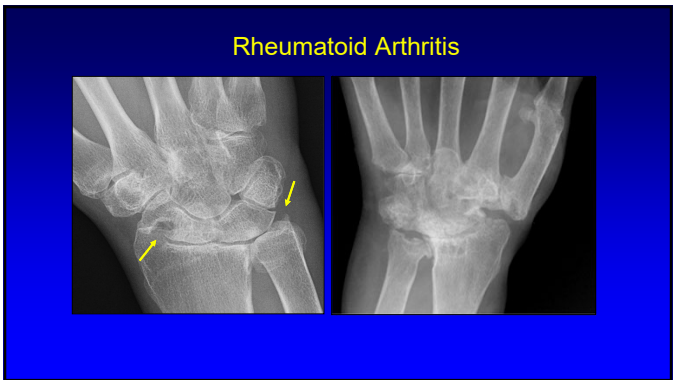
36



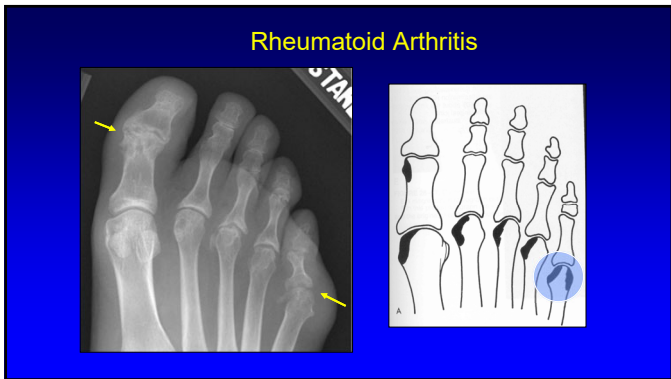
37



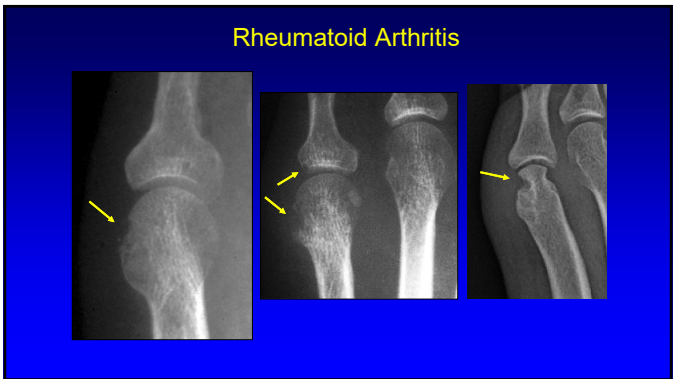
38



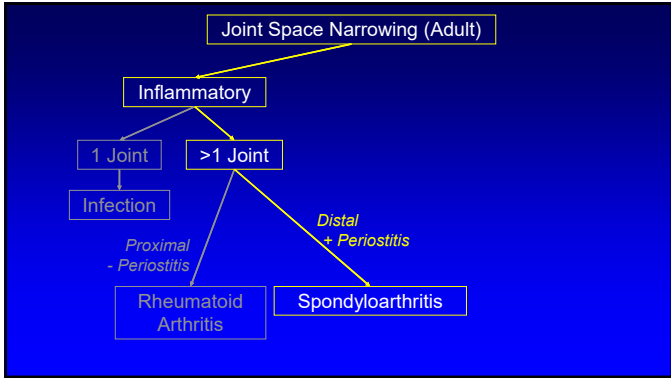
39



40



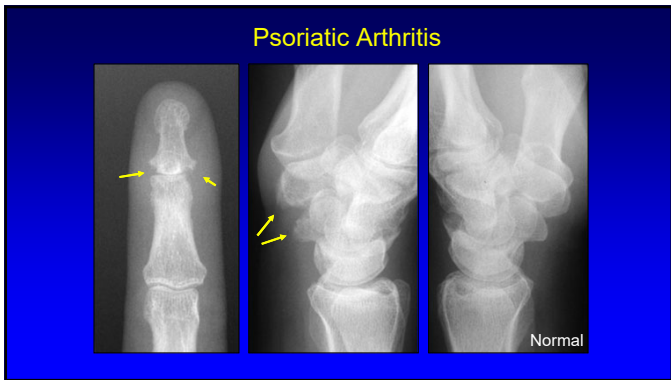
41



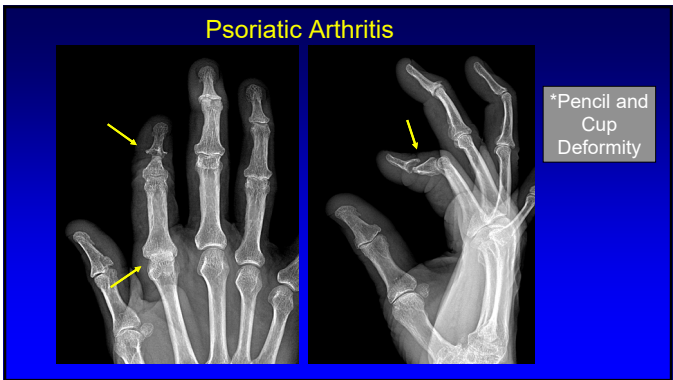
42

- Spondyloarthritis:**
- Synovial joints:
 - Erosions, uniform joint space narrowing
 - Periostitis
 - Cartilaginous joints: erosions
 - Enteses:
 - Tendon and ligament attachment
 - Fluffy enthesophytes, erosions

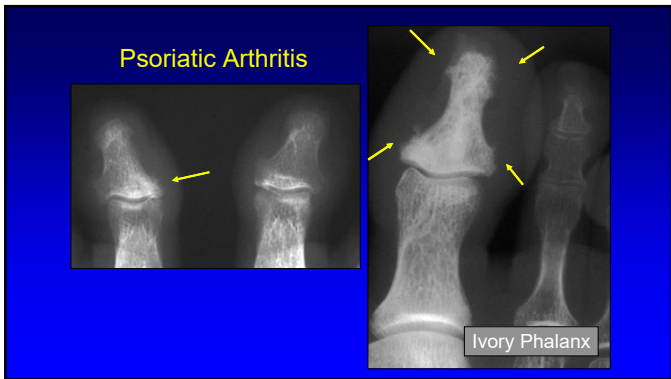
43



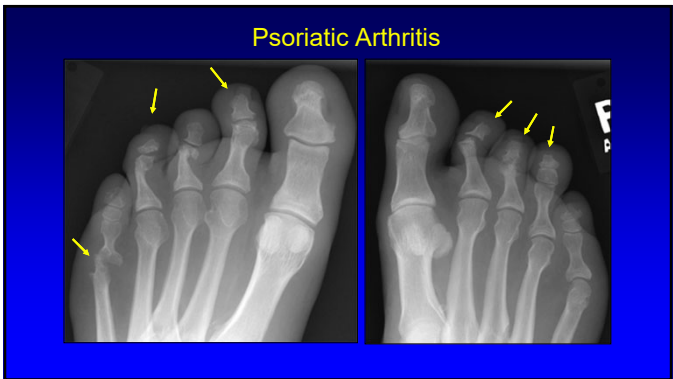
45



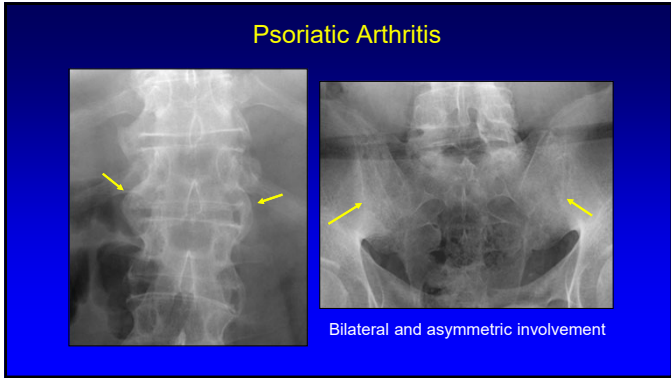
46



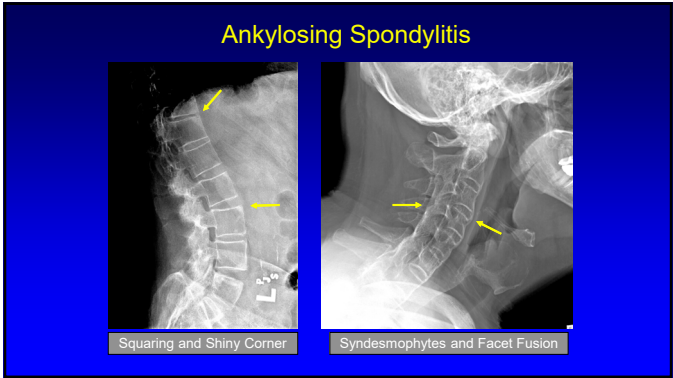
47



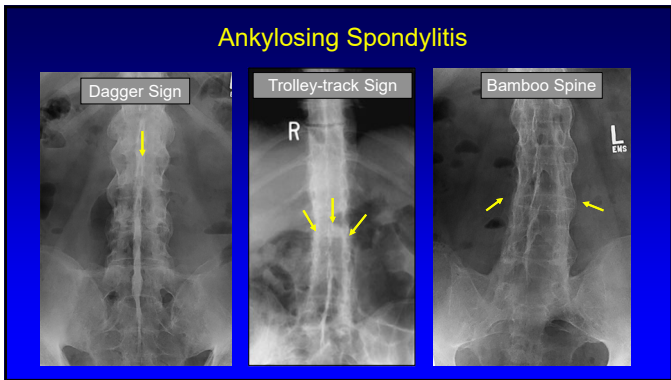
48



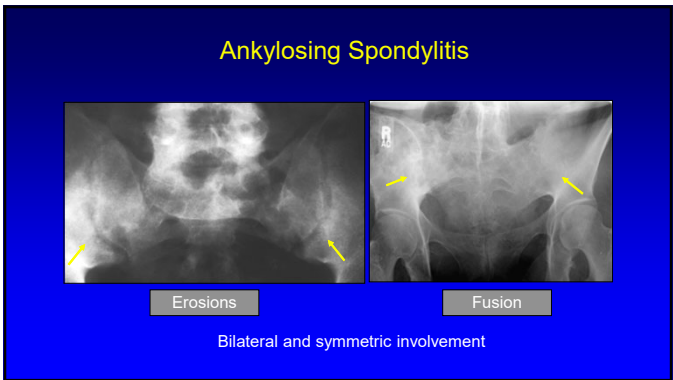
49



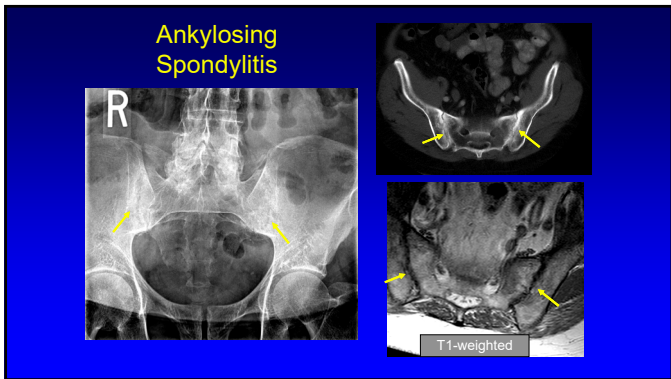
50



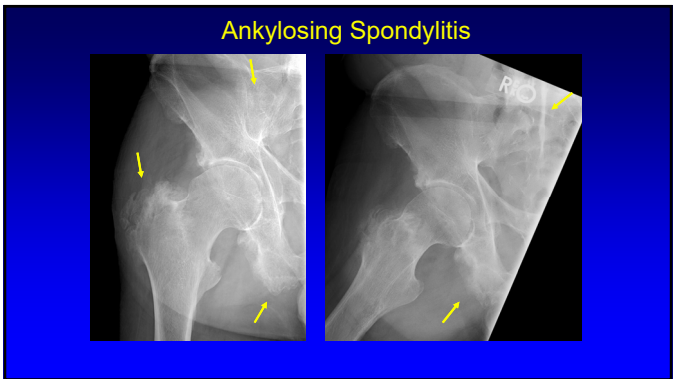
51



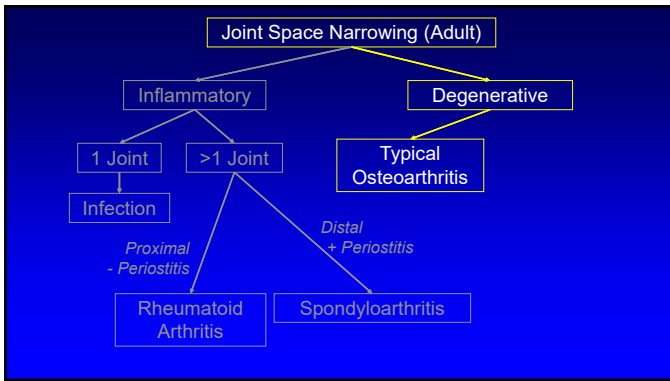
52



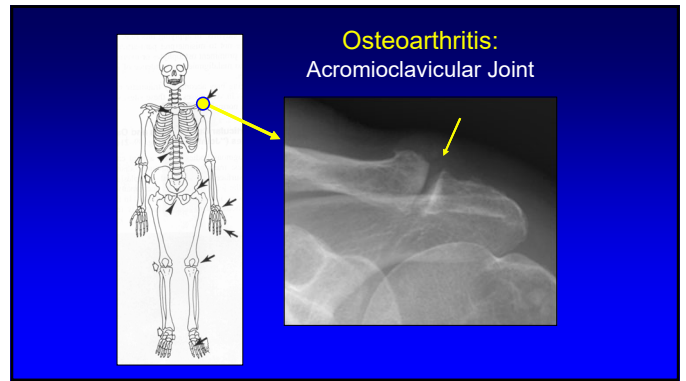
53



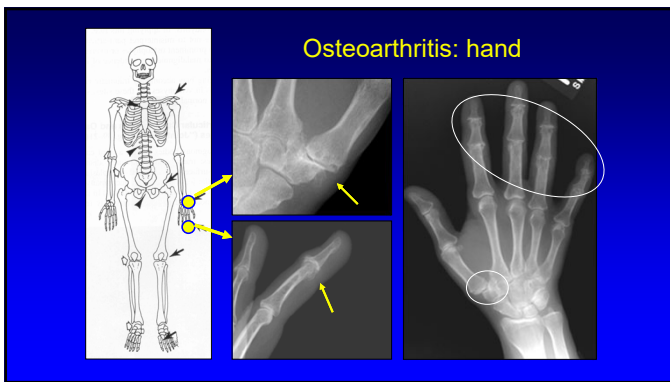
54



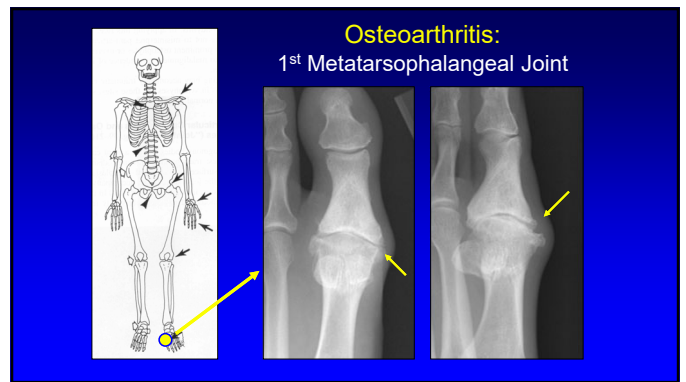
55



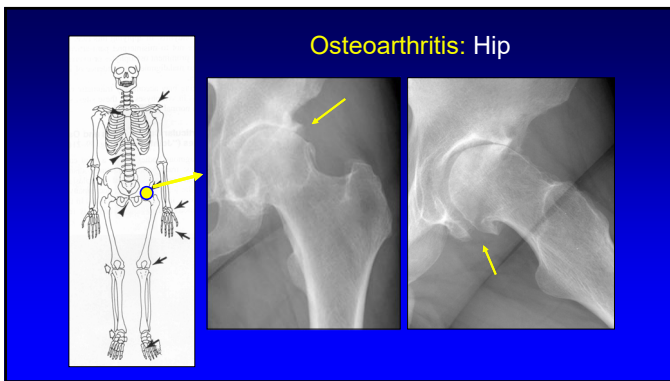
56



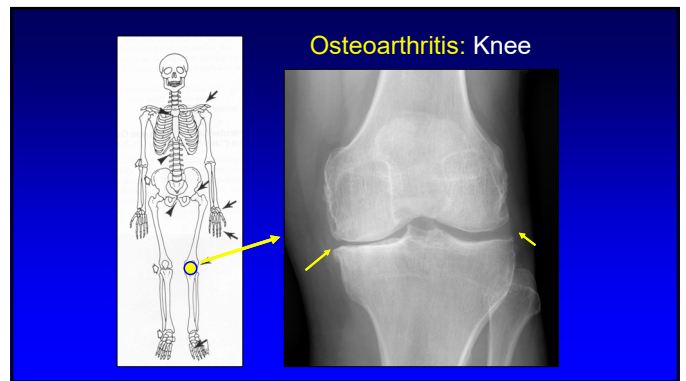
57



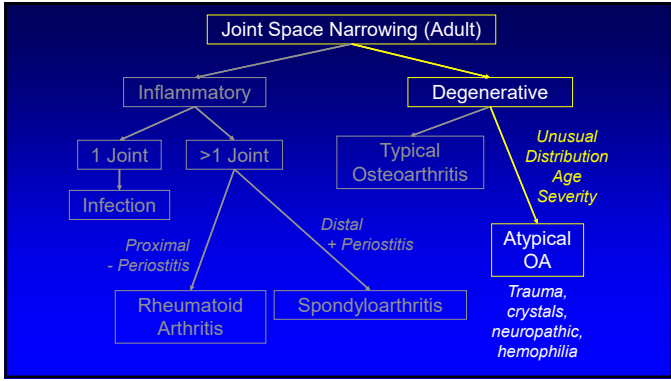
58



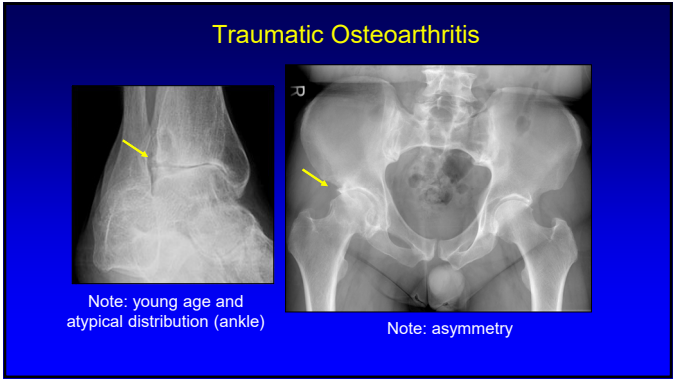
59



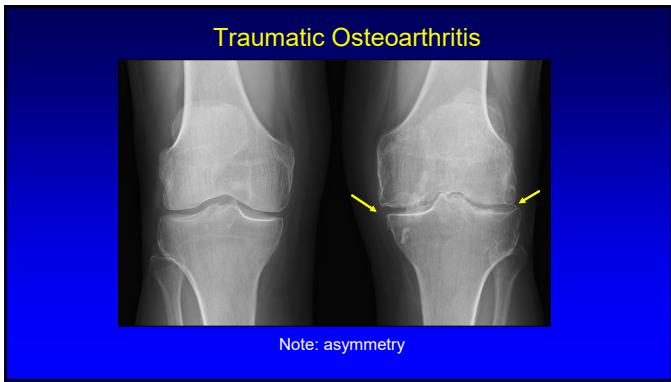
60



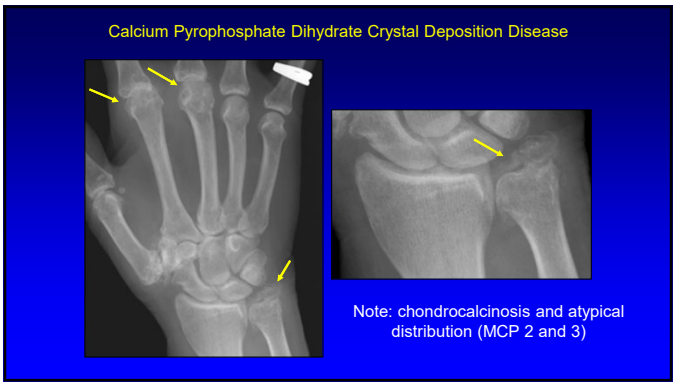
61



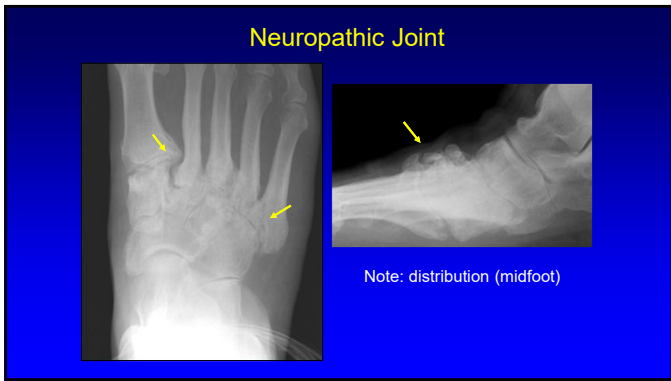
62



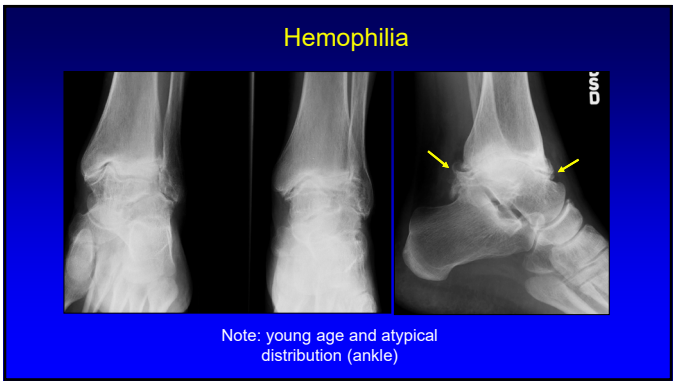
63



64



65



66

Outline

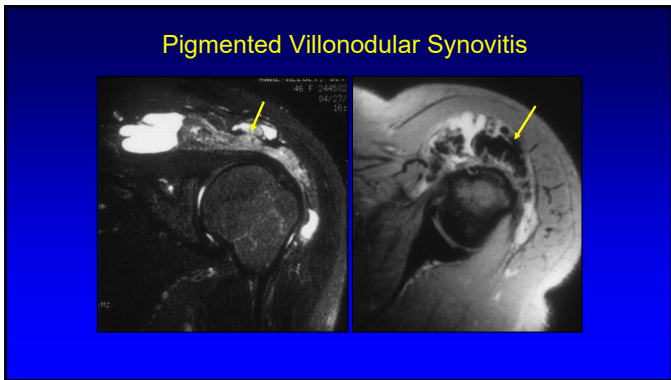
- Meniscal tear
- Osteomyelitis
- Arthritis
- **Mass**
- "Cyst" on MRI
- Periostitis
- Bone marrow

67

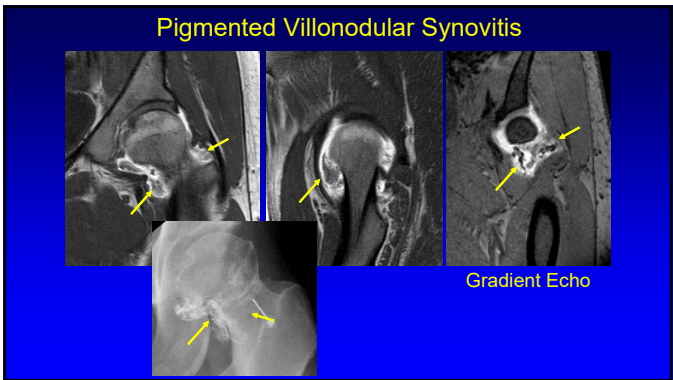
Mass Algorithm

Bone	Synovial Space <small>Joint, bursa, tendon sheath</small>	Other
<ul style="list-style-type: none"> • > 40 years old ✓ Mets ✓ Myeloma • Primary tumor • Infection 	<ul style="list-style-type: none"> • Inflammatory <ul style="list-style-type: none"> ✓ Rheumatoid ✓ TB, fungal • Proliferative <ul style="list-style-type: none"> ✓ PVNS ✓ Synovial chondromatosis ✓ Amyloid ✓ Hemophilia 	<ul style="list-style-type: none"> • Sarcoma • Lymphoma • Met • Infection

68



69

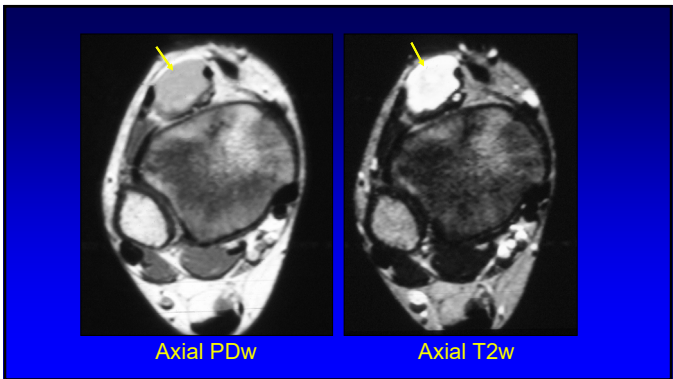


70

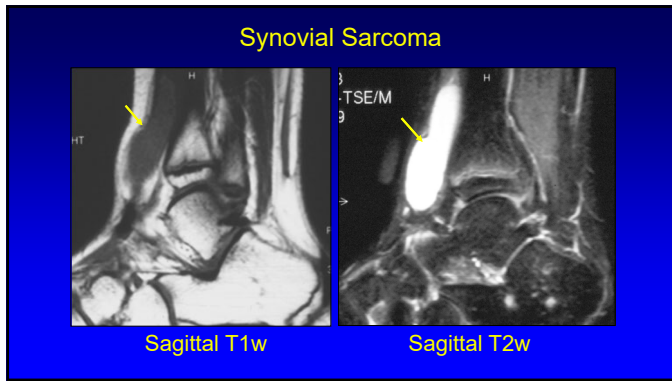
Outline

- Meniscal tear
- Osteomyelitis
- Arthritis
- Mass
- "Cyst" on MRI
- Periostitis
- Bone marrow

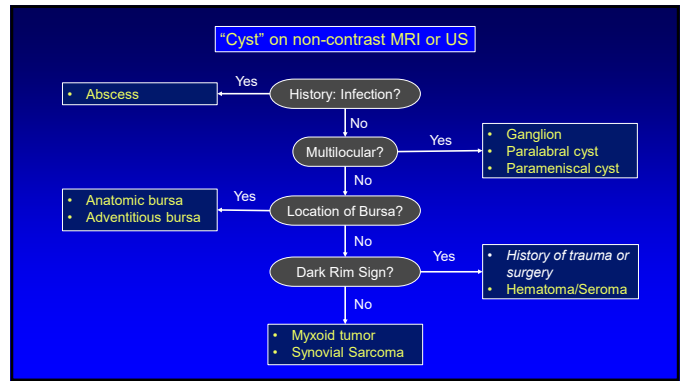
71



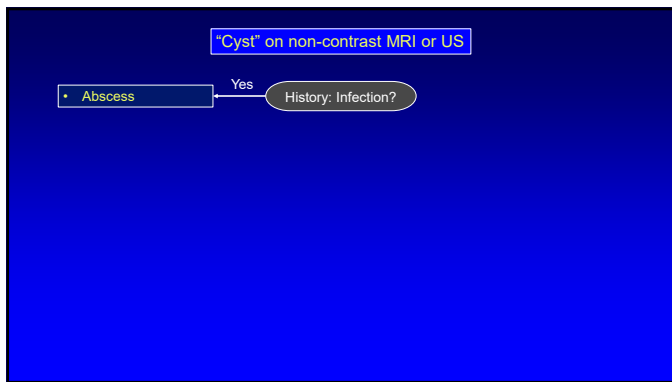
72



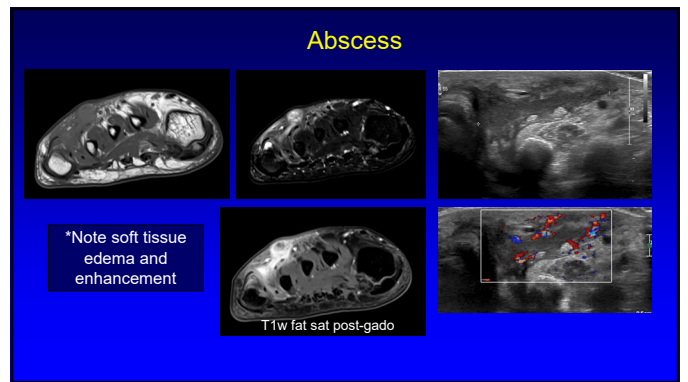
73



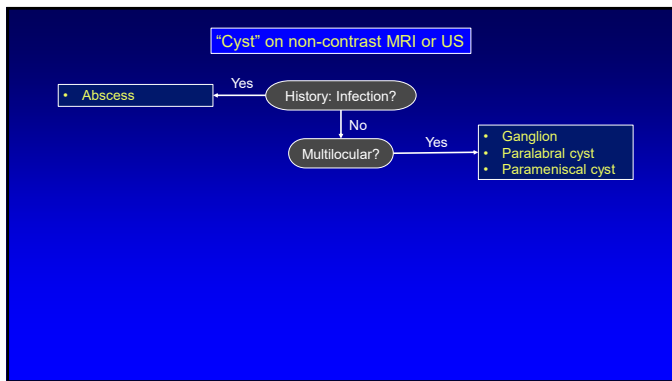
74



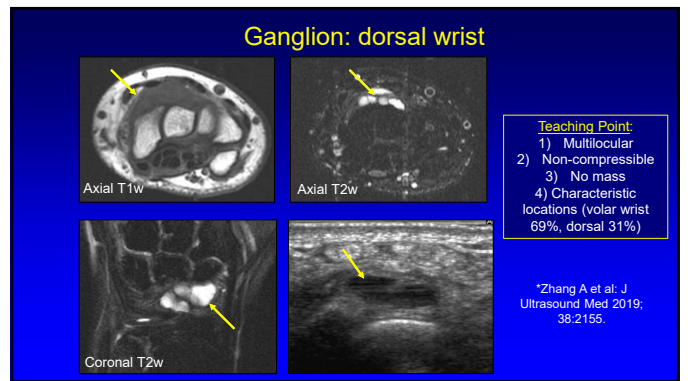
75



76



77



78

Ganglion: volar wrist

Radial Artery
Flexor Carpi Radialis
Radius
RPL/EPB

Teaching Point:
1) Multilocular, 2) Non-compressible, 3) No mass, 4) Characteristic locations (volar wrist 69%, dorsal 31%)

*Zhang A et al. J Ultrasound Med 2019; 38:2155.

79

Ganglion: gastrocnemius

Femur

Teaching Point:
1) Multilocular, 2) Non-compressible, 3) Characteristic locations (gastrocnemius, cruciate, Hoffa)

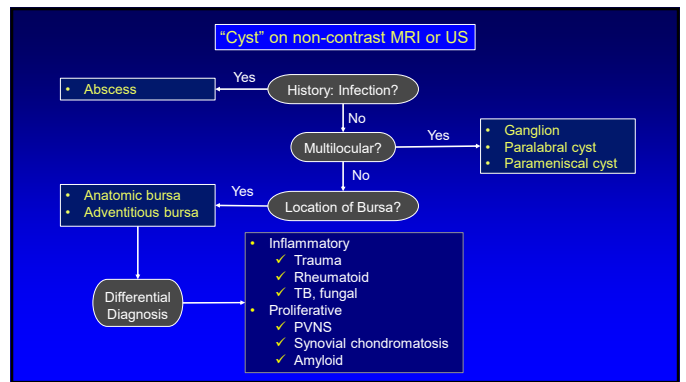
80

Medial Meniscus: tear and parameniscal cyst

Femur Tibia

Teaching Point:
1) Multilocular
2) Non-compressible
3) Associated horizontal meniscal tear

81



82

Knee Bursae

*Suprapatellar Recess
Prepatellar Bursa
Deep Infrapatellar Bursa
Superficial Infrapatellar Bursa
Baker Cyst
Semimembranosus-Tibial Collateral Ligament Bursa
Pes Anserinus Bursa

Ruangchajaturorn T et al. Skeletal Radiol 2017;46:445.

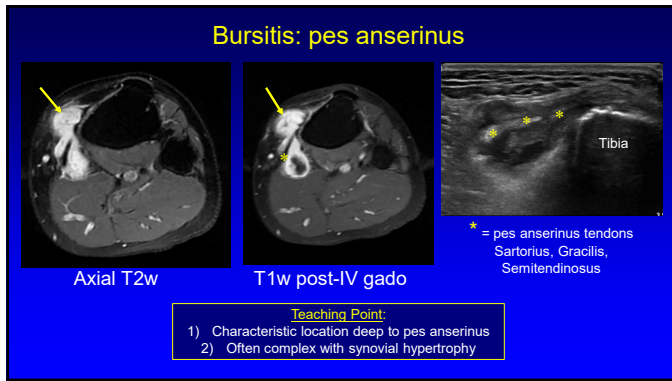
83

Pes Anserinus Bursitis

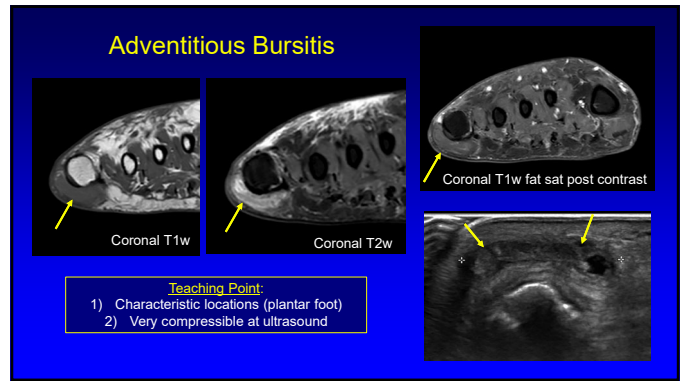
Coronal T2w
T1w post-IV gado

- Inflammatory
 - ✓ Trauma
 - ✓ Rheumatoid
 - ✓ TB, fungal
- Proliferative
 - ✓ PVNS
 - ✓ Synovial chondromatosis
 - ✓ Amyloid

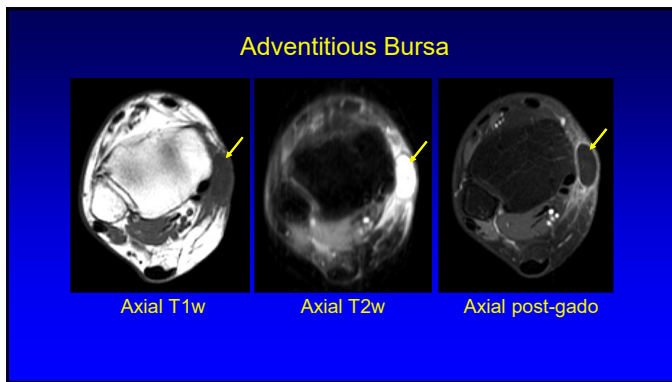
84



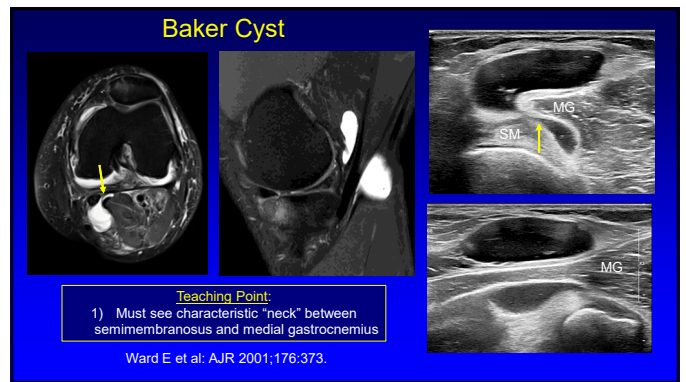
85



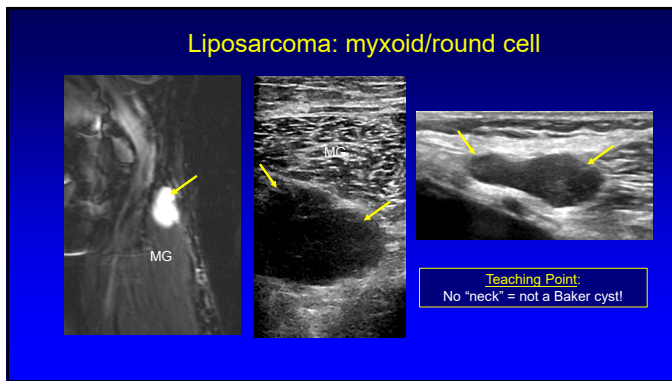
86



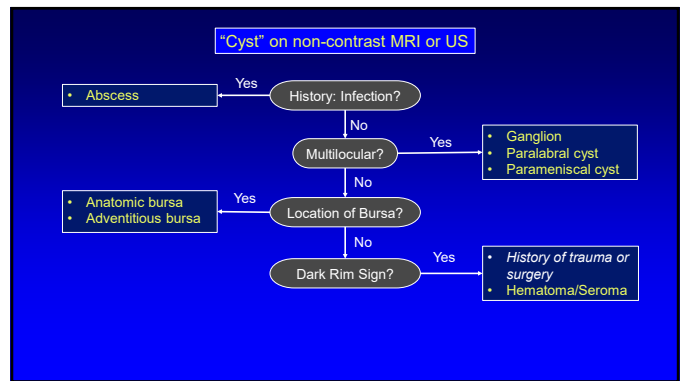
87



88



89



90

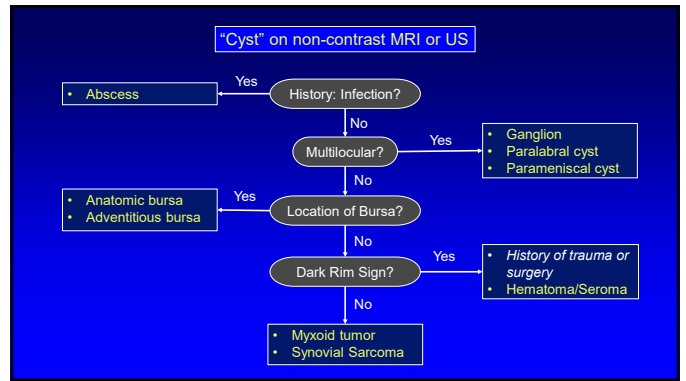
Seroma

Teaching Point:

- 1) Low signal rim from hemosiderin
- 2) High T1w signal on fat-sat with no internal enhancement
- 3) Mural nodules are okay

Lantos JE et al: AJR 2014;202:1297.

91



92

Intramuscular Myxoma

Teaching Point:

- 1) Low T1 signal and variable enhancement
- 2) US: increased through transmission
- 3) Location (thigh)

93

Liposarcoma: myxoid/round cell

Teaching Point:

- 1) Fat signal <10% of area
- 2) T1w signal equal to muscle
- 3) Variable enhancement

*Murphey MD et al: Radiographics 2005; 25:1371

94

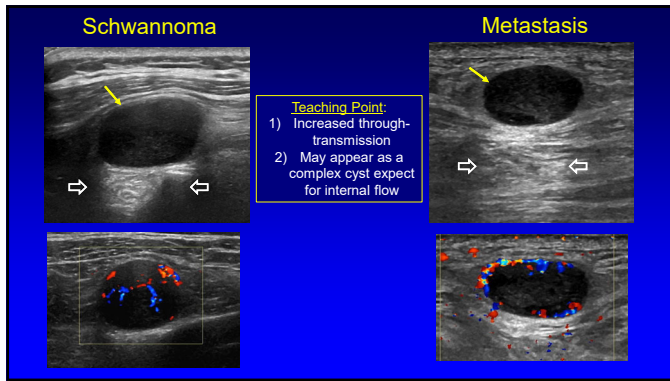
96

Synovial Sarcoma

Teaching Point:

- 1) T1w signal not lower than muscle
- 2) Not a bursal location
- 3) Enhancement and flow

97

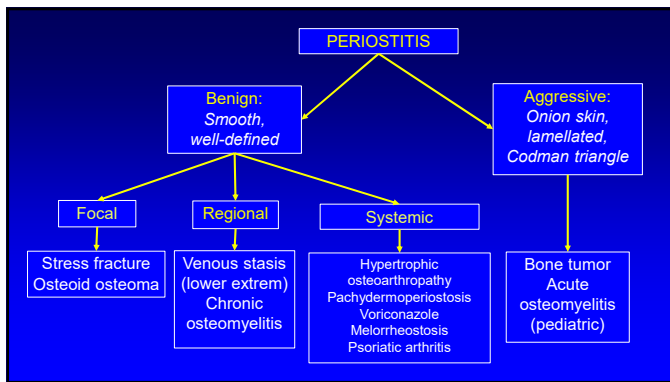


98

Outline

- Meniscal tear
- Osteomyelitis
- Arthritis
- Mass
- "Cyst" on MRI
- **Periostitis**
- Bone marrow

99

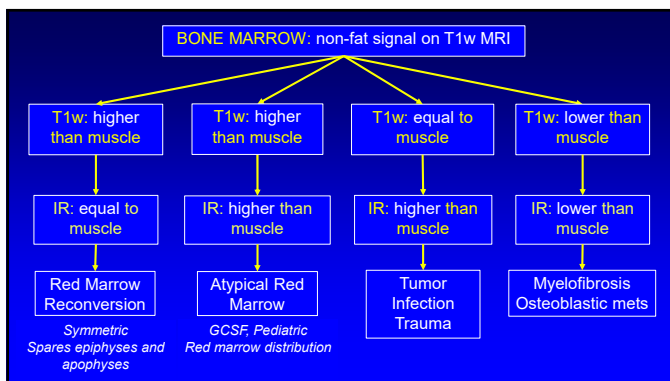


100

Outline

- Meniscal tear
- Osteomyelitis
- Arthritis
- Mass
- "Cyst" on MRI
- Periostitis
- **Bone marrow**

111



112

Thank you!

NYC Ann Arbor San Diego

Syllabus on line and other educational material:
www.jacobsonmskus.com

Twitter handle: @jjacobsn

127