

Ultrasound of the Groin and Hip: Top 3 Tips

Jon A. Jacobson, M.D.
Ann Arbor, Michigan, USA

1

Disclosures

- Consultant: Bioclinica
- Book Royalties: Elsevier
- Contractor: POCUS PRO
- Advisory Board: Philips
- Not relevant to this talk

Syllabus and other educational material can be found at www.jacobsonmskus.com

Note: all images from the textbook *Fundamentals of Musculoskeletal Ultrasound* are copyrighted by Elsevier Inc.

2

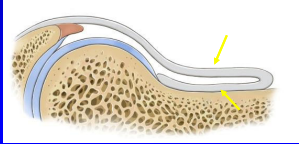
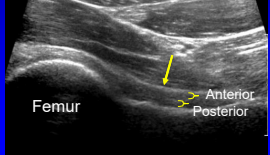
Hip and Groin: Top Tips

1. Anterior hip capsule anatomy
"It's not synovitis"
2. Trochanteric anatomy and related pathology
"It's not bursitis"
3. Iliopsoas anatomy and snapping etiology
"It is actually the psoas major tendon and iliacus"

3

Hip: anterior recess

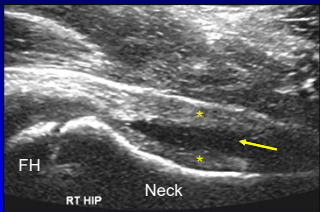

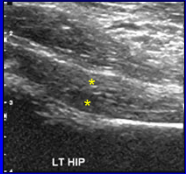
- Anterior and posterior layers
 - Fibrous tissue + minute layer of synovium
 - Hyperechoic
 - Each 2 - 4 mm thick

Radiology 1999; 210:499

4

Hip Joint: septic effusion

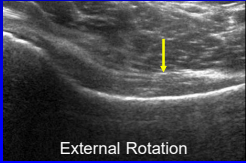
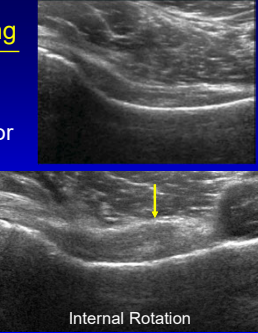




- Separation of anterior and posterior layers¹
- Capsule distention at femoral neck > 7 mm or difference of 1 mm from opposite side²

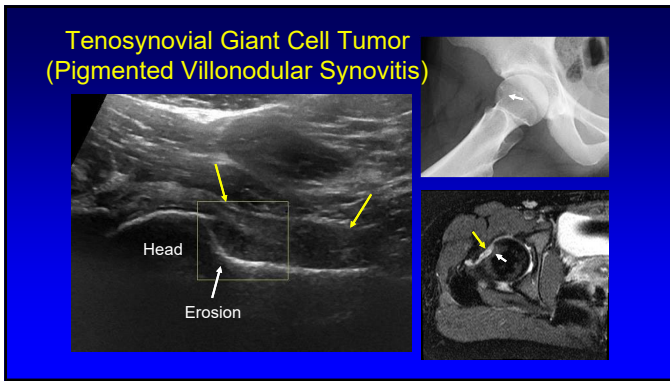
5

Pitfall: capsule thickening

- Internal rotation of hip:
 - Anterior hip capsule
 - Thicker, convex anterior

6



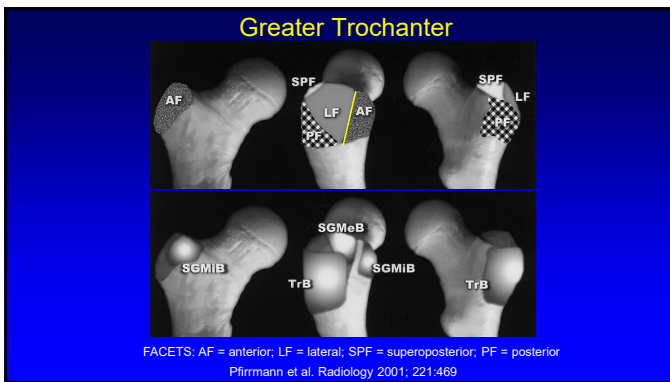
7

Trochanteric Pain Syndrome

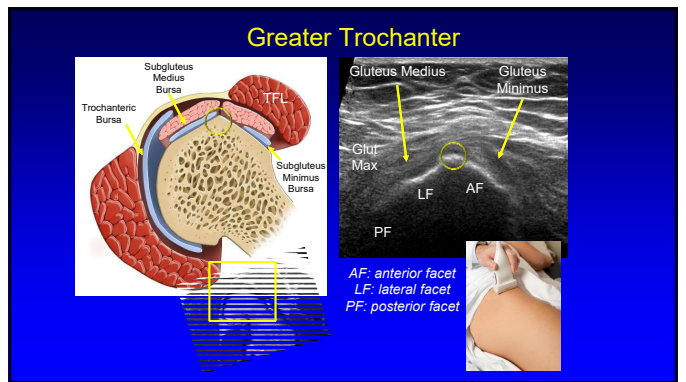
- Trochanteric bursitis: uncommon
 - 20% of symptomatic patients¹
 - Not actually inflamed²
 - Not associated with pain³
- Most commonly caused by gluteus minimus and medius tendon abnormalities⁴

¹Long SS et al. AJR 2013; 201:1083
²Clin Rheumatol 2008; 14:82
³Skeletal Radiol 2008; 37:903
⁴Eur Rad 2007; 17:1772

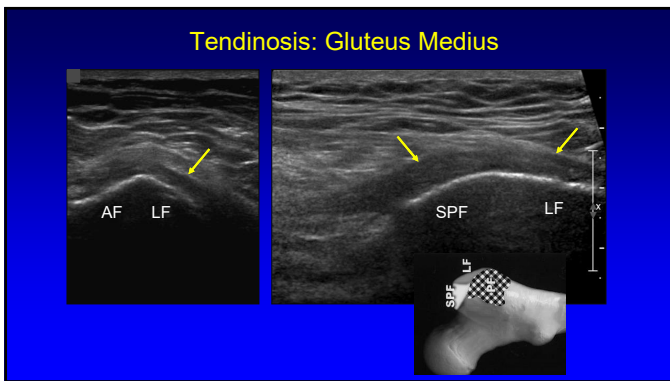
8



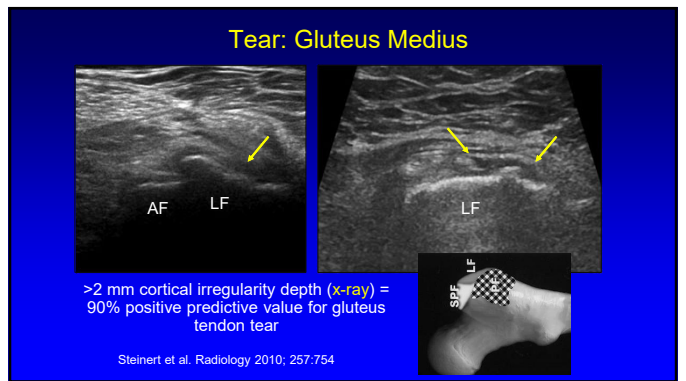
9



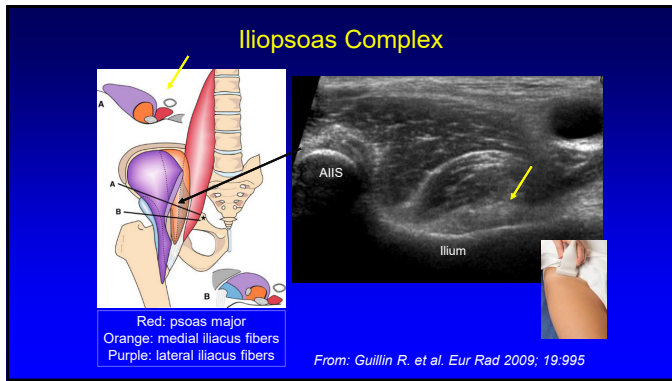
10



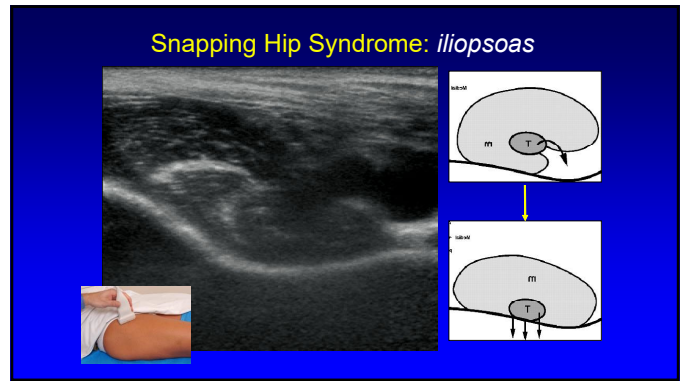
11



12



13



14

- ### Hip and Groin: Top Tips
1. Anterior hip capsule anatomy
"It's not synovitis"
 2. Trochanteric anatomy and related pathology
"It's not bursitis"
 3. Iliopsoas anatomy and snapping etiology
"It is the psoas major tendon and iliacus"

15

Thank you!

Syllabus on line and other educational material:
www.jacobsonmskus.com
Twitter handle: @jjacobsn

16