

# Ultrasound of Soft Tissue Masses

Jon A. Jacobson, MD  
FACR, FSRU, FAIUM, RMSK

Professor of Radiology  
Lenox Hill Radiology, NYC  
University of California, San Diego

1

## Disclosures

- Consultant: Bioclinica
- Advisory Board: Philips
- Book Royalties: Elsevier
- Not relevant to this lecture

*Note: all images from the textbook  
Fundamentals of Musculoskeletal Ultrasound are  
copyrighted by Elsevier Inc.*

See [www.jacobsonmskus.com](http://www.jacobsonmskus.com) for syllabus other educational material

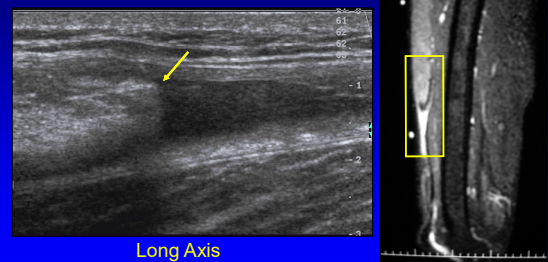
2

## Question: tumor or pseudotumor?

- Pseudotumors:
  - Tendon tear with retraction:
    - Rectus femoris, tibialis anterior
  - Muscle hernia
  - Anomalous muscle:
    - Accessory soleus
    - Extensor digitorum brevis manus
  - Rheumatoid nodule

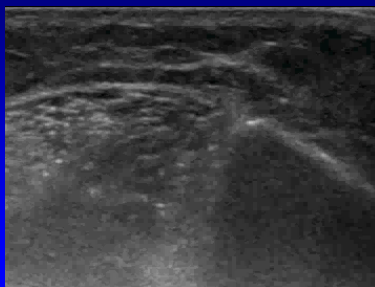3

## Rectus Femoris Tear: full tear, pseudomass



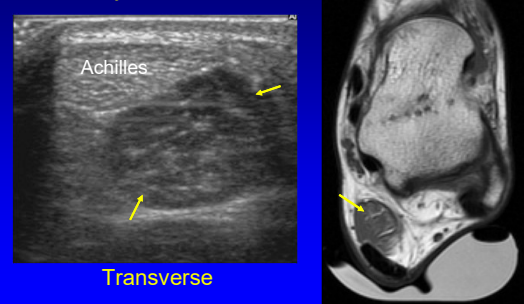
4

## Muscle Hernia: anterior tibialis



5

## Accessory Soleus Muscle



6

### Question: anatomic location?

- Joint, tendon sheath, or bursal origin
  - Synovial: benign
- Tendon
  - Gout
- Osseous origin
  - Aggressive: infection or malignancy
- Soft tissue origin
  - Variable etiology

7

### Outline:

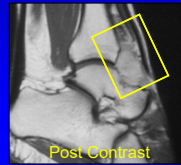
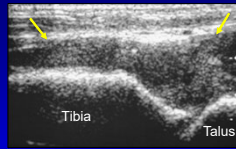
- Joint recess
- Bursa
- Tendon
- Lymph Node
- Ganglion
- Subcutaneous
- Other

8

### Joint Recess

- Mass arising from a joint is a benign synovial process:
  - Rheumatoid arthritis
  - Tenosynovial giant cell tumor (pigmented villonodular synovitis)
- Synovial sarcoma: very rarely involves a joint

Tenosynovial Giant Cell Tumor



9

### Outline:

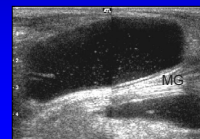
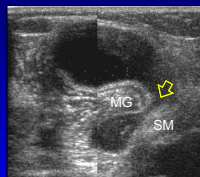
- Joint recess
- Bursa
- Tendon
- Lymph Node
- Ganglion
- Subcutaneous
- Other

10

### Bursa

- Mass arising from a bursa
  - Benign synovial process
  - Know locations of normal bursa
  - Anechoic or hypoechoic
  - Compressible
  - May be complex
  - Example: Popliteal (Baker) cyst

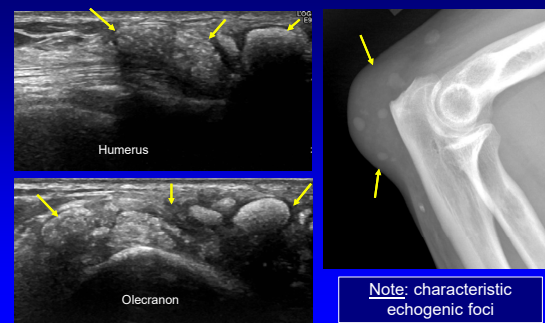
Popliteal Cyst



Note: characteristic "neck" between MG and SM tendons (yellow arrow)

11

Gout: olecranon bursa



Note: characteristic echogenic foci

12

### Outline:

- Joint recess
- Bursa
- Tendon
- Lymph Node
- Ganglion
- Subcutaneous
- Other

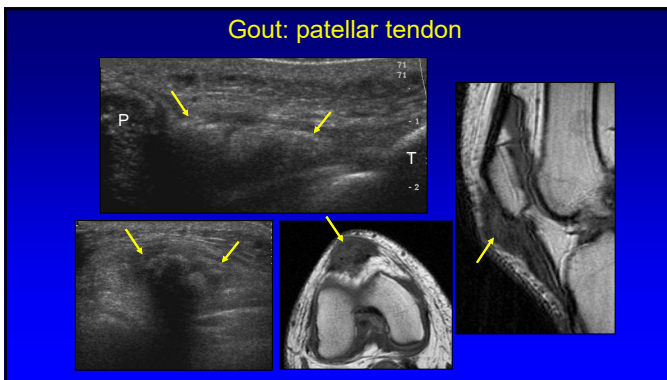
13

### Tendon

- Gout
  - Popliteus tendon: knee
  - Patellar tendon
  - Quadriceps tendon
- Tenosynovial giant cell tumor
- Pseudotumor:
  - Tendon tear and retraction
  - Rectus femoris, tibialis anterior

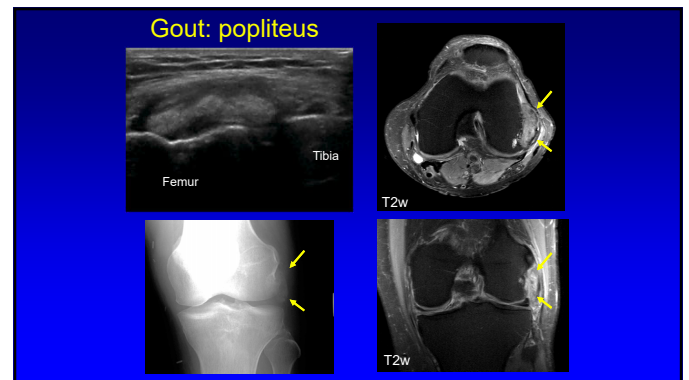
14

### Gout: patellar tendon



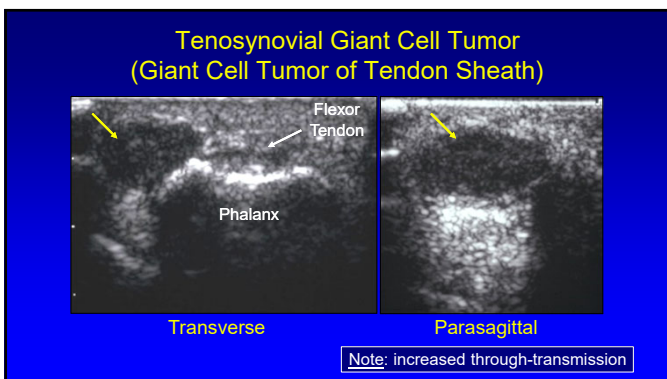
15

### Gout: popliteus



16

### Tenosynovial Giant Cell Tumor (Giant Cell Tumor of Tendon Sheath)



17

### Outline:

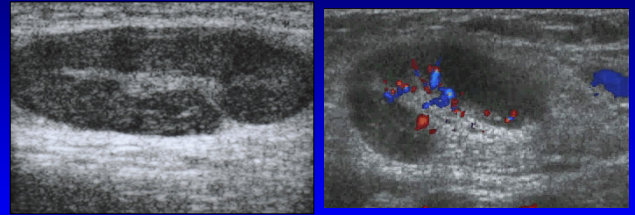
- Joint recess
- Bursa
- Tendon
- Lymph Node
- Ganglion
- Subcutaneous
- Other

18

## Lymph Node

- Hyperplastic:
  - Oval, hyperechoic hilum
  - Hilar vascular pattern
- Malignant:
  - Asymmetric thick cortex
  - Round
  - Loss of hyperechoic hilum
  - Variable vascular pattern

## Lymph Node: reactive

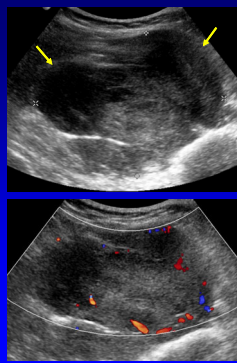


19

20

## Lymphoma: nodal

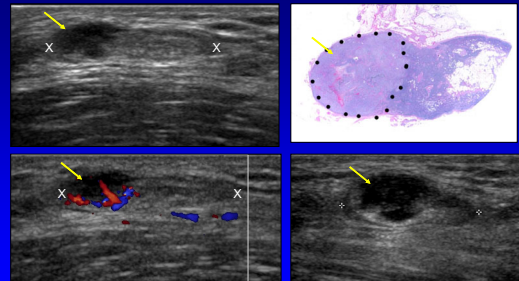
- Hypoechoic enlarged lymph node mass
- Malignant:
  - Round shape
  - Absence of echogenic hilum
  - Irregular vascular pattern



Vassallo et al. Radiology 1992; 183:215

21

## Lymph Node: angiosarcoma metastasis



22

## Outline:

- Joint recess
- Bursa
- Tendon
- Lymph Node
- **Ganglion**
- Subcutaneous
- Other

## Ganglion

- Ultrasound features:
  - Hypoechoic
  - Multilocular
  - Not compressible
- Specific locations
- Differential: paralabral, parameniscal cysts

23

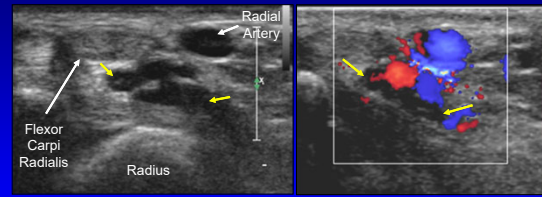
24

## Ganglia

- Wrist:
  - Volar: between radial artery and FCR
    - Most common site (69%)
  - Dorsal: over scapholunate ligament
- Knee:
  - Cruciates, gastrocnemius tendon
  - Hoffa fat pad
- Ankle: tarsal tunnel

25

## Ganglion: volar wrist



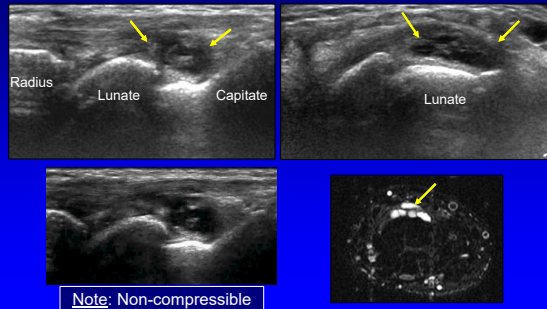
Axial

color Doppler

Zhang A et al. J Ultrasound Med 2019; 38:2155

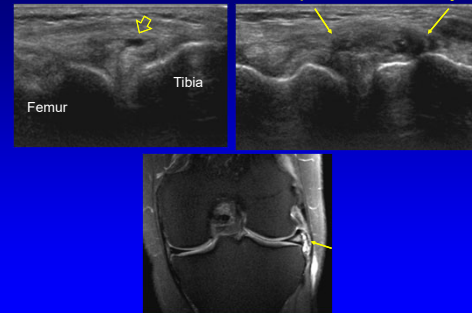
26

## Ganglion: dorsal wrist



27

## Lateral Meniscus: tear and parameniscal cyst



28

## Outline:

- Joint recess
- Bursa
- Tendon
- Lymph Node
- Ganglion
- **Subcutaneous**
- Other

29

## Subcutaneous Masses

- Lipoma
- Fat necrosis
- Epidermal inclusion cyst
- Other: benign versus malignant

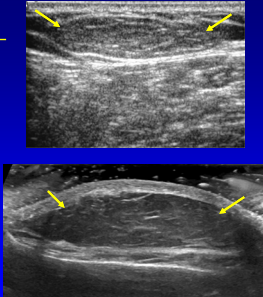
\*Note: subcutaneous masses that are hyperechoic are almost certainly benign

Jacobson JA et al. Radiology 2022; 304:18

30

### Lipoma: subcutaneous

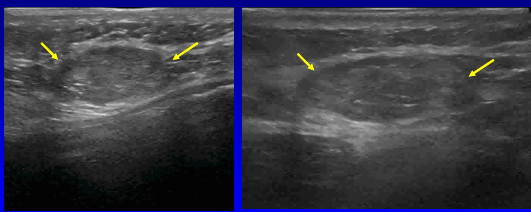
- Oval or oblong
- Homogeneous
- Isoechoic to adjacent fat
- Hyperechoic:
  - With increased fibrous tissue components
- No internal vascularity
- Compressible
- Clinically benign



Inampudi et al. Radiology 2004; 233:763

31

### Lipoma: subcutaneous

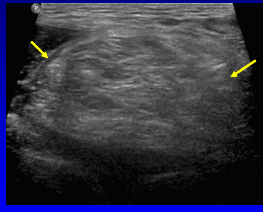


Sonopalpation      Compressible

32

### Lipoma: deep

- Variable echogenicity
- Often ill-defined
- Often difficult to assess
- Cannot reliably differentiate from low-grade liposarcoma!
- Need MRI

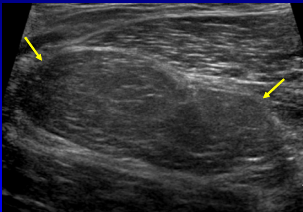


Paunipager et al. Insights Imaging 2010; 1:149

33

### Liposarcoma: well-differentiated

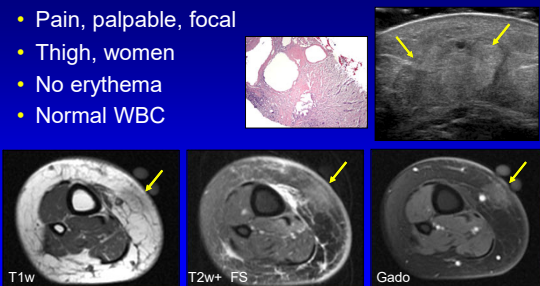
- Also called atypical lipomatous tumor
- Hypoechoic
- Looks like a lipoma
- Need MRI with any suspected deep lipoma!



34

### Fat Necrosis

- Pain, palpable, focal
- Thigh, women
- No erythema
- Normal WBC

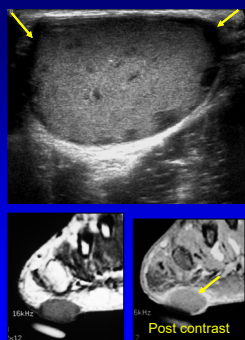


J Ultrasound Med 2008; 27:1751

35

### Epidermal Inclusion Cyst

- Etiology: implantation of epithelium, congenital, squamous metaplasia, hair follicle obstruction
- US findings:
  - Low level echoes and hypoechoic halo
  - Through transmission
  - Hypoechoic clefts
  - Periscope sign: extension to skin



Kim et al. Skeletal Radiol 2011; 40:1415

36

**Outline:**

- Joint recess
- Bursa
- Tendon
- Lymph Node
- Ganglion
- Subcutaneous
- **Other**

37

**Tumor**

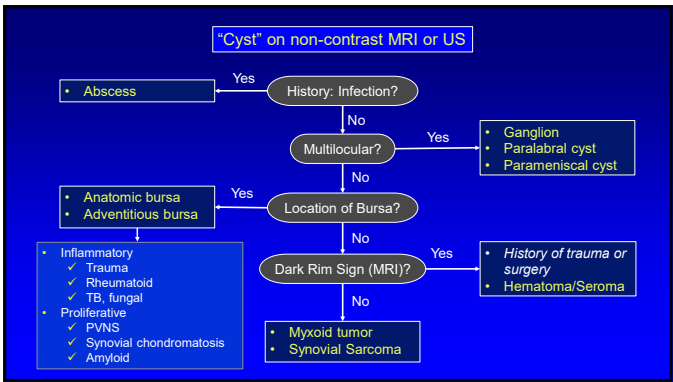
Metastasis: Renal Cell Carcinoma      Sarcoma: high grade

38

**Metastasis**

Squamous cell carcinoma  
*Note: increased through-transmission (open arrows)*

39



40

**Take Home Points**

- Key to differential diagnosis:
  - Specific anatomic location
- Joint and tendon: benign
- Bursa: key location, unilocular, compressible
- Ganglion: location, multilocular, not compressible
- Lipoma: subcutaneous, oval, compressible
- Malignancy: hypoechoic, heterogeneous

41

**Thank you!**

NYC      Ann Arbor      San Diego

Syllabus on line and other educational material:  
[www.jacobsonmuskus.com](http://www.jacobsonmuskus.com)

Twitter handle: @jjacobsn

42